

## References

1. Júnior AdP, Erdmann TR, Santos TV, et al. Comparação entre bloqueios peridural e paravertebral torácicos contínuos para analgesia pós-operatória em pacientes submetidos a toracotomias: revisão sistemática. *Rev Bras Anesthesiol.* 2013;63:433–42.
2. Bueno NB. Explorando a heterogeneidade. In: Barbosa FT, editor. *Introdução à revisão sistemática: a pesquisa do futuro.* 2013. Available at: <http://bit.ly/lrs01> [accessed 02.01.14].
3. Higgins JP, Thompson SG, Deeks JJ, et al. Measuring inconsistency in metaanalyses. *BMJ.* 2003;327:557–60.

Fabiano Timbó Barbosa<sup>a,\*</sup>,  
Tatiana Rosa Bezerra Wanderley Barbosa<sup>b</sup>,  
Rafael Martins da Cunha<sup>c</sup>

<sup>a</sup> *Universidade Federal de Alagoas (UFAL), Maceió, AL, Brazil*

<sup>b</sup> *Centro Universitário Uniseb Interativo, Maceió, AL, Brazil*

<sup>c</sup> *Hospital Unimed, Maceió, Maceió, AL, Brazil*

\*Corresponding author.

E-mail: [fabianotimbo@yahoo.com.br](mailto:fabianotimbo@yahoo.com.br) (F.T. Barbosa).

Available online 12 August 2015

<http://dx.doi.org/10.1016/j.bjane.2014.02.015>

## Foot drop following spinal anaesthesia



### Queda do pé após raquianestesia

Dear Editor,

We report a case of foot drop following spinal anaesthesia. The incidence of nerve injury related to spinal anaesthesia is less than 1:10,000, and most incidences have unknown aetiology.<sup>1,2</sup> However, if patients complain of pain or paraesthesia during spinal anaesthesia they must be watched for any unwanted neurological deficits. We report a case involving a possible needle trauma or local anaesthetic drug-related neural structure injury and subsequent foot drop.

A healthy 31-year-old adult female was scheduled for anal fissurectomy surgery. She had no medical comorbidity. Complete blood count and coagulation parameters were normal. After obtaining informed written consent and after overnight fasting, she was prepared for the operation. Routine monitorization (non-invasive blood pressure, electrocardiography, and pulse-oximeter) was performed in the operating room.

Once all aseptic precautions had been completed, a 27 g Quincke needle was inserted in the L4-L5 interspace. As the needle entered the subarachnoid space, the patient exhibited a jerky reaction that was followed by paraesthesia and pain. The needle was immediately withdrawn slightly and once the pain had subsided spinal anaesthesia was achieved with 10 mg (2 mL) 0.5% bupivacaine (heavy marcaine®, AstraZeneca, Istanbul, Turkey) In order to achieve saddle block, the patient was kept in a sitting position for five minutes and was turned to a prone position to operation.

In terms of perioperative sedation, midazolam (3 mg) was given intravenously. The operation lasted for 30 minutes. The patient was lightly sedated and was comfortable during the procedure.

At the postoperative sixth hour, the patient noticed that she was unable to move her left foot. After light touch neurological examination, pin prick and vibration senses were all reported to be absent. All reflexes were brisk except for the left knee, the ankle and the plantar reflexes, which were absent. There was also a persistent foot drop involving with left foot plantar flexion (0/5), although the

right foot was normal. Because the MRI was normal, surgical intervention was not scheduled. Methylprednisolone (250 mg) and vitamin B complex treatment (Bemiks®, Zentiva, Istanbul, Turkey) were started.<sup>2,3</sup> Dexamethazone (16 mg) and B complex therapy were continued for five days. Physiotherapy was scheduled, and the patient was discharged. After 3 months of physiotherapy, the patient's symptoms were markedly improved.

Following spinal anaesthesia, mechanical trauma resulting from a needle or accidentally unsuitable drug placement are the most probable causes of neurological complications. As in many of the reported cases,<sup>1–3</sup> we could not explain the exact aetiological factor that led to the neurological complications, which included paraesthesia and pain.

Orientation of the needle is also an important factor in terms of the depth and extent of nerve injury. A transverse needle insertion is associated with greater nerve injury, while a horizontal insertion is less dangerous. During the spinal anaesthesia procedure, paraesthesia associated with needle movement may cause nerve damage. The intensity of the paraesthesia is a strong indicator of nerve damage. The weakness and sensorial defects may be long lasting.<sup>4</sup>

We recommend a brief neurological examination of the lower limbs before a spinal anaesthesia protocol and, in an acute developed spinal anaesthesia-related foot drop situation, an urgent diagnose is needed and a treatment procedure is crucial for improved long term outcomes.

## Conflicts of interest

The authors declare no conflicts of interest.

## References

1. Nirmala BC, Gowri Kumari. Foot drop after spinal anaesthesia: a rare complication. *Indian J Anaesth.* 2011;55:78–9.
2. Ghai A, Hooda S, Kumar P, Kumar R, Bansal P. Bilateral foot drop following lower limb orthopedic surgery under spinal anesthesia. *Can J Anesth.* 2005;52:550.
3. Reynolds F. Damage to the conus medullaris following spinal anaesthesia. *Anaesthesia.* 2001;56:238–47.
4. Auroy Y, Narchi P, Messiah A, Litt L, Rouvier B, Samii K. Serious complications related to regional anaesthesia: results of a prospective survey in France. *Anaesthesiology.* 1997;87:479–86.

Ilker Onguc Aycan<sup>a,\*</sup>, Huseyin Turgut<sup>b</sup>,  
Abdulmenap Guzel<sup>a</sup>, Erdal Dogan<sup>a</sup>, Gonul Olmez Kavak<sup>a</sup>

<sup>a</sup> Department of Anaesthesiology and Reanimation,  
Medical Faculty, Dicle University, Diyarbakır, Turkey

<sup>b</sup> Department of Anaesthesiology and Reanimation, Women  
Health and Gynecology Hospital, Diyarbakır, Turkey

\* Corresponding author.

E-mail: [ilkeraycan@gmail.com](mailto:ilkeraycan@gmail.com) (I.O. Aycan).

Available online 11 October 2014

<http://dx.doi.org/10.1016/j.bjane.2014.06.003>

## Is it a matter of habit?



## Será uma questão de hábito?

Dear Editor,

Postoperative respiratory complications reportedly occur in 4.3% of surgical cases (1.7% and 7.4% of cleft lip and cleft palate repairs, respectively).<sup>1</sup> Airway obstruction is the main early postoperative respiratory complication with an overall frequency of 2.3%.<sup>2,3</sup> Airway obstruction usually occurs following closure of a wide cleft palate or syndromic cleft associated with hypoplasia of the mandible, the presence of a hematoma, or the presence of packs accidentally left in the surgical site. However, an airway obstruction due to surgical repair of cleft as regard to a closure of the habitual anatomical airway and the reason for its postoperative unexpected respiratory complications have not been considered in cleft reports until now.

Patients with cleft lip may develop a habitual airway preoperatively, based on their cleft type and size. Because they do not have symptoms of breathing difficulty in the preoperative period, their main airway is not considered during preoperative anesthetic assessment; thus, the anesthetist may not be ready for an airway problem in the postoperative period. We reviewed our recent case series with respect to the incidence and possible causes of postoperative airway obstruction. Postoperative desaturation occurred in only one case in our series; all other reasons, such as opiate analgesic use and postoperative swelling or edema that may cause similar symptoms, were excluded. We present herein our view of airway obstruction, with consideration of a patient with unilateral lip cleft who developed postoperative desaturation.

Patients with clefts breathe mainly through one of the following routes:

- Oral airway
- Nasal airway
- Cleft airway

Breathing through the nasal airway is possible through the intact nostril in a patient with a unilateral complete cleft. Oral airway patency is more or less dependent on the positioning of the jaw and lower lip. However, the cleft airway will be occluded by the end of the operation. Therefore, during the preoperative period, infant patients who breathe predominantly through the cleft airway can manifest airway problems because of desaturation and

cyanosis related to closure of the cleft until they are able to change their breathing habit in the early postoperative period. Closing the cleft can be problematic, and a transitional period may be necessary to relieve the agitation and symptoms, similar to those observed during the postoperative period, in patients who have undergone nasal septum or rhinoplasty operations. Therefore, a relatively long period of airway use may be necessary until these patients learn to breathe through their "new" airway.

We recently encountered a 5-month-old patient with a unilateral complete cleft lip in whom the oropharyngeal airway had to be maintained in the mouth for 24 hours postoperatively. The baby tolerated the airway in his mouth even when fully awake without manifesting any signs of irritation, acting as if it were a pacifier (Fig. 1). Thus, cyanosis and desaturation were restored. Afterward, we taught his mother how to insert the airway into, and remove it, from his mouth as needed. When the baby needed to be fed and the airway had to be removed, we observed that he had learned to breathe through his new anatomical airway and no longer required the artificial airway. Remote

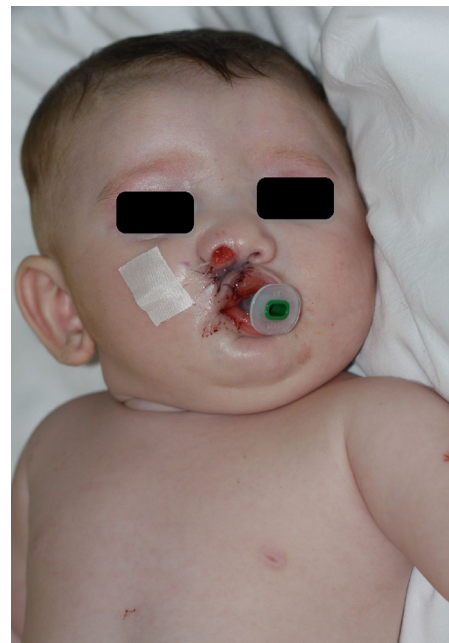


Figure 1 Awake baby with the airway in his mouth without any signs of irritation.