



## Case Report

# Case Report: acute pancreatitis in a patient with dengue fever

Jorge C. F. Nakazaki <sup>a,b</sup>, Angela I. Cotera-Ramón <sup>b,\*</sup>, Rodrigo G. Medina <sup>b</sup>

<sup>a</sup> Instituto de Medicina Tropical 'Alexander von Humboldt', Universidad Peruana Cayetano Heredia, Honorio Delgado 430, San Martín de Porres, Lima 15102, Peru

<sup>b</sup> Facultad de Medicina Alberto Hurtado, Universidad Peruana Cayetano Heredia. Lima, Perú

### ARTICLE INFO

#### Article history:

Received 18 April 2024

Received in revised form 15 June 2024

Accepted 21 June 2024

#### Keywords:

Dengue

Pancreatitis

Abdominal pain

### ABSTRACT

Dengue fever is caused by the dengue virus (DENV) and affects over 390 million people yearly. It is prevalent in tropical areas, and warning signs have been established to easily identify patients who need further medical attention. In this article, we report the case of an 18-year-old female patient in Lima, Peru, during a dengue outbreak, presenting with abdominal pain, fever, and gingival bleeding. She tested positive for the NS1 antigen and was also diagnosed with mild acute pancreatitis. It is important to note that DENV infection may lead to acute pancreatitis during outbreaks, which could be underdiagnosed due to symptoms similar to dengue fever.

© 2024 The Authors. Published by Iberoamerican Journal of Medicine. This is an open access article under the CC BY license (<http://creativecommons.org/licenses/by/4.0/>).

\* Corresponding author.

E-mail address: [angela.cotera@upch.pe](mailto:angela.cotera@upch.pe)

ISSN: 2695-5075 / © 2024 The Authors. Published by Iberoamerican Journal of Medicine. This is an open access article under the CC BY license (<http://creativecommons.org/licenses/by/4.0/>).

<https://doi.org/10.53986/ibjm.2024.0018>

## Caso clínico: pancreatitis aguda en un paciente con dengue

### INFO. ARTÍCULO

#### Historia del artículo:

Recibido 18 Abril 2024

Recibido en forma revisada

15 Junio 2024

Aceptado 21 Junio 2024

#### Palabras clave:

Dengue

Pancreatitis

Dolor abdominal

### RESUMEN

La fiebre del dengue es causada por el virus del dengue (DENV) y afecta a más de 390 millones de personas cada año. Es frecuente en zonas tropicales y se han establecido señales de advertencia para identificar fácilmente a los pacientes que necesitan atención médica adicional. En este artículo, reportamos el caso de una paciente de 18 años en Lima, Perú, durante un brote de dengue, que presentó dolor abdominal, fiebre y sangrado gingival. Dio positivo para el antígeno NS1 y también le diagnosticaron pancreatitis aguda leve. Es importante señalar que la infección por DENV puede provocar pancreatitis aguda durante los brotes, que podrían subdiagnosticarse debido a síntomas similares a los del dengue.

© 2024 Los Autores. Publicado por Iberoamerican Journal of Medicine. Éste es un artículo en acceso abierto bajo licencia CC BY (<http://creativecommons.org/licenses/by/4.0/>).

HOW TO CITE THIS ARTICLE: Nakazaki JCF, Cotera-Ramón AI, Medina RG. Case Report: acute pancreatitis in a patient with dengue fever. Iberoam J Med. 2024. doi: 10.53986/ibjm.2024.0018. [Ahead of Print].

## 1. INTRODUCTION

Dengue fever is caused by the DENV, which belongs to the *Flaviviridae* and affects more than 390 million people annually. Transmission follows a human-mosquito cycle whose principal actor is the mosquito of the genus *Aedes spp* (*A. aegypti* or *A. albopictus*), mainly in tropical regions such as South America [1].

During DENV infection, three clinical phases can be differentiated: febrile, critical, and recovery. The second phase is most associated with complications due to pathological plasma leakage, which can manifest mainly as ascites and pleural effusion. This phase starts when the fever drops, indicating that patients and health workers must be aware of potential complications [2, 3].

In 2009, THE World Health Organization (WHO) guidelines proposed a classification depending on the presence of warning signs, which include abdominal pain, persistent vomiting, ascites or pleural effusion, mucosal bleeding, lethargy, hepatomegaly, increase in hematocrit, and thrombocytopenia, to identify which patients should be admitted for further management [4]. Nevertheless, abdominal pain and persistent vomiting can also have other underlying etiologies in patients with dengue fever, including hepatitis, acute acalculous cholecystitis, and acute pancreatitis [5]. Nonetheless, these causes of abdominal pain are considered rare in dengue fever. Here, we report a case of an 18-year-old female patient from Lima, Peru, who tested positive for the NS1 antigen during a dengue outbreak. The patient experienced abdominal pain, fever, and gingival bleeding and was also diagnosed with mild acute pancreatitis.

## 2. CASE REPORT

An 18-year-old female patient from Lima, Peru, with no significant medical history, presented to the emergency room due to persistent fever, myalgias, abdominal pain, and bleeding gums, which had been present for five days. Her abdominal pain had gradually increased in intensity, requiring medical attention. At that time, testing was notable for a positive NS1 antigen. She also reported experiencing heavier-than-usual menstrual bleeding, a pruritic rash on her lower limbs, epistaxis, and oral intolerance. On the fifth day of the disease, she was admitted.

Initial vitals upon admission were blood pressure 95/64 mmHg, heart rate 135 beats/minute, respiratory rate 22 breaths/minute, and temperature 38.3°C. Oxygen saturation was 98% on room air. The patient had a diffuse erythematous rash with white spots on his back and upper and lower extremities. The physical exam was notable for tenderness in the mesogastrium and epigastrium. The rest of the examination was unremarkable.

Upon admission, the patient's laboratory results showed a hemoglobin of 11.5 mg/dl, and hematocrit of 34%, and leukopenia, with lymphopenia being more pronounced on the third day of admission (the eighth day of illness). Hemoglobin and hematocrit values remained constant throughout the disease. Platelets reached a nadir of 158 000/mm<sup>3</sup> on the third day of admission. Leukocyte levels returned to normal towards the end of the illness. AST and ALT values were 187 U/L and 114 U/L, respectively. Renal function was normal. Additionally, the chest X-ray showed no abnormalities.

On the sixth day since the onset of the abdominal pain, the patient's condition severely progressed. An ultrasound

showed no abnormalities, and the pancreas could not be evaluated. Pancreatic enzymes were markedly elevated. Lipase reached a threefold upper normal limit since the sixth day of illness, attaining a zenith of 1848 U/L one week later (Figure 1). Cholesterol and triglycerides were within the normal values. Electrolytes, including calcium, were unremarkable (Table 1). The patient also experienced oral intolerance, nausea, and vomiting as the main symptoms at this time. An abdominal computed tomography was performed to investigate the condition further (Figure 2), which revealed gallbladder and pancreas edema.

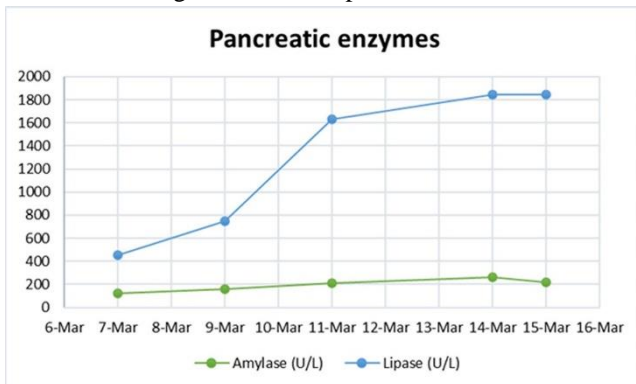


Figure 1: Pancreatic enzymes along the time.

The patient was treated for dengue and pancreatitis according to guidelines. Her condition improved, and she was discharged after nine days of hospitalization. She is currently undergoing follow-up care as an outpatient.

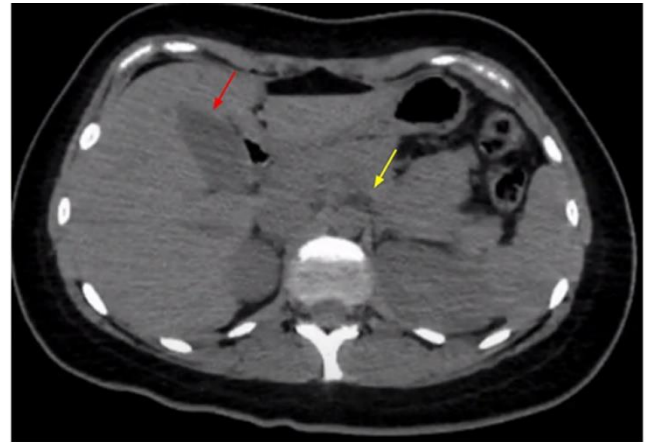


Figure 2: Abdominal CT scan without contrast from the abdomen showing gallbladder edema (red arrow) and pancreas body edema (yellow arrow); the head of the pancreas is difficult to see.

### 3. DISCUSSION

Dengue is an RNA virus belonging to the *Flavivirus* genus and the *Flaviviridae* family; the different serotypes of this disease are transmitted by the bite of mosquitoes of the *Aedes* genus, mainly *Aedes aegypti* [1].

There has recently been a significant increase in the incidence of DENV in subtropical and tropical regions. Due to the rapid and significant urban growth and development associated with the necessary adequate dengue surveillance in non-developed countries in tropical areas, the disease's actual burden is likely underestimated. According to the Ministry of Health of Peru, dengue cases increased by 221% until Epidemiological Week No. 10 (March 8) compared to the same period in 2023 [6, 7].

Acute pancreatitis is a rare manifestation of DENV and usually occurs during the critical phase. Among the most

Table 1: Patient laboratories during admission

	March 07	March 09	March 11	March 14	March 15
Days of illness	#06	#08	#10	#13	#14
Hemoglobin (mg/dL)	11.5	11.9	11.3	11.6	11.3
Hematocrit (%)	34	35	33	34	33
WBC (cells/mm <sup>3</sup> )	2400	900	3600	4300	4900
Lymphocytes	950	360	1720	1480	1800
Platelets (/mm <sup>3</sup> )	180 000	158 000	189 000	356 000	356 000
Alkaline phosphatase	-	142	-	69	70
AST	-	187	-	233	177
ALT	-	114	-	405	367
Creatinine	0.68	0.54	-	0.45	0.44
INR	-	0.94	-	1.2	1.12
Amylase (U/L)	125	157	210	263	214
Lipase (U/L)	454	749	1631	1848	1845

WBC: White blood cells; AST: Aspartate transaminase; ALT: Alanine transaminase; INR: International normalized ratio.

common causes of pancreatitis are gallstones and alcohol; however, infectious diseases are also known to cause pancreatitis [7, 8]. Diagnosis requires the presence of two out of three criteria: 1) acute onset of pain in the epigastrium, often radiating to the back; 2) elevated levels of lipase or serum amylase, three times or more than the upper normal limit; 3) and distinctive findings indicative of acute pancreatitis on imaging studies (such as contrast-enhanced computed tomography (CT), magnetic resonance imaging (MRI), or transabdominal ultrasound) [9, 10]

It is essential to rule out other causes of pancreatitis before considering the DENV. An abdominal ultrasound should be performed to look for gallstones, triglycerides, and calcium should be measured, and a history of excessive alcohol consumption should be assessed. After excluding all these common causes, the criteria for associating pancreatitis with DENV should be evaluated.

These criteria can be applied to any infectious organism. They establish the following scenarios [5, 9, 10]:

- Definitive criteria: finding the pathogen in pancreatic tissue.
- Probable criteria: isolating the organism in culture from the pancreatic juice, blood, or serological evidence with a characteristic clinical or epidemiological setting.
- Possible criteria: isolating the organism in a culture from other body samples or serological evidence of infection.

The aforementioned case presentation was likely a sequela of an acute dengue virus infection based on the abovementioned criteria. In this case, this patient tested positive for the NS1 antigen. Likewise, she has an abdominal tomography showing a slight increase in volume and edema in the pancreas, which correlates with elevated lipase levels. Additionally, confirmation through abdominal computed tomography suggests the diagnosis of acute pancreatitis secondary to viral etiology. Serological evidence in correlation with the characteristic clinical and epidemiological picture is often enough to establish the diagnosis, as in our case.

This case suggests that DENV might be a more frequent cause of acute pancreatitis than expected, especially during outbreaks. Classical dengue cases can manifest abdominal pain as a warning sign, a symptom expected to occur during the critical phase, typically associated with vascular leakage into the peritoneal cavity. Nevertheless, organ involvement should be considered in dengue patients presenting with abdominal pain during the febrile phase since the virus can infect them. Following this idea, we believe that abdominal organ involvement should be considered in patients with

dengue fever who develop abdominal pain early in the disease [7, 9].

Finally, it is also relevant to acknowledge the possibility of underdiagnosed cases of dengue pancreatitis since both acute pancreatitis and dengue fever have IV fluids as the cornerstone of their management. If pancreatitis was detected early in dengue cases, further complications from this entity might be avoided. Additional studies are required to understand dengue pancreatitis cases better and determine the relevance of its early detection.

---

## 4. CONFLICT OF INTERESTS

The authors have no conflict of interest to declare. The authors declared that this study has received no financial support.

---

## 5. ACKNOWLEDGEMENTS

We thank the patient for allowing us to use their image and share their complex disease case. This patient's case was discussed during the clinical rounds at The Gorgas Diploma Course in Clinical Tropical Medicine 2024, so we thank those in charge. Furthermore, we would like to express our heartfelt appreciation to the Alexander von Humboldt Institute of Tropical Medicine for providing us with the necessary facilities for this patient's treatment.

---

## 6. REFERENCES

1. Khan MB, Yang ZS, Lin CY, Hsu MC, Urbina AN, Assavalapsakul W, et al. Dengue overview: An updated systemic review. *J Infect Public Health*. 2023;16(10):1625-42. doi: 10.1016/j.jiph.2023.08.001.
2. Dengue: Guidelines for Diagnosis, Treatment, Prevention and Control: New Edition. Geneva: World Health Organization; 2009.
3. Nakazaki JCF, Cotera-Ramón AI. Assessment of the importance of platelet transfusion in patients with severe dengue: a systematic review. *Iberoam J Med*. 2024;5(2):69-77. doi: 10.53986/ibjm.2024.0010.
4. Bhatt S, Gething PW, Brady OJ, Messina JP, Farlow AW, Moyes CL, et al. The global distribution and burden of dengue. *Nature*. 2013;496(7446):504-7. doi: 10.1038/nature12060.
5. Flor MA, Andrade JV, Bucaram JA. Acute Pancreatitis Secondary to Dengue Fever: An Uncommon Presentation of a Common Endemic Illness. *Case Rep Infect Dis*. 2022;2022:9540705. doi: 10.1155/2022/9540705.
6. Centro Nacional de Epidemiología, Prevención y Control de Enfermedades. Ministerio de Salud de Perú. Sala Situacional de Dengue. Available from: <https://www.dge.gob.pe/sala-situacional-dengue/#gráfico01> (accessed March 2024).
7. Guzman MG, Gubler DJ, Izquierdo A, Martinez E, Halstead SB. Dengue infection. *Nat Rev Dis Primers*. 2016;2:16055. doi: 10.1038/nrdp.2016.55.
8. Gubler DJ. Dengue and dengue hemorrhagic fever. *Clin Microbiol Rev*. 1998;11(3):480-96. doi: 10.1128/CMR.11.3.480.
9. Seetharam P, Rodrigues G. Dengue Fever presenting as acute pancreatitis. *Eurasian J Med*. 2010;42(3):151-2. doi: 10.5152/eajm.2010.41.

---

10. Acherjya GK, Tarafder K, Sayeed MA, Ghosh GK, Hossain MJ, Hossain S, et al. Dengue presenting as a case of acute pancreatitis-A rare case report. *Clin Case Rep.* 2023;11(2):e6926. doi: 10.1002/ccr3.6926.