

## Crude beetroot extract ameliorates metabolic-dysfunction associated steatotic liver disease by improving the MAS-activity score in an experimental rat model

Jeremiah K. Munguti <sup>1\*</sup>  , Andrew N. Makanya <sup>2</sup>  , Moses M. Obimbo <sup>3</sup>    
Vincent K. Kipkorir <sup>4</sup>  , and Ben M. Njuguna <sup>5</sup>  

<sup>1</sup> Department of Human Anatomy and Medical Physiology, University of Nairobi, Nairobi, Kenya

<sup>2</sup> Department of Veterinary Anatomy and Physiology, University of Nairobi, Nairobi, Kenya

<sup>3</sup> Department of Human Anatomy and Medical Physiology, University of Nairobi, Nairobi, Kenya

<sup>4</sup> The College of Surgeons of East, Central and Southern Africa (COSESCA) Secretariat, Arusha, Tanzania

<sup>5</sup> Faculty of Health Sciences, University of Nairobi, Nairobi, Kenya

\* Author to whom correspondence should be addressed

Received: September 09, 2025, Accepted: November 07, 2025, Published online: November 12, 2025



Copyright© 2025. This open-access article is distributed under the *Creative Commons Attribution License*, which permits unrestricted use, distribution, and reproduction in any medium, provided the original work is properly cited.

### HOW TO CITE THIS

Munguti JK, et al. Crude beetroot extract ameliorates metabolic-dysfunction associated steatotic liver disease by improving the MAS-activity score in an experimental rat model. *Mediterr J Med Res.* 2025; 2(4): 217-229.  
[Article number: 27]. <https://doi.org/10.5281/zenodo.17587262>

**Keywords:** MASLD, MASLD-activity score, metabolic syndrome, triglyceride-glucose index

**Abstract:** The burden of metabolic-dysfunction associated steatotic liver disease (MASLD) has been rising. Targeted therapy is either expensive or unavailable. Beetroot, nonetheless, contains phytochemicals that have qualitatively been shown to deter the progression of MASLD. We sought, using stereology, to quantify the ameliorative potential of crude beetroot extract on the progression of induced MASLD. 45 rats were studied and grouped into three: Group 1 rats fed on a hyper-calorific diet; Group 2 rats fed on a hyper-calorific diet and crude beetroot extract at 200 mg/kg, while Group 3 rats were fed on standard rat chows. Five rats from groups 1 and 2 were euthanized at weeks 4, 8, 12, and 16, and blood samples were taken for biochemical analysis. The livers were then harvested and systematic uniform random sampling was used to select histological samples for processing. Images were taken and the Cavalieri principle of point counting employed to determine MASLD activity score (MAS) as listed: Steatosis scored 0 to 3; lobular inflammation scored 0 to 3 (foci/200X field) and ballooning, scored 0 to 2. A hyper-calorific diet resulted in hyperglycaemia, dyslipidaemia, and high triglyceride-glucose index, accompanied by a temporal increase in the severity of hepatocyte steatosis, ballooning and inflammation. The MAS increased with time and was highest at the 16<sup>th</sup> week for group 1 compared to group 2. Beetroot supplementation delayed hepatocyte ballooning (78.0% vs. 65.0%) and led to lower rates of moderate inflammation and severe steatosis. The accompanying biochemical markers also showed significant improved. Beetroot reduces the histological changes associated with induced MASLD by lowering the severity of several MAS components while significantly improving associated biochemical parameters.

### Introduction

Metabolic-dysfunction associated steatotic liver disease (MASLD) is a non-communicable disease characterised by the presence of  $\geq 5.0\%$  of hepatic steatosis in the absence of other established aetiologies such as chronic inflammatory liver diseases, viral hepatitis, or significant alcohol consumption [1]. The global prevalence of MASLD in the general population ranges between 14.0% and 51.0% [2, 3]. This number has, in the recent past, been on the rise especially with the increasing prevalence of metabolic syndrome fuelled by

a combination of sedentary lifestyle and an adoption of a western diet [4, 5]. Untreated, MASLD further fuels the progression of diabetes and may complicate as liver cirrhosis, and eventually, hepatocellular carcinoma. To manage the resultant MASLD, various conventional anti-inflammatory, anti-glycaemic and lipid-lowering medicines have been used in the past with varied degrees of success [6, 7]. They are further associated with numerous side effects while their limited ability to target multiple points in the pathogenesis of MASLD forces clinicians' polypharmacy [8]. On the other hand, studies have exploited the anti-oxidative and anti-inflammatory properties of various plant extracts with laudable success in ameliorating the biochemical and histological changes seen in MASLD [9]. Past experimental studies have qualitatively documented the ameliorative potential of beetroot on induced MASLD [10]. Similar findings have been reported in human subjects involving sonographic liver examination [11]. The proposed mechanisms include increased insulin sensitization, anti-oxidative, anti-inflammatory and hypoglycaemic properties of phytochemicals contained in beetroot [10, 12]. Hardly, any studies, however, exist that quantify the ameliorative potential of beetroot extract on the progression of induced MASLD despite the available scoring systems. Such scoring systems include the MASLD-activity score (MAS) initially developed by the Pathology Committee of the NASH Clinical Research Network and summarized by Takahashi and Fukusato [13]. The MAS utilizes histological changes associated with MASLD including the degree of steatosis, hepatocyte ballooning and inflammatory changes to quantify the degree of the disease entity and its temporal sequence [14]. Yet, determination of MAS in a research basis is labour intensive and requires expert input and the use of stereological techniques that may, unfortunately, not be largely available. This study, therefore, aimed at employing stereological techniques to quantify the ameliorative potential of crude beetroot extract on induced MASLD using the MAS.

## Materials and methods

*Ethical considerations, handling of study animals and study site:* Ethical approval for the conduction of the study was sought and granted by the Biosafety, Animal Use and Ethics Committee, Faculty of Veterinary Medicine, University of Nairobi (FVM BAUEC/2020/266). The study rats were housed in the animal house located at the Department of Veterinary Anatomy and Physiology, University of Nairobi. To enable the study rats to acclimatize to their new environment, they were kept for 10 days prior to the commencement of the study. The rats were housed in standard well-labelled cages. They were placed under a normal 12-hour light/dark diurnal cycle. Drinking water was freely provided ad libitum. To minimise stress to the rats, they were handled while fully awake by holding the skin over their back. This was done under the supervision of a qualified rat house attendant. All biochemical analysis was carried out at Noble Veterinary Laboratories, Nairobi while histological processing and staining were done at the Department of Human Anatomy and Medical Physiology, University of Nairobi, Nairobi, Kenya.

*Selection of study animals:* Male Albino rats (eight weeks old) were used. This is because oestrogen is thought to be protective against MASLD in females of reproductive age [15]. To reduce litter-to-litter variation, rats recruited to the study were sourced from the same breeder. Rats with obvious gross malformations including small for age rats, were excluded. Selected study rats were then randomly divided into three groups: Group 1 rats were put on a hyper-caloric diet composed of high-fat-high-fructose (HFHF); Group 2 rats were put on an HFHF diet and crude beetroot extract while Group 3 rats were the control group and were fed on a normal diet composed of standard rat pellets and drinking water ad libitum. The body weight of the study rats was assessed at the beginning of the experiment and at the end of every week after eight hours of fasting.

*Preparation of the high-fat-high-fructose diet:* The HFHF diet was prepared as described before and summarized in [12]. Saturated fat (Cowboy<sup>TM</sup> manufactured by Bidco<sup>TM</sup> industries) - 20.0% w/w was added to standard rat chow obtained from Unga feeds and containing protein (29.8%), fat (13.4%), carbohydrates (56.7%), fibre (5.3%), and vitamins and minerals in predetermined quantities as prescribed by the Kenya Bureau of Standards (KEBS). Food-grade fructose (30.0%) was added to the drinking water of rats under the

HFHF diet. The fructose was sourced from Science Lab Limited and its quality was guaranteed by the KEBS prequalification certificate. All feed was prepared on a daily basis and by the same person in order to maintain uniformity and the quality of the feeds. Maximal care was taken to maintain hygiene thus, minimizing feed contamination. Any food remaining from the previous day was weighed and then discarded as per the established animal house guidelines.

*Extraction of crude beetroot juice:* Beetroot roots used in the current study were sourced every week from a farm in Nakuru County that is usually contracted to supply beetroot to prominent hotels found in Nakuru and its environment. The choice of the farm was informed by their proven record in good horticultural practice. Beetroot juice extraction was done as previously described [16]. A fresh beetroot sample (5.0 g) was placed in a tube and 5.0 ml of acidic methanol/water mixture (50: 50, v/v, pH=2) was added. The tube was then shaken vigorously for one hour and centrifuged at 2500 g for 10 min. The supernatant was then separated from the residue. Acetone/water mixture (70: 30, v/v) was then added to the residue with a repeat of the shaking and centrifugation steps. The two extracts were then be combined and stored at - 40°C. The process was then repeated with fresh beetroot samples until the required amount was attained. The process of freeze drying the supernatant mixture was carried out at the International Livestock Research Institute (ILRI) - Nairobi Laboratories. The resultant freeze-dried extract was then stored in a freezer at - 20°C from which the daily required amount was taken, measured and reconstituted for the oral gavage of the group B rats. The HFHF+BR group was then fed, on a daily basis via oral gavage, beetroot extract at 200 mg/kg of body weight.

*Qualitative phytochemical analysis of beetroot extract:* The phytochemical screening was performed as previously described [17]. These methods employ the principle of chemical reactions of certain compounds with the target phytochemical in a given plant extract with a positive reaction being either a particular colour change or the formation of a known precipitate. The extracts that were tested were observed based on their colour change and precipitate formation. The following phytochemicals were analysed and found to be present: saponins, tannins, alkaloids, flavonoids, and steroids [18].

*Administration of beetroot extract:* The extract was then given to the group B rats every morning via oral gavage at a dose of 200 mg/kg to a maximum of 2.0 ml per rat [12, 18]. This was informed by the observation that further enzymatic digestion of the extract by gut microbiota in the colon has been reported to release more antioxidants from the insoluble fraction of the extract [19]. For standardization purposes, the control group rats were similarly given and an equitable volume of distilled water via oral gavage.

*Biochemical analysis and tissue harvesting periods:* Five rats from the control group were used for baseline results. Five rats from each group (to account for inter-individual differences) were then harvested at weeks 4, 8, 12, and 16. At each harvesting periods, blood was harvested directly from the right atrium for the biochemical analysis of the following: Serum triglycerides (TG), high density lipoproteins (HDL), and fasting glucose. Then, the triglyceride-glucose index was determined using an established online calculator.

Following euthanasia for each harvesting period, whole livers were harvested and their volumes determined using the Scherle method as described [20]. The livers were then sliced into equal one cm blocks that were then rearranged in an ascending order. The second piece was then picked and thereafter the third piece until five pieces per liver were selected for further histological processing. Each block was then embedded in wax, and using a rotary microtome, sliced into five-micrometre-thick ribbons. The second piece per ribbon and the 3<sup>rd</sup>, thereafter, for a total of five pieces per ribbon, were then selected for staining with haematoxylin and eosin stains (for quantifying steatosis). The same process was repeated for the selection of sections for staining using the Masson's trichrome and reticulin stains (for quantifying the degree of fibrosis) and periodic acid stain - PAS (for quantifying steatosis and inflammation).


*Determination of the degree of MASLD using the MASLD activity score (NAS):* We adopted the MASLD activity score (MAS) as initially determined by the Pathology Committee of the NASH Clinical Research



Network and summarized by Takahashi and Fukusato [13]. The MAS scoring system was developed for use in clinical trials and is applicable for human and animal subjects [21]. Furthermore, the MAS is able to evaluate histological changes over time, the main reason for which it was developed [14]. The score was determined and graded as summarized in **Table 1**: Steatosis scored 0 to 3; lobular inflammation scored 0 to 3 and ballooning scored 0 to 2. Determination of steatosis was done using the Cavalieri principle of point counting with the number of points falling over the regions with steatoses divided by the total number of points per field multiplied by 100 (**Figure 1**). Hepatocyte ballooning was defined by the presence of enlarged hepatocytes containing Mallory-Denk bodies [22]. Two researchers were used to independently do the scoring with each recording their findings. Where there were discrepancies, counting was done by the researchers in tandem in order to ascertain the scores. As per the original description, MAS scores  $\geq 5$  were taken to confirm the presence of non-alcoholic steatohepatitis [23].

**Table 1:** The summaries of NAFLD activity scoring

Item	Definition	Score	Grading
Steatosis	< 5.0%	0	None
	5.0-33.0%	1	Mild
	> 33.0-66.0%	2	Moderate
	> 66.0%	3	Severe
Lobular Inflammation	No Foci	0	None
	< foci/x200 field	1	Mild
	2-4 foci/x200 field	2	Moderate
	> 4foci/x200 field	3	Severe
Hepatocyte ballooning	None	0	None
	Few Balloon cells	1	Mild
	Many cells/prominent ballooning	2	Moderate



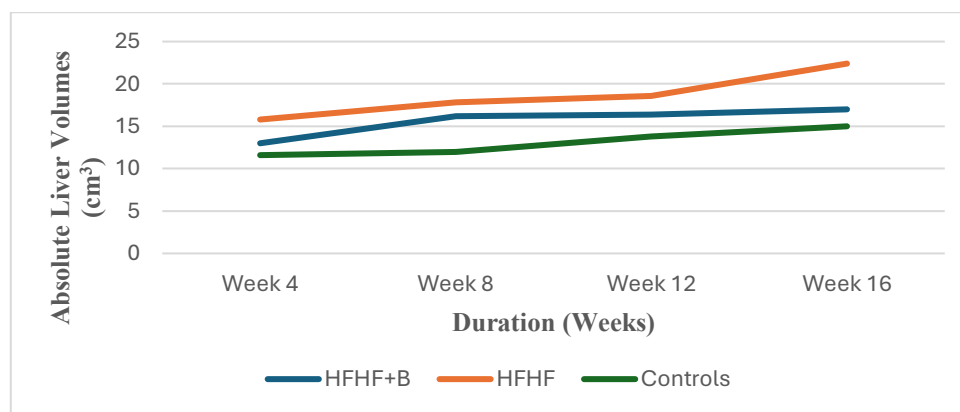
**Figure 1:** Haematoxylin and Eosin section showing the quantification of hepatocytes steatosis by point counting using STEPanizer

The principle of point counting and STEPanizer software were used to quantify steatosis in the liver sections. Selected images were placed in STEPanizer and the points were placed on the predetermined grid. The points falling on areas with steatosis were highlighted and automatically captured in Excel via a code written to link STEPanizer and Excel, hence semi-automating the process. The percentage of steatosis was then determined by dividing the counted points over the total number of points in the reference space. The same principle was used in quantifying hepatocyte ballooning and the degree of hepatic inflammation.

**Statistical analysis:** Data obtained from the methods described above was entered into Statistical Package for Social Sciences (SPSS) software (version 25). Means and standard deviations were calculated and one-way ANOVA was used to compare differences amongst the groups for the various continuous data variables with a uniform distribution. The Tukey test was used as the post-hoc test to detect between which groups the significant difference lay. Kruskal-Wallis was the nonparametric test used to compare differences in non-uniformly distributed data. Chi-square test was used to compare the categorical data obtained from the NAS.  $P \leq 0.05$  is considered statistically significant at a 95% confidence interval.

## Results

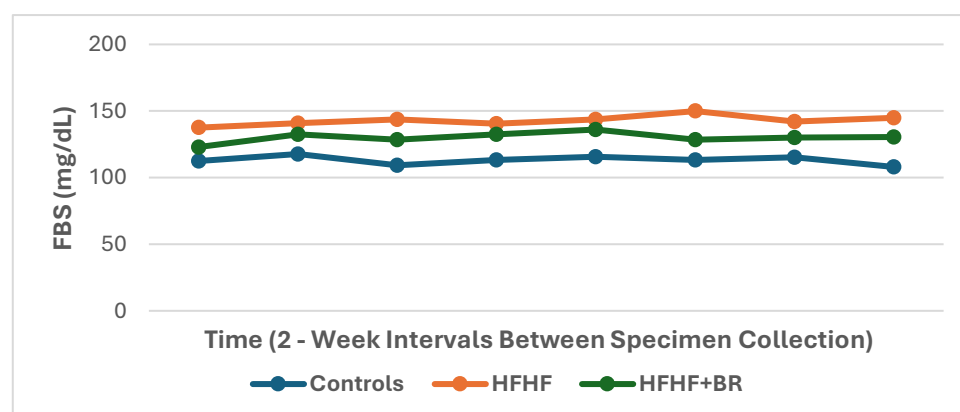
Over the 16-week period of the study, control rats had an average weight increase of 38.3% while those on the HFHF diet had 56.91% increase of body weight from baseline. Beetroot supplementation attenuated this weight increase with rats recording a weight gain of 42.4% over the same period. Similarly, the HFHF-fed rats had significantly larger liver volumes compared to the beetroot-supplemented and control rats (**Figure 2**).



**Figure 2:** Changes in absolute liver volumes over time

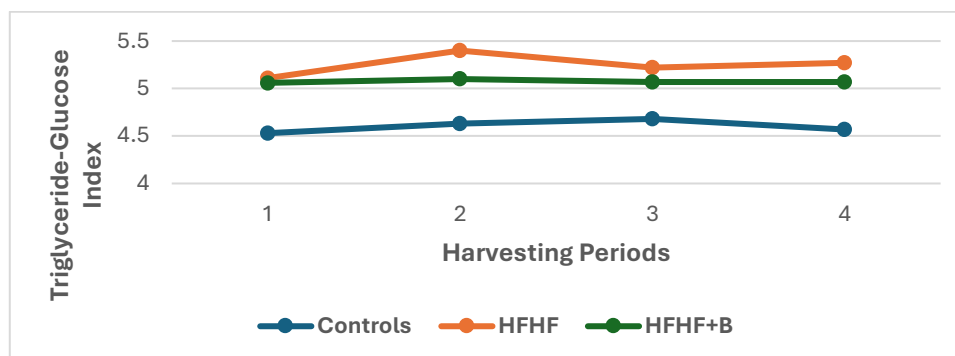
The absolute liver volumes were distinctly different for the three groups. (HFHF – high fat high fructose; HFHF + BR – high fat high fructose plus crude beetroot extract; Controls - control group rats)

**Biochemical changes associated with a high-fat-high-fructose diet:** Compared to the control group rats, the administration of an HFHF diet led to significantly higher FBS readings compared to the control group rats ( $p < 0.001$ ) (**Figure 3**). This increase was however attenuated by co-administration of beetroot extract. Similarly, the HFHF diet resulted in elevated TG, TC, and LDL levels with lower levels of HDL. Beetroot extract, on the other hand, not only led to a diminution of such increase but also led to higher levels of HDL (**Table 2**). The triglyceride-glucose index was lowest for the control group and highest for the HFHF-only group rats (**Figure 4**).



**Figure 3:** The trend of fasting blood sugar (FBS) over time

The control group rats had the lowest while group 2 rats fed only on the hyper-caloric (HFHF) diet had the highest FBS



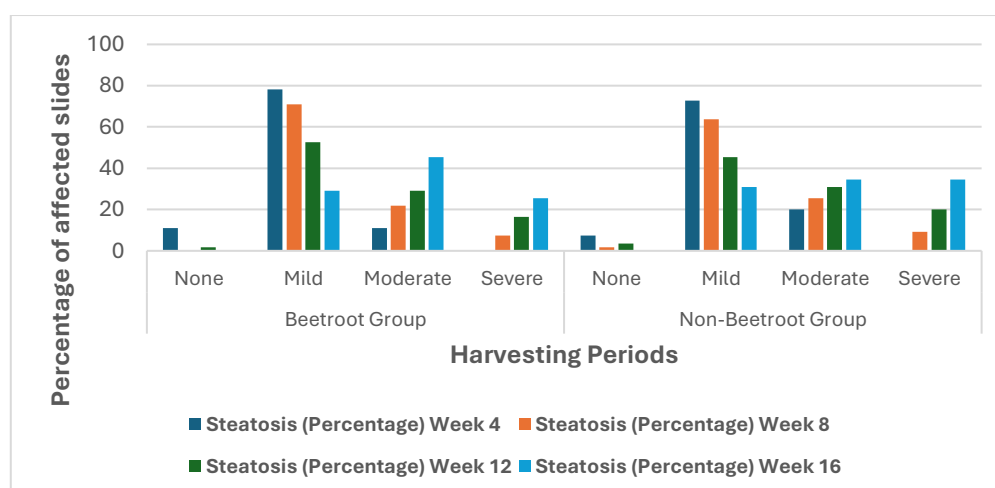
**Figure 4:** The trend in triglyceride-glucose index over time

A hyper-calorific (HFHF) diet resulted in the highest increase in the index which was attenuated by beetroot supplementation. Harvesting periods 1 - 4 represents weeks 4, 8, 12 and 16, respectively.

**Table 2:** The differences in the various lipid profile parameters over time

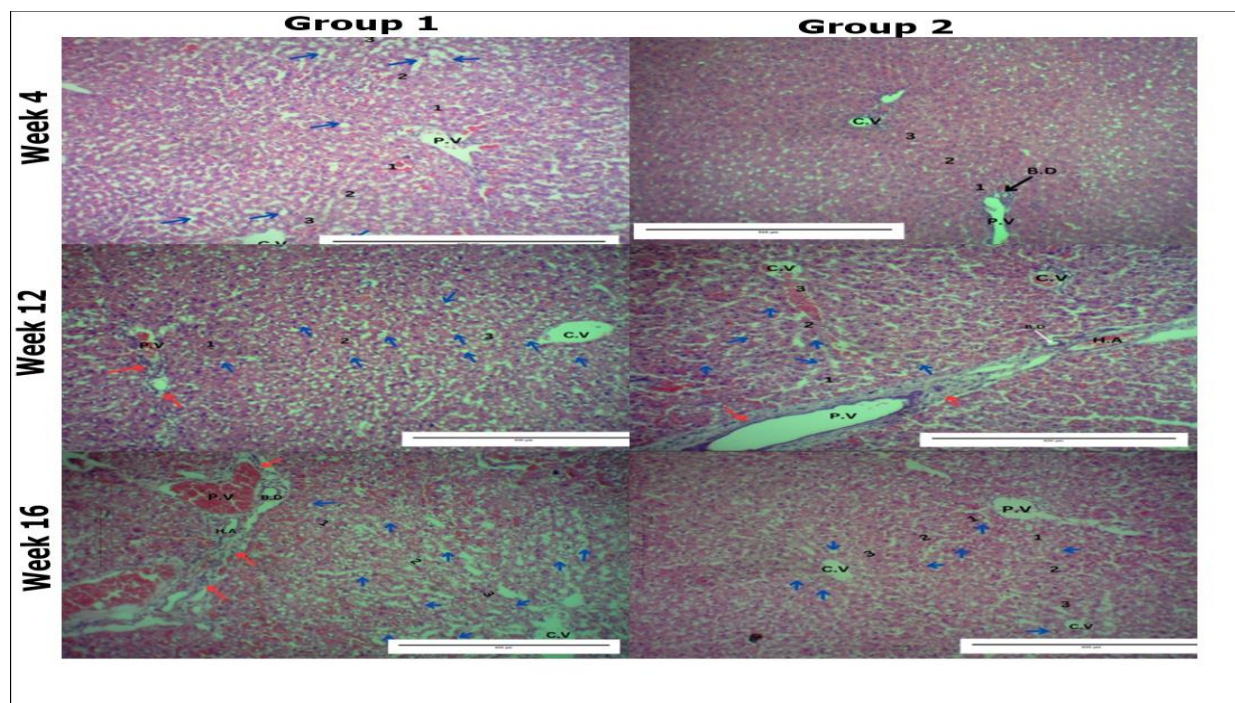
Week	Lipid Profile Control Group	Group 1 (HFHF)	p-value against Control	Group 2 (HFHF+B)	p-value Against Control	p-value Against HFHF
Triglyceride Levels (mg/dL)						
4	73.69±13.04	194.42±62.28	<b>0.0018</b>	188.66±35.25	0.0026	0.97
8	92.81±12.09	252.80±81.47	<b>0.0011</b>	202.31±36.88	0.016	0.3
12	101.5±13.03	230.29±55.18	<b>0.00048</b>	198.23±33.94	0.0046	0.4
16	86.27±10.68	262.86±74.63	<b>0.0048</b>	195.22±95.34	0.072	0.31
LDL Levels (mg/dL)						
4	9.51±04.8	21.13±8.64	<b>0.046</b>	12.45±6.28	0.77	0.15
8	9.51±05.4	21.36±6.16	0.19	19.33±15.39	0.31	0.97
12	11.21±06.79	22.74±6.04	0.17	18.18±13.54	0.49	0.73
16	13.07±07.23	19.95±6.35	0.43	18.18±10.97	0.62	0.94
HDL Levels (mg/dL)						
4	23.67±6.47	28.07±3.26	0.64	22.43±10.94	0.96	0.49
8	24.52±6.55	35.04±4.99	<b>0.02</b>	35.81±03.65	<b>0.013</b>	0.97
12	23.67±05.0	30.47±2.94	0.052	30.78±04.02	<b>0.042</b>	0.99
16	21.12±05.9	37.74±9.08	<b>0.003</b>	41.14±00.8	<b>0.0008</b>	0.68

*Non-alcoholic fatty liver disease scores:* Hepatocyte steatosis >5.0% was evident as early as the first harvesting period for group 1 and 2 rats. Steatosis was initially mild but worsened with time. Severe steatosis, on the other hand, occurred mainly in the later stages of the experiment and was more pronounced in the group A rats than in the beetroot-supplemented rats (**Figure 5**). Differences between the two groups were, however, not significant for all the harvesting periods.

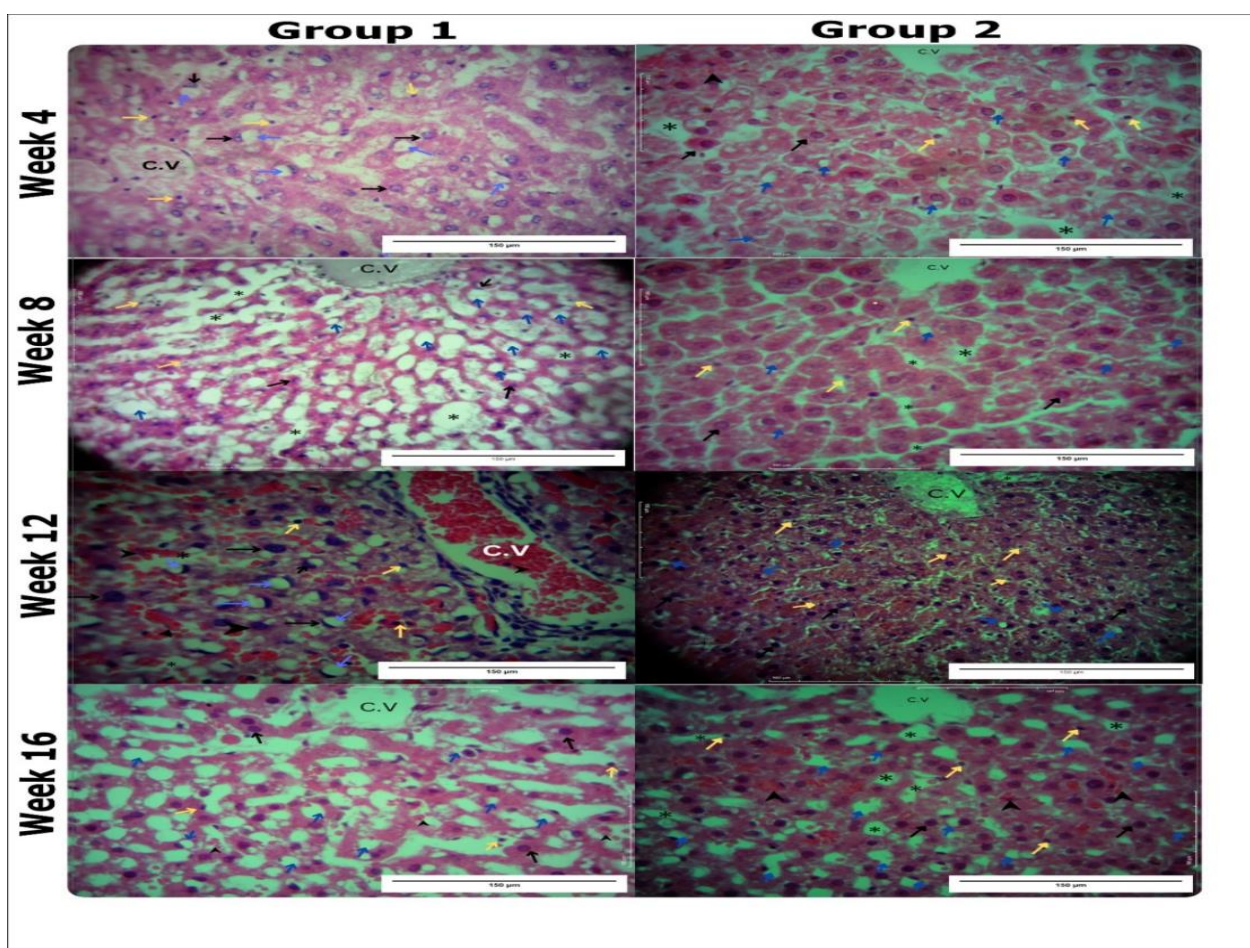


**Figure 5:** Changes in degree of hepatocyte steatosis over time (Non-Beetroot group - Group 1 rats; Beetroot group - Group 2 rats)





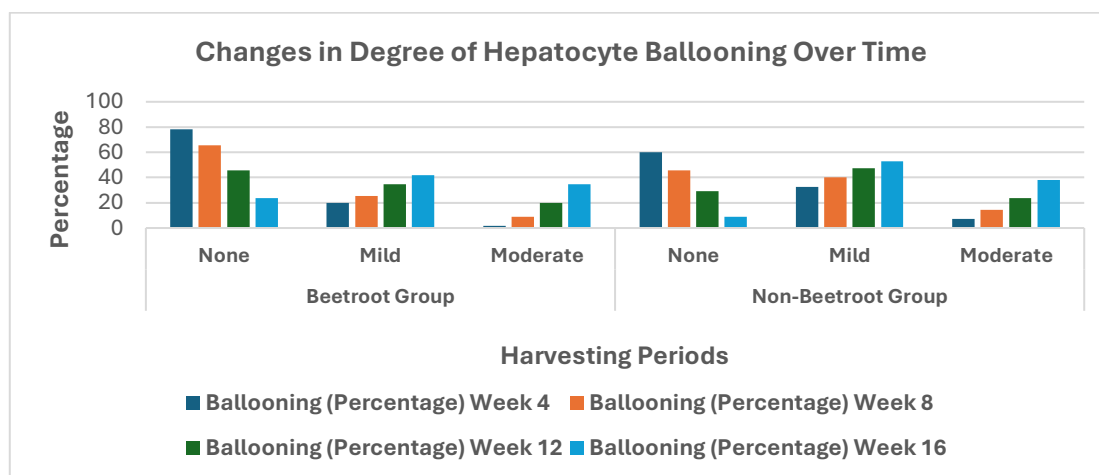
Micrographs of a hepatic lobule showing zonal differences in the HFHF and HFHF + beetroot groups at week 4, 12 and 16 of the experiment. There is prominent steatosis more in the HFHF group (blue arrows) and is seen extending to zone 1 in weeks 12, and 16, with accompanying distortion of the hepatic chords in week 16. The different zones of the liver have been illustrated in the sections (1, 2, and 3). Central vein (C.V), bile duct (B.D), portal vein (P.V).



Micrographs showing hepatic parenchymal changes at weeks 4 to 16 of the experiment. H & E-stained sections showing a greater degree of macrovesicular steatosis (blue arrows) in the HFHF group while microvesicular steatosis predominates in the HFHF + beetroot group in the earlier weeks. Macrosteatosis is later noted in both groups but worse in the HFHF-only group as the weeks progress. Sinusoidal expansion (asterisks), red blood cells (black arrowheads), prominent hepatic stellate cells (yellow arrows), Central vein (C.V).

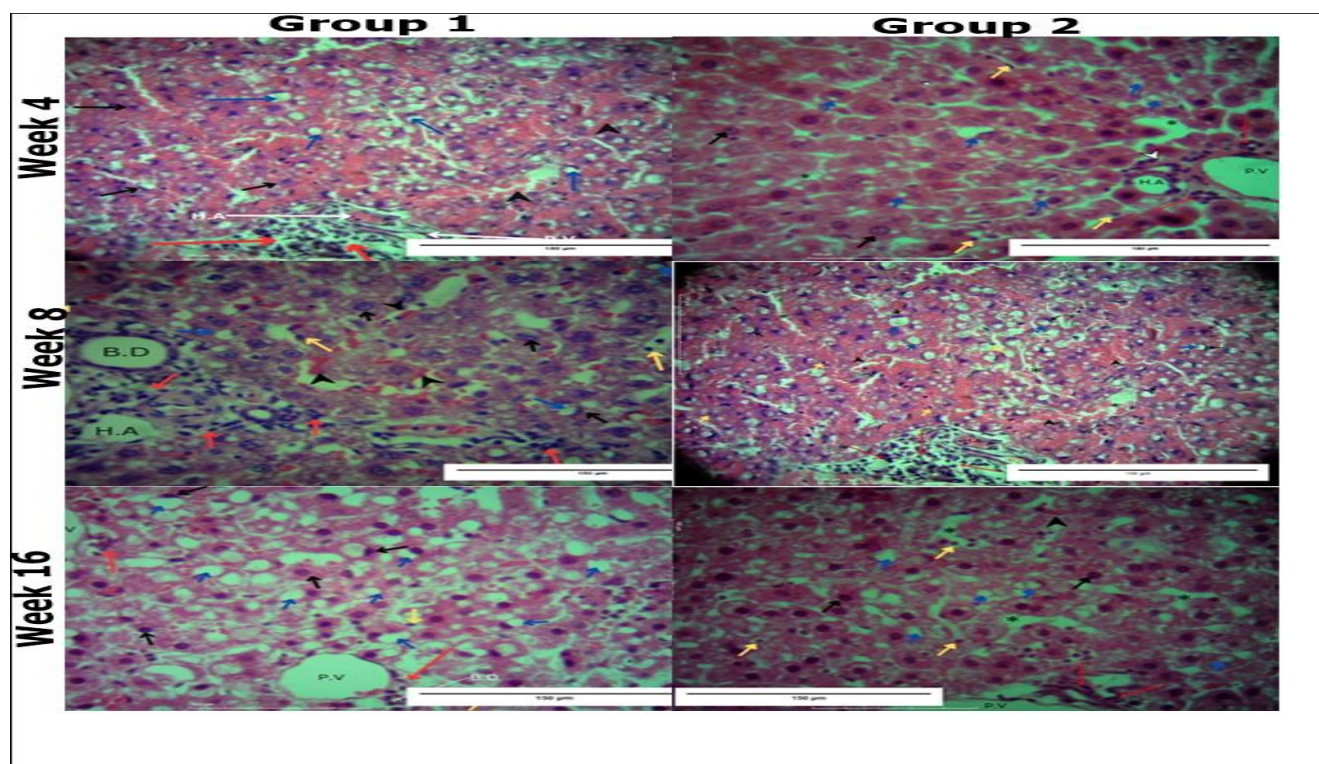


The degree of hepatocyte ballooning in groups 1 and 2 rats increased as the study duration progressed. It was initially not found in up to 78.0% and 65.0% of the slides studied for the Group B (beetroot supplemented group) and Group A rats (HFHF-only fed rats), respectively, at the first harvest. A greater degree of mild and moderate steatosis was nevertheless found in the later stages of the study and occurred more frequently in group A compared to the beetroot-supplemented group (**Figure 6**).



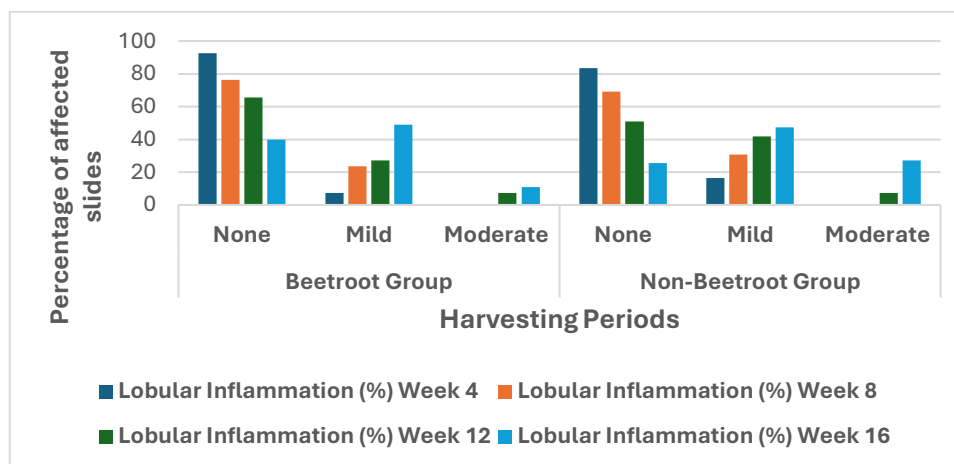
**Figure 6:** Bar graphs showing changes in the degree of hepatocyte ballooning over time  
(Non-Beetroot group – Group 1 rats; Beetroot group – Group 2 rats)

Lobular inflammation was limited in the initial stages of the study for groups but became more evident as the study progressed. When present, inflammation was however mild for both groups. Nonetheless, moderate inflammation was encountered more frequently in group 1 rats (**Figure 7**). None of the groups registered severe forms of lobular inflammation.



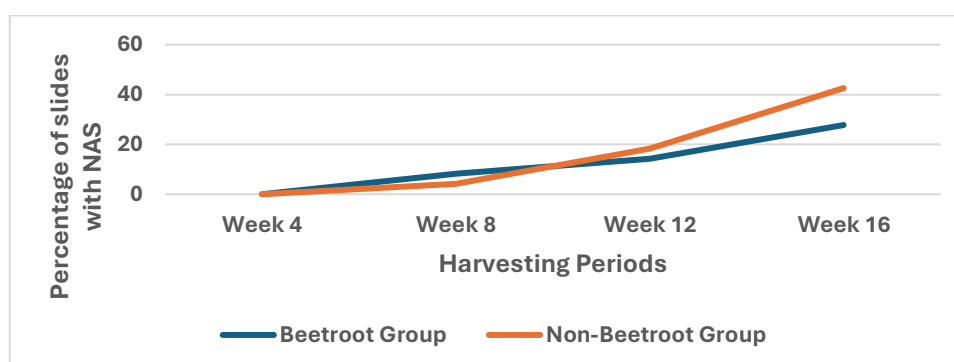
Photomicrograph of H & E-stained sections showing evidence of hepatic inflammation following a HFHF diet at weeks 4, 8 and 16 of the experiment. Periportal regions of the beetroot supplemented group has the least inflammation. Hepatitis spreading beyond the portal region is, however, seen in the HFHF group from week 8. Areas with the highest degree of steatosis (blue arrows) have the most infiltration with inflammatory cells (red arrows). Black Hepatocytes (black arrows) are not arranged in chords while sinusoids (asterisks) are dilated and filled with red blood cells (black arrowheads). Other labelled structures include the portal vein (P.V), hepatic artery (H.A) and bile duct (B.D).



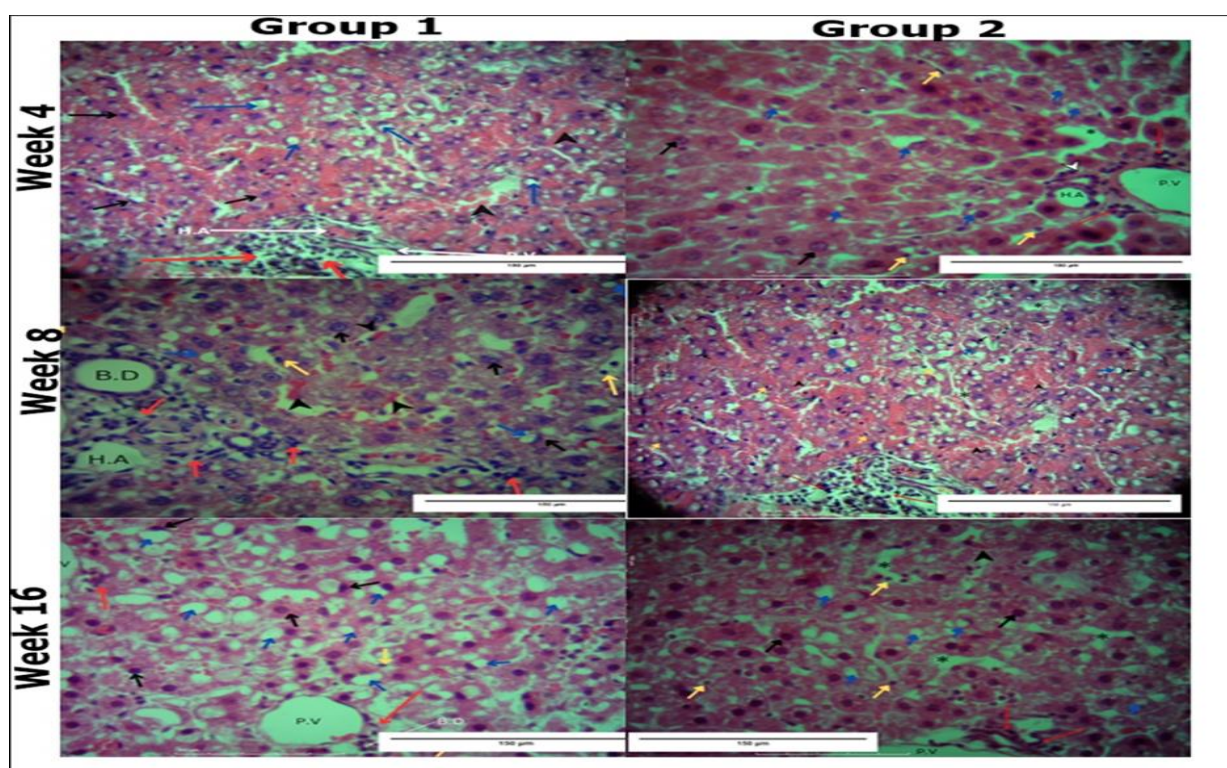


**Figure 7:** Changes in the degree of stromal inflammation over time

(Non-Beetroot group - Group 1 rats; Beetroot group - Group 2 rats). None of the slides analysed for rats euthanized at the end of the first four weeks had non-alcoholic steatohepatitis (NAS  $\geq 5$ ). As time progressed, there was nonetheless a gradual increase in the number of affected rats with the NBR group having the highest number of slides with a NAS  $\geq 5$  (42.59%) after 16 weeks (**Figures 7 and 8**). The differences in slides meeting the NAS scoring criteria between the corresponding intervention groups was only statistically significant for the last harvesting period ( $p=0.046$ ).



**Figure 8:** Changes in rates of non-alcoholic steatosis over time  
(Non-Beetroot group - group 1 rats; Beetroot group - group 2 rats)



## Discussion

The rising global prevalence of MASLD has necessitated the need for heightened preventive and reversal measures for the disease entity. Unfortunately, conventional medical therapies are limited by their side effects profile and limited ability to target multiple points in the cascade involved in the development of MASLD [7]. Furthermore, the cost of many recently approved medicines is out of reach of many potential users. Therefore, alternative measures, including the adoption of a healthy lifestyle and the use of beneficial plants as sources of nutraceuticals, are not only safe but also available for exploration [24, 25].

Our study protocol was able to induce a MASLD picture that initially included pericentral hepatic steatosis culminating, with continued exposure, to global steatohepatitis and fibrosis. A similar model has previously been used to induce metabolic syndrome and MAFLD in rats [26]. Progressive worsening of steatosis with continued exposure to the steatogenic diet was accompanied by biochemical changes reminiscent of a state of diabetes and dyslipidaemia, a finding that has been replicated in human subjects [11]. An imbalance between TG acquisition and removal by hepatocytes has been attributed to the development of steatosis in MAFLD with subsequent lipotoxicity-induced inflammation [27]. Furthermore, *de novo* lipogenesis (DNL) occurs in hepatocytes exposed to low-glycaemic index foods, including fructose, further exacerbating steatosis [28]. Using precision cut-liver slices, this hepatic steatosis in liver rats cultured in appropriate media has been demonstrated to develop within 24-hours and is mainly driven by insulin resistance, disruption in  $\beta$ -oxidation and impaired fatty acid transportation [29]. In the present study, insulin resistance was reflected by a rise in the triglyceride-glucose index. The elevation of this index was nonetheless attenuated by beetroot supplementation. Furthermore, and as used in the present study, a HFHF diet provides the necessary substrates to drive DNL and induce insulin resistance in hepatocytes thus, inducing progressive steatosis in hepatocytes [30]. Nevertheless, beetroot extract has been shown to counteract these biological processes and hence reduce liver steatosis and consequent hepatic damage [10]. The findings of the current study quantified the beneficial effects of beetroot extract with commendable temporal reduction in the occurrence of moderate and severe steatosis despite continued exposure of a steatogenic diet.

Continued hepatic steatosis has been documented to culminate in degenerative hepatocyte ballooning prior to the development of steatohepatitis. This process is driven by an imbalance in cellular metabolism coupled with increased oxidative stress and lipid toxicity [31]. Balloon degeneration was further associated with the presence of Mallory-Denk bodies and apoptotic bodies. These histological changes were accompanied, and as previously reported, by an elevation of hepatic transaminases and thrombocytopenia hallmarking the presence of NASH [12, 32]. The temporal and spatial pattern of hepatic injury recorded in the current study has previously been reported secondary to other hepatic insults [33, 34]. The increased hepatocyte ballooning closely mirrored increased dyslipidaemia and hyperglycaemia, further highlighting the role of these processes in its development [11, 31]. Similarly, oxidative stress has further been implicated in the development of ballooning [35]. Downstream, these cellular insults enhance the transcription and secretion of pro-inflammatory and pro-fibrotic factors, including perilipin and adipophilin, and products of the Sonic-Hedgehog gene [22]. Beetroot, on the other hand, contains important phytochemicals that have been known to ameliorate these biochemical and cellular changes and that predispose liver injury in MASLD, hence improving the hepatic histo-architecture [11, 36]. These findings were similarly realized in the current study, where supplementing the HFHF diet with crude beetroot extract resulted in a lesser degree of hepatocyte ballooning. Furthermore, beetroot has been shown to modulate the expression of genes vital for the progression of hepatocyte ballooning in MASLD, a process currently being evaluated as a key therapeutic target. Thus, beetroot offers an avenue necessitating further investigation as an important source of phytochemicals vital in curbing the progress of degenerative hepatocyte ballooning.

Increased hepatic steatosis and ballooning culminate in increased liver inflammation and fibrosis [22, 36]. As previously reported, and evident in our research findings, hepatic inflammation occurs as a late sequelae in

the spectrum that MASLD [11, 30, 37]. Nevertheless, the ability of crude beetroot extract to further ameliorate these changes was reflected by the lesser degree of mild and moderate inflammation noted in the beetroot supplemented group coupled with a greater percentage of non-existent inflammation across all the harvesting periods. Such ameliorative capacity is driven by the anti-inflammatory, anti-oxidative and cytoprotective properties of beetroot that, downstream, modulate gene and cytokine expression and hence, tamper with the development of extreme forms of steatohepatitis [9, 10]. This hepatoprotective effect of beetroot extract against an HFHF diet was further evidenced by the significant reduction in the overall MAS scores, especially in the latter stages of the experiment. Beetroot, therefore, offers immense potential as an excellent candidate for future research on the management of MASLD.

**Conclusion:** Beetroot reduces the histological changes associated with induced MASLD by lowering the severity of several MAS components while significantly improving associated biochemical parameters. Further research is therefore warranted to elucidate how best to harness this potential towards the management of MASLD.

## References

1. Lindenmeyer CC, McCullough AJ. The natural history of non-alcoholic fatty liver disease-an evolving view. *Clinical Liver Diseases*. 2018; 22: 11-21. doi: 10.1016/j.cld.2017.08.003
2. Godoy-Matos AF, Silva Júnior WS, Valerio CM. NAFLD as a continuum: From obesity to metabolic syndrome and diabetes. *Diabetology and Metabolic Syndrome*. 2020, 12: 60. doi: 10.1186/s13098-020-00570-y
3. Iqbal U, Perumpail BJ, Akhtar D, Kim D, Ahmed A. The epidemiology, risk profiling and diagnostic challenges of non-alcoholic fatty liver disease. *Medicines*. 2019; 6(1). 41. doi: 10.3390/medicines6010041
4. Seth A, Sherman KE. Fatty liver disease in persons with HIV infection. *Topics in Antiviral Medicine*. 2019; 27: 75-82. PMID: 31136997; PMCID: PMC6550355.
5. Zhu X, Huang Q, Ma S, Chen L, Wu Q, Wu L, et al. Presence of sarcopenia identifies a special group of lean NAFLD in middle-aged and older people. *Hepatology International*. 2023; 17: 313-325. doi: 10.1007/s12072-022-10439-z
6. Aso Y, Kato K, Sakurai S, Kishi H, Shimizu M, Jojima T, et al. Impact of dapagliflozin, an SGLT2 inhibitor, on serum levels of soluble dipeptidyl peptidase-4 in patients with type 2 diabetes and non-alcoholic fatty liver disease. *International Journal of Clinical Practice*. 2019; 73: e13335. doi: 10.1111/ijcp.13335
7. Chen JYS, Chua D, Lim CO, Ho WX, Tan NS. Lessons on drug development: A literature review of challenges faced in Non-alcoholic Fatty Liver Disease (NAFLD) clinical trials. *International Journal of Molecular Sciences*. 2022; 24: 158. doi: 10.3390/ijms24010158
8. Zemel MB, Kolterman O, Rinella M, Vuppalanchi R, Flores O, Barritt AS, et al. Randomized controlled trial of a leucine-metformin-sildenafil combination (NS-0200) on weight and metabolic parameters. *Obesity (Silver Spring)*. 2019; 27(1): 59-67. doi: 10.1002/oby.22346
9. Engin AB, Tsatsakis AM, Tsoukalas D, Engin A. Do flavanols-rich natural products relieve obesity-related insulin resistance? *Food and Chemical Toxicology*. 2018; 112: 157-167. doi: 10.1016/j.fct.2017.12.055
10. Al-Harbi LN, Alshammari GM, Al-Dossari AM, Subash-Babu P, Binobead MA, Alhussain MH, et al. Beta vulgaris L. (Beetroot) methanolic extract prevents hepatic steatosis and liver damage in T2DM rats by hypoglycemic, insulin-sensitizing, antioxidant effects, and upregulation of PPAR $\alpha$ . *Biology*. 2021; 10: 1306. doi: 10.3390/biology10121306
11. Fateh HL, Rashid SA, Muhammad SS, Al-Jaf SH, Ali AM. Comparing effects of beetroot juice and Mediterranean diet on liver enzymes and sonographic appearance in patients with non-alcoholic fatty liver disease: a randomized control trial. *Frontiers in Nutrition*. 2023; 10: 1181706. doi: 10.3389/fnut.2023.1181706
12. Munguti J, Makanya A, Obimbo M, Kipkorir V, Omondi D. Effect of beetroot juice supplementation on the physical and biochemical profiles of induced metabolic syndrome in rat. *Mediterranean Journal of Pharmacy and Pharmaceutical Sciences*. 2023; 3: 31-42. doi: 10.5281/zenodo.8329687
13. Kleiner DE, Brunt EM, Van Natta M, Behling C, Contos MJ, Cummings OW, et al. Design and validation of a histological scoring system for non-alcoholic fatty liver disease. *Hepatology*. 2005; 41: 1313-1321. doi: 10.1002/hep.20701
14. Takahashi Y, Fukusato T. Histopathology of non-alcoholic fatty liver disease/nonalcoholic steatohepatitis. *World Journal Gastroenterol*. 2014; 20: 15539-15548. doi: 10.3748/wjg.v20.i42.15539



15. Lonardo A, Nascimbeni F, Ballestri S, Fairweather D, Win S, Than TA, et al. Sex differences in NAFLD: State of the art and identification of research gaps. *Hepatology*. 2019; 70(4): 1457-1469. doi: 10.1002/hep.30626
16. Carrillo C, Rey R, Hendrickx, M Del Mar Cavia M, Alonso-Torre S. Antioxidant capacity of beetroot: Traditional vs novel approaches. *Plant Foods for Human Nutrition*. 2017; 72: 266-273. doi: 10.1007/s11130-017-0617-2
17. Harborne JB. *Phytochemical methods: A guide to modern techniques of plant analysis*. Springer Netherlands, Dordrecht, 1998. ISBN: 0412572605, 9780412572609.
18. Munguti J, Makanya A, Obimbo M, Kipkorir V. The effects of different short-term storage modalities on the anti-oxidant capacity of beetroot juice: Short term refrigeration of beetroot juice better preserves its antioxidant capacity. *Algerian Journal of Bioscience*. 2023; 4(2): 116-122. doi: Nil.
19. Mansoorian B, Combet E, Alkhalidy A, Garcia AL, Edwards CA. Impact of fermentable fibres on the colonic microbiota metabolism of dietary polyphenols rutin and quercetin. *International Journal of Environmental Research and Public Health*. 2019; 16: 292. doi: 10.3390/ijerph16020292
20. Munguti J, Obimbo M, Odula P, Sibuur W, Cheruiyot I. Hypervitaminosis A causes reversible liver volume changes independent of body mass in albino rats (*Rattus Norvegicus*). *Austin Journal of Anatomy*. 2018; 5(3): 1086. doi: Nil.
21. Brunt EM. Pathology of nonalcoholic fatty liver disease. *Nature Reviews Gastroenterology and Hepatology*. 2010; 7: 195-203. doi: 10.1038/nrgastro.2010.21
22. Fujii H, Ikura Y, Arimoto J, Sugioka K, Iezzoni JC, Park SH, et al. Expression of perilipin and adipophilin in non-alcoholic fatty liver disease; relevance to oxidative injury and hepatocyte ballooning. *Journal of Atherosclerosis and Thrombosis*. 2009; 16: 893-901. doi: 10.5551/jat.2055
23. Henkel J, Alfine E, Saín J, Jöhrens K, Weber D, Castro JP, et al. Soybean oil-derived poly-unsaturated fatty acids enhance liver damage in NAFLD induced by dietary cholesterol. *Nutrients*. 2018; 10(9): 1326. doi: 10.3390/nu10091326
24. Del Bo' C, Perna S, Allehdan S, Rafique A, Saad S, AlGhareeb F, et al. Does the Mediterranean diet have any effect on lipid profile, central obesity and liver enzymes in non-alcoholic fatty liver disease (NAFLD) subjects? *Nutrients*. 2023; 15: 2250. doi: 10.3390/nu15102250
25. Ndung'u W, Nurani K, Obimbo M, Odula P, Dimba E, Munguti J. Changes associated with dietary beetroot extract on diet-induced damage in the common carotid artery of the albino rat (*Rattus norvegicus*). *Anatomy Journal of Africa*. 2024; 13: 2617-2633. doi: 10.4314/aja.v13i2.4
26. Panchal SK, Poudyal H, Iyer A, Nazer R, Alam MA, Diwan V, et al. High-carbohydrate, high-fat diet-induced metabolic syndrome and cardiovascular remodeling in rats. *Journal of Cardiovascular Pharmacology*. 2011; 57: 611-624. doi: 10.1097/FJC.0b013e31821b1379
27. Manne V, Handa P, Kowdley KV. Pathophysiology of non-alcoholic fatty liver disease/non-alcoholic steatohepatitis. *Clinical Liver Disease*. 2018; 22: 23-37. doi: 10.1016/j.cld.2017.08.007
28. Kochan K, Kus E, Szafraniec E, Wislocka A, Chlopicki S, Baranska M. Changes induced by non-alcoholic fatty liver disease in liver sinusoidal endothelial cells and hepatocytes: Spectroscopic imaging of single live cells at the subcellular level. *The Analyst*. 2017; 142: 39483958. doi: 10.1039/c7an00865a
29. Smith GI, Shankaran M, Yoshino M, Schweitzer GG, Chondronikola M, Beals et al. Insulin resistance drives hepatic de novo lipogenesis in nonalcoholic fatty liver disease. *Journal of Clinical Investigation*. 2020; 130: 1453-1460. doi: 10.1172/JCI134165
30. Yustisia I, Tandiar D, Cangara MH, Hamid F, Daud NAS. A high-fat, high-fructose diet induced hepatic steatosis, renal lesions, dyslipidemia, and hyperuricemia in non-obese rats. *Heliyon*. 2022; 8: e10896. doi: 10.1016/j.heliyon.2022.e10896
31. Singla T, Muneshwar KN, Pathade AG, Yelne S. Hepatocytic ballooning in non-alcoholic steatohepatitis: bridging the knowledge gap and charting future avenues. *Cureus*. 2023; 15(9): e45884. doi: 10.7759/cureus.45884
32. Forlano R, Mullish BH, Dhar A, Goldin RD, Thursz M, Manousou P. Liver function tests and metabolic-associated fatty liver disease: Changes in upper normal limits, does it really matter? *World Journal of Hepatol*. 2021; 13: 2104-2112. doi: 10.4254/wjh.v13.i12.2104
33. Munguti JK, Obimbo MM, Odula PO, Makanya AN, Sibuur WO. Hypervitaminosis A causes reversible changes in the density of hepatocytes and hepatic stellate cells of Albino rats (*Rattus norvegicus*). *Journal of Morphological Sciences*. 2020; 37: 82-87. doi: 10.51929/jms.37.14.2020
34. Nurani K, Pulei A, Olabu B, Munguti J, Chaudhry T, Kipkorir V. Stereological estimation and zonal distribution of the hepatotoxic effects of doxorubicin on the female albino rat (*Rattus norvegicus*). *International Journal of Medical Students*. 2023; 11: 184-190. doi: 10.5195/ijms.2023.1859
35. Li Y-Y, Zheng T-L, Xiao S-Y, Wang P, Yang W-J, Jiang L-L, et al. Hepatocytic ballooning in non-alcoholic steatohepatitis: Dilemmas and future directions. *Liver International*. 2023; 43: 1170-1182. doi: 10.1111/liv.15571

36. Aliahmadi M, Amiri F, Bahrami, LS, Hosseini AF, Abiri B, Vafa M. Effects of raw red beetroot consumption on metabolic markers and cognitive function in type 2 diabetes patients. *Journal of Diabetes and Metabolic Disorders*. 2021; 20: 673-682. doi: 10.1007/s40200-021-00798-z
37. Rangwala F, Guy CD, Lu J, Suzuki A, Burchette JL, Abdelmalek MF, et al. Increased production of sonic hedgehog by ballooned hepatocytes. *Journal of Pathology*. 2011; 224: 401-410. doi: 10.1002/path.2888

**Author contribution:** JKM, ANM & MMO conceived and designed the study. JKM, VKK & BMN collected data. All authors contributed to data analysis and drafted the manuscript/revised it for important intellectual context. All the authors approved the final version of the manuscript and agreed to be accountable for its contents.

**Conflict of interest:** The authors declare the absence of any commercial or financial relationships that could be construed as a potential conflict of interest.

**Ethical issues:** The authors completely observed ethical issues, including plagiarism, informed consent, data fabrication or falsification, and double publication or submission.

**Data availability statement:** The raw data that support the findings of this article are available from the corresponding author upon reasonable request.

**Author declarations:** The authors confirm that they have followed all relevant ethical guidelines and obtained any necessary IRB and/or ethics committee approvals.

**Generative AI disclosure:** No generative AI was used in the preparation of this manuscript.

يُحسّن مستخلص الشمندر الخام من حالة الكبد الدهني المرتبط باضطرابات التمثيل الغذائي، وذلك بتحسين مؤشر نشاط MAS في نموذج تجريبي على الفئران.

جيريميا ك. مونغوتي 1\*، أندرون. ماكانيا 2، موسى م. أوبيمبو 3  
فينسنت ك. كيبكورير 4، وبن م. نجوغونا 5

- 1 قسم التشريح البشري وعلم وظائف الأعضاء الطبية، جامعة نيروبي، نيروبي، كينيا
  - 2 قسم التشريح البيطري وعلم وظائف الأعضاء، جامعة نيروبي، نيروبي، كينيا
  - 3 قسم التشريح البشري وعلم وظائف الأعضاء الطبية، جامعة نيروبي، نيروبي، كينيا
  - 4 أمانة كلية الجراحين لشرق ووسط وجنوب أفريقيا (COSESCA)، أروشا، تنزانيا
  - 5 كلية العلوم الصحية، جامعة نيروبي، نيروبي، كينيا
- \* المؤلف المسؤول عن المراسلات

**ملخص:** يتزايد عبء مرض الكبد الدهني المرتبط بخلل التمثيل الغذائي (MASLD). العلاج الموجه إما مكلف أو غير متوفر. مع ذلك، يحتوي البنجر على مواد كيميائية نباتية أثبتت نوعياً قدرتها على تثبيط تطور مرض الكبد الدهني المرتبط بخلل التمثيل الغذائي. سعينا، باستخدام علم التجسيم، إلى تحديد القدرة التحسينية لمستخلص البنجر الخام على تطور مرض الكبد الدهني المرتبط بخلل التمثيل الغذائي. درست 45 فأراً وقُسمت إلى ثلاثة أقسام: المجموعة الأولى: فئران تغذت على نظام غذائي عالي السعرات الحرارية؛ المجموعة الثانية: فئران تغذت على نظام غذائي عالي السعرات الحرارية ومستخلص البنجر الخام بتركيز 200 ملغم/كغم؛ بينما تغذت المجموعة الثالثة على علف الفئران القياسي. أُعدمت خمسة فئران من المجموعتين الأولى والثانية قتلًا رحيماً في الأسابيع 4 و8 و12 و16، وأُخذت عينات دم للتحليل الكيميائي الحيوي. بعد ذلك، جُمعت الأكباد، واستُخدمت طريقة أخذ عينات عشوائية منتظمة لاختيار العينات النسيجية اللازمة للمعالجة. أُخذت صور، واستُخدم مبدأ كافالييري لحساب النقاط لتحديد درجة نشاط MASLD (MAS) كما هو مُبين: سجّل التدهن الكبدي من 0 إلى 3؛ وسجّل الالتهاب الفصيبي من 0 إلى 3 (بؤر/مجال X200)، وسجّل التضخم الكبدي من 0 إلى 2. أدى اتباع نظام غذائي عالي السعرات الحرارية إلى ارتفاع سكر الدم، وخلل شحميات الدم، وارتفاع مؤشر الدهون الثلاثية-الجلوكوز، مصحوباً بزيادة مؤقتة في شدة التدهن الكبدي، والتضخم الكبدي، والالتهاب. زدادت قيمة MAS مع مرور الوقت، وبلغت أعلى مستوياتها في الأسبوع السادس عشر للمجموعة 1 مقارنةً بالمجموعة 2. أبطأ تناول مكملات البنجر تضخم خلايا الكبد (78.0% مقابل 65.0%)، وأدى إلى انخفاض معدلات الالتهاب المتوسط والتدهن الكبدي الشديد. كما أظهرت المؤشرات البيوكيميائية المصاحبة تحسناً ملحوظاً. يُقلل البنجر من التغيرات النسيجية المرتبطة بـ MASLD المُستحث عن طريق خفض شدة العديد من مكونات MAS، مع تحسين ملحوظ في المعايير البيوكيميائية المرتبطة بها.