











ORIGINAL RESEARCH article

Protective effects of curcumin on spleen parenchyma in rats treated with dexamethasone

Gloria Natalia Wafula^{1*}  , Boniface Chege²  , Isaac Cheruiyot¹  
Fawzia Butt¹  , and Jeremiah Munguti¹  

¹Department of Human Anatomy and Medical Physiology, University of Nairobi, Nairobi, Kenya

²School of Health Sciences, Dedan Kimathi University of Technology, Nyeri, Kenya

*Author to whom correspondence should be addressed

Article number: 189, **Received:** 07-01-2025, **Accepted:** 02-02-2025, **Published online:** 04-02-2025

Copyright© 2025. This open-access article is distributed under the *Creative Commons Attribution License*, which permits unrestricted use, distribution, and reproduction in any medium, provided the original work is properly cited.

HOW TO CITE THIS

Wafula et al. (2025) Protective effects of curcumin on spleen parenchyma in rats treated with dexamethasone. *Mediterr J Pharm Pharm Sci.* 5 (1): 87-96. [Article number: 189]. <https://doi.org/10.5281/zenodo.14802068>

Keywords: Dexamethasone, curcumin, spleen, white pulp, red pulp

Abstract: Prolonged use of corticosteroids like dexamethasone reduces immune cells through oxidative stress, leading to splenic parenchymal changes such as reduced size and relative volume densities of white pulp areas. Curcumin, an antioxidant found in turmeric, may protect against these effects. This study evaluated the spleen's parenchymal changes in male rats after dexamethasone and curcumin administration, emphasizing white and red pulp areas. Twenty-six male Wistar rats (aged two months) were studied. The control group received standard chow and water (n=6), while experimental groups were administered dexamethasone or dexamethasone with curcumin (n=20). Dexamethasone was injected daily at 0.6 mg/kg for 14 days, and curcumin was given orally at 200 mg/kg. Rats were sacrificed on days 7 and 14. Spleens were processed and stained using hematoxylin and eosin, and histo-morphological changes were quantified using Fiji Image J. Dexamethasone administration led to significantly lower white pulp volumetric density [0.34 vs. 0.26, p=0.002] compared to the controls. The ratio of white pulp to red pulp volumetric density decreased significantly [0.64 vs. 0.51, p<0.001], with these changes becoming more pronounced by day 14. The red pulp volumetric density remained relatively unchanged (p=0.256). Curcumin administration alongside dexamethasone lessened the white pulp damage, with white pulp volumetric density on day 14 showing no significant difference compared to the control [0.35 vs. 0.34, p=0.887]. Thus, dexamethasone significantly impacts the spleen's white pulp with minimal effects on the red pulp. Curcumin mitigates dexamethasone-induced white pulp damage.

Introduction

The spleen is crucial for immune function. It consists of the white pulp (WP), which initiates adaptive immune responses, and the red pulp (RP), which filters blood and supports immune cell functions [1, 2]. Immunosuppression, whether due to infectious agents or pharmacological treatments, can lead to significant alterations in splenic structure, such as follicular hyperplasia and lymphocyte depletion [3, 4]. Corticosteroids like dexamethasone are essential for managing inflammation and immune responses in conditions such as COVID-19

and allergies [5]. However, their prolonged use is associated with adverse effects including osteoporosis, hyperglycemia, and increased infection risk [5-7]. Understanding these effects becomes particularly important when corticosteroids are used for non-immunological purposes, such as in treating of certain cancers or neurological conditions, where their impact on the spleen and overall immune function needs careful consideration [8, 9].

Dexamethasone, a potent corticosteroid, is commonly used clinically and experimentally to induce immunosuppression [10]. In rat models, it has been shown to reduce spleen size and weight by inducing lymphocyte apoptosis and lymphoid organ atrophy. Histological effects include damage to the WP follicular zones, and fibrinoid accumulation within red pulp areas [11-13]. These changes underscore the need for potential protective interventions, especially when the drug is used for conditions unrelated to immune system modulation.

Curcumin, the active compound in turmeric, is known for its anti-inflammatory and antioxidant properties [14]. It activates the Nrf2 pathway and downregulates the enzyme cyclooxygenase-2 (COX-2), potentially counteracting oxidative stress and inflammation that are hallmark features of cellular injury [15-16]. Curcumin has demonstrated the ability to enhance spleen cell proliferation and improve tissue structure in various models [17]. It mitigates damage from environmental toxins and supports immune function [18, 19]. However, its effects on dexamethasone-induced splenic damage remain under-researched. This study aimed to address this gap by examining curcumin's potential to protect against dexamethasone-induced changes in spleen parenchyma.

Materials and methods

Study design and sample: This was a quasi-experimental study. Albino male adult Wistar rats (age: two months) were selected as the animal model due to their ease of maintenance, short life cycle, and physiological similarities to humans, particularly in studies of splenic features and immunosuppression [20, 21]. Male rats were used in this study due to their higher susceptibility to the effects of glucocorticoids compared to females. Research shows that male rats respond more strongly to glucocorticoid treatment while female rats may have protective effects from estrogens and differences in corticosteroid receptor expression [22]. Rats were selected based on their weight (100 g to 200 g). Sick animals or those outside this range were excluded.

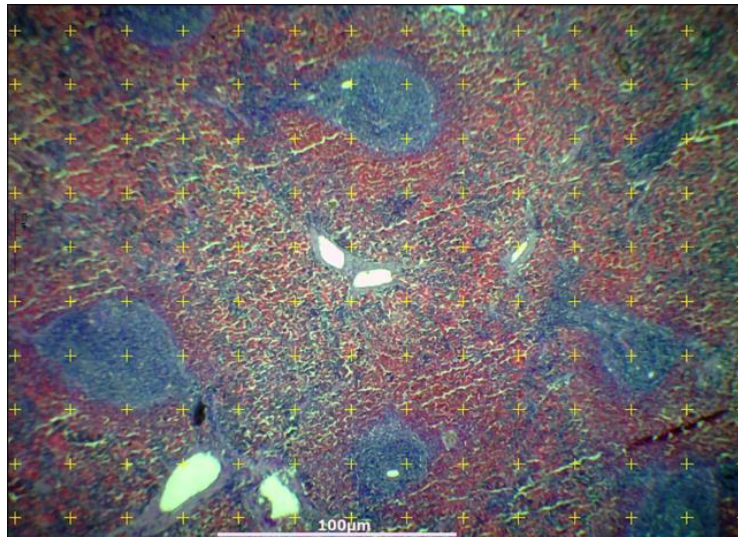
Preparation and administration of dexamethasone and curcumin for administration: Dexamethasone was prepared by diluting Dexasona (4.0 mg/ml) to a concentration of 0.4 mg/ml in distilled water and administered intramuscularly at a dosage of 0.6 mg/kg body weight. The dose was chosen based on its recognition as a therapeutic daily dose in rat models that is known to induce immunosuppression without excessive toxicity. This dose has been used in previously investigating the immunosuppressive effects of dexamethasone, including its effects on spleen morphology, which aligns with the aims of the current study. Specifically, a dose of 0.6 mg/kg body weight has been reported to cause significant immunosuppressive changes, including alterations in the structural components of the spleen, similar to those observed with other immunosuppressive agents like medroxyprogesterone acetate (MPA) [23]. Studies have also demonstrated that intramuscular (IM) administration of dexamethasone effectively induces immunosuppression in rats. For instance, a study evaluating the effects of dexamethasone on spleen morphology in female rats administered IM doses of 0.6 mg/kg and 3.0 mg/kg for seven days observed significant reductions in the WP and marginal zones of the spleen, indicating immunosuppressive activity [23]. In addition, a study comparing IM and intravenous (IV) administration of dexamethasone in rats found that IM injection provided rapid absorption with high bioavailability (86.0%), suggesting that IM administration is an effective route for systemic delivery of dexamethasone [24]. Curcumin, sourced from Webber

Naturals capsules containing 600 mg of curcumin each, was dissolved in distilled water to achieve a final concentration of 250 mg/kg body weight. Administering curcumin at a dose of 250 mg/kg in rats is supported by studies demonstrating its efficacy and safety at this level. For instance, research on diabetic rats induced by a high-fat diet plus streptozotocin administered curcumin at doses of 50, 150, or 250 mg/kg body weight for seven weeks. The study found that curcumin dose-dependently decreased plasma lipids and glucose, with 150 mg/kg being adequate to produce a significant effect. However, the 250 mg/kg dose was used to assess the dose-dependent effects of curcumin [25]. Additionally, a study investigating the pharmacokinetics and pharmacodynamics of curcumin in rats administered an oral dose of 250 mg/kg body weight. This research provided insights into the absorption and systemic availability of curcumin at this dosage [26]. The rats were housed in standard cages, allowed to acclimatize for seven days, and provided with standard chow and water ad libitum. Dexamethasone was administered IM to group B at a dose of 0.6 mg/kg body weight daily for 14 days. Group C received both dexamethasone (0.6 mg/kg) and curcumin (250 mg/kg) daily for 14 days via oral gavage. The control group (group A) received sham injections while being maintained on standard chow and water. The 14-day duration was selected based on prior studies demonstrating that this period is sufficient to induce significant immune-suppressive effects on the spleen while balancing the need to observe progressive structural changes without excessive systemic toxicity [23].

Harvesting and processing of spleen: Following the treatment period, rats were euthanized using halothane in a well-ventilated room. The spleens were carefully dissected and weighed. Scherle's method was used to assess spleen volume, providing an estimate of splenic size based on fluid displacement. The length and width of each spleen were then measured using digital calipers. The spleens were sectioned into five equal parts, as measured using a ruler to ensure consistency across samples. These sections were fixed in 10.0% formalin, dehydrated, and embedded in paraffin blocks. Systematic random sampling was employed to select five ribbon sections from each block, which were subsequently stained with Hematoxylin and Eosin for microscopic examination, enabling detailed histological analysis.

Stereological assessment: From each of the slides; three images were captured, from three non-overlapping fields of view, using a Motic Digital Camera and analyzed with Image J software. To estimate the volumetric densities of WP and RP in spleen samples, we utilized the Cavalieri principle of point counting [23]. This process began with sampling five different sections from each rat through simple random sampling. From these sections, we created five different slides using systematic random sampling of the ribbons, selecting every 3rd ribbon and subsequently every 2nd ribbon. Each slide was then examined under a microscope, capturing images at a magnification of X40. For each slide, three random fields were captured. The selected histological areas were analyzed following the techniques described previously [24]. It superimposed a 120-point grid on the digital images displayed on the monitor screen. This grid system, with regularly arranged lines and point probes, facilitated the estimation of specific tissue densities [23]. The volumetric densities (V_v) of the histological structures were evaluated without knowledge of the source of the tissue samples. According to stereological principles, in isotropic tissue, the distribution area of a specific structure, as seen in a two-dimensional section, is proportional to the volume distribution of that structure [24]. The V_v of the histological components were then calculated using the formula $V_v = P_p/P_t$, where V_v represents the volume density, p indicates the tissue component under consideration (either WP or RP), P_p is the number of test points associated with p , and P_t is the total number of points in the test system. Finally, the WP: RP ratios were determined by dividing the specific WP volumetric density by the RP volumetric densities, expressing these results as ratios. **Figure 1** below illustrates the test point system used.

Figure 1: Test point system used for stereological assessment



Ethical considerations: Approval to conduct the study was obtained from the Biosafety, Animal Use and Ethics Committee, Faculty of Veterinary Medicine, University of Nairobi (REF: FVM BAUEC/2024/545). Rats were handled by a qualified animal house technician according to the guidelines provided therein.

Statistical analysis: Stereological data were entered into the SPSS software (27.0, Chicago, Illinois) for analysis. Body weight change was calculated as the difference between baseline weight (measured at the start of the experiment) and weight at the respective harvest periods (days 7 and 14). Volumetric densities were reported as ratios. The data were grouped into: Control and experimental groups (dexamethasone only and dexamethasone plus curcumin) groups. After confirming that the data was not normally distributed, box plots and histograms were used and non-parametric tests were used for univariate analysis. Kruskal Wallis H-test was used to compare the medians of the body weight changes and volumetric densities in the three groups per harvesting period; days 7 and 14. Mann Whitney U test was used to compare the medians in the body weight changes and volumetric densities between days 7 and 14 per group. A $p < 0.05$ was considered significant at a 95% confidence interval.

Results

During the study period, rats were consistently observed, revealing differences in feeding and social behavior across groups. Control rats showed active social interactions and maintained normal feeding habits, the latter of which were reflected in their consistent weight gain throughout the study period. In comparison, the dexamethasone-only group exhibited significantly reduced food intake, increased social withdrawal, and signs of distress such as hunched posture, unkempt fur, and shallow breathing. The dexamethasone plus curcumin group showed decreased feeding and some social withdrawal, but these effects were less severe than in the dexamethasone-only group. Relative to weights at baseline (start of the study), the dexamethasone-only group experienced a greater weight change (loss) by day 14 of the study than the control group [-11 g (95% CI -15--7) vs 6 g (95% CI 4-6), $p = 0.007$]. The dexamethasone plus curcumin group, however, had a lower degree of weight loss compared to the dexamethasone-only group [-1 g (95% CI -4.5-2) vs [-11 g (95% CI -15--7), $p = 0.031$]. No significant changes in weight were seen between the control group and the dexamethasone plus curcumin group ($p = 0.280$).

Histomorphological changes in spleen parenchyma

The parenchymal architecture in the dexamethasone-only group showed significant atrophy of the WP with reduced lymphoid follicle size and obliteration of marginal zones. The RP maintained its overall structure with no apparent differences across the three groups. These degenerative alterations intensified from day 7 to day 14. Conversely, the dexamethasone plus curcumin group demonstrated a relatively preserved WP structure with only slight reductions in follicle size and partial maintenance of marginal zones [Figure 2]. **Figures 2.1** and **2.4**: Well-organized WP and RP in control rats at days 7 and 14, respectively. **Figures 2.2** and **2.5**: Marked reduction in WP size and loss of marginal zones in the dexamethasone-only group at days 7 and 14, respectively. **Figures 2.3** and **2.6**: Moderately preserved WP and marginal zones in dexamethasone plus curcumin group at days 7 and 14, respectively.

Figure 2: Histomorphological changes in splenic parenchyma

Figure 2.1: Control: day 7

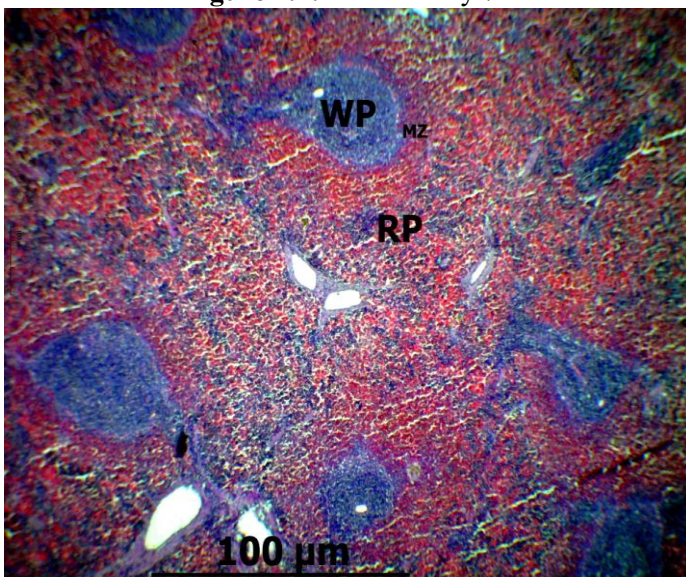


Figure 2.2: Dexamethasone: day 7

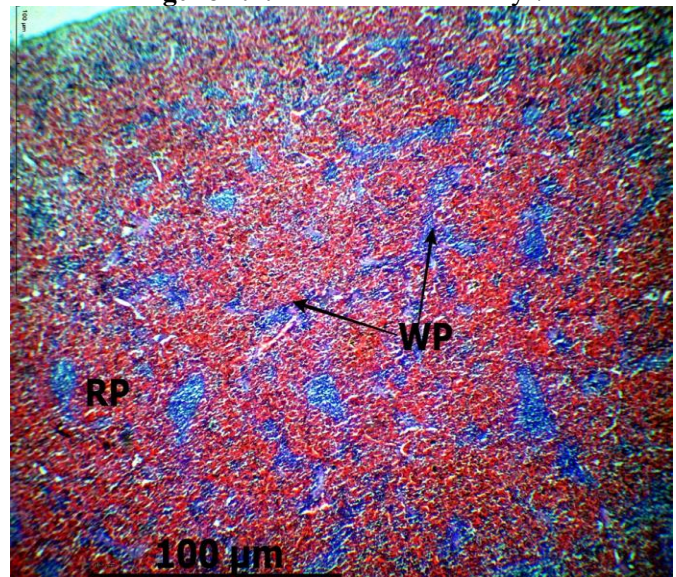


Figure 2.3: Dexamethasone + Curcumin: day 7

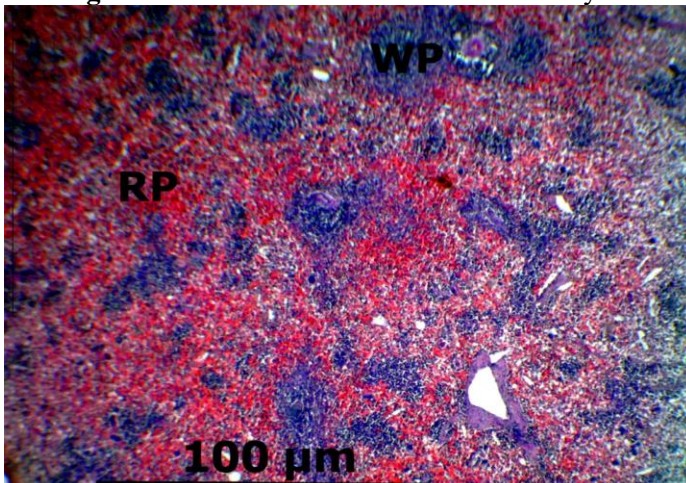


Figure 2.4: Control: day 14

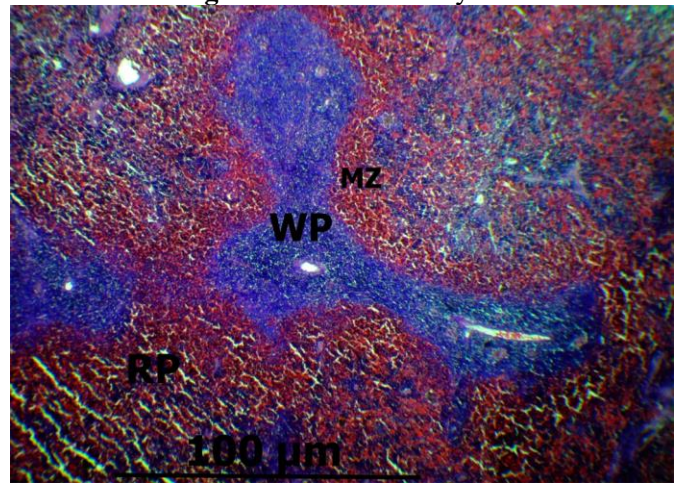


Figure 2.5: Dexamethasone: day 14

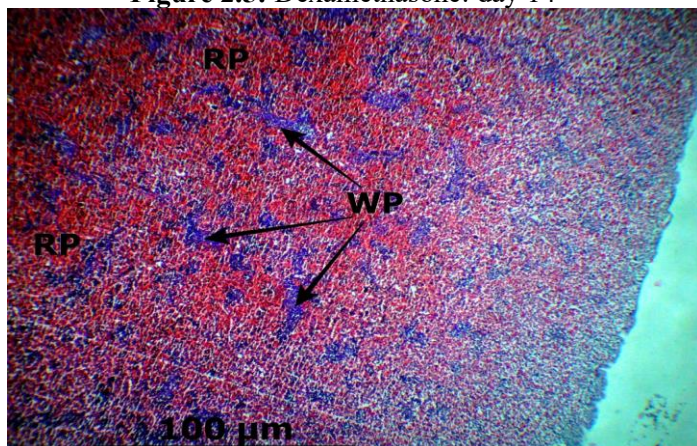
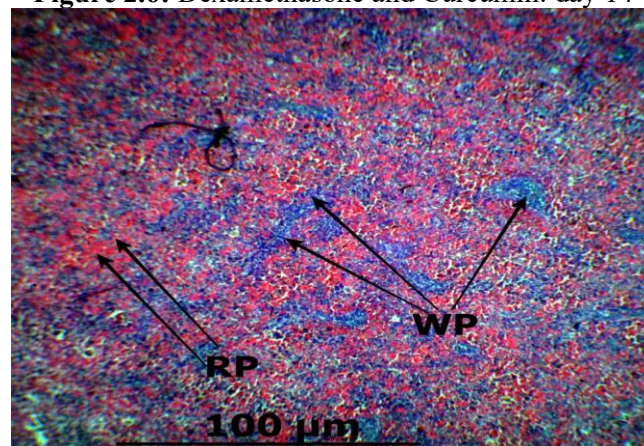


Figure 2.6: Dexamethasone and Curcumin: day 14

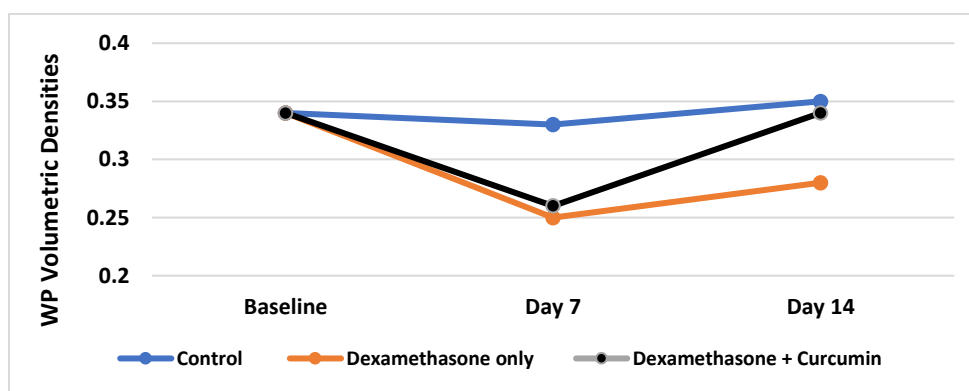


Histomorphological changes in the splenic parenchyma. The white pulp (WP) and marginal zone (MZ) are affected in the dexamethasone-only group, while the red pulp (RP) remains largely unaffected.

Stereological changes

Differences in white pulp volumetric density (WPVD) across groups: Quantitative analysis revealed a significant reduction in WPVD in the dexamethasone-only group compared to controls at day 7 and day 14. Specifically, WPVD decreased from 0.33 (IQR 0.14) in controls to 0.26 (IQR 0.11) at day 7 [$p=0.002$] and from 0.35 (IQR 0.11) to 0.28 (IQR 0.13) at day 14 ($p<0.001$). In contrast, the dexamethasone plus curcumin group showed an initial decrease in WPVD at day 7 0.26 (IQR 0.09) followed by a significant increase by day 14 0.34 (IQR 0.11), approaching values comparable to controls and significantly higher than the dexamethasone-only group ($p<0.001$) (**Figure 3**).

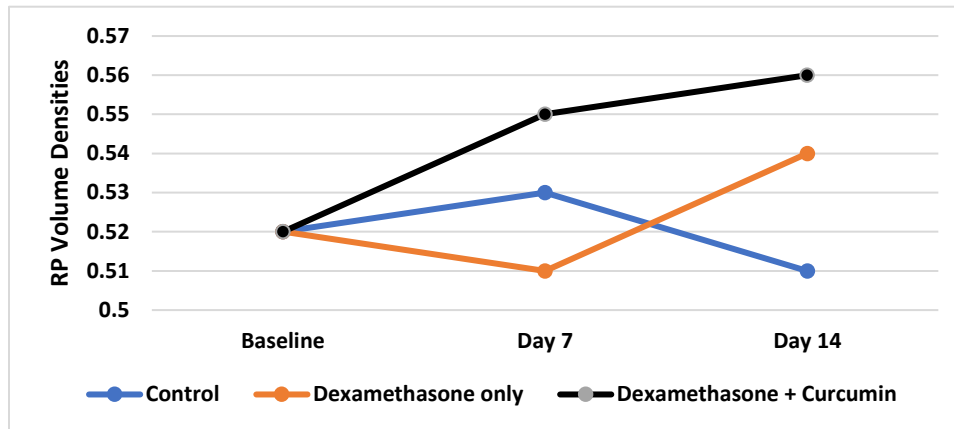
Figure 3: Comparison of white pulp volumetric densities across groups and time points



Data are median (interquartile range [IQR]). The dexamethasone-only group showed highly significant reduction in WPVD compared to controls on day 7 and day 14 ($p=0.002$, $p<0.001$), respectively. The dexamethasone-curcumin group demonstrated an increase in WPVD from day 7 to day 14, matching the control group and highly significantly exceeding the dexamethasone-only group ($p<0.001$)

Differences in red pulp volumetric density (RPVD) across groups: No significant differences in RPVD were observed among the control and treatment groups across all time points. The RPVD remained relatively stable, with minor fluctuations that were not significant. For instance, the control group exhibited RPVDs of 0.52 [IQR 0.05] at baseline, 0.53 (IQR 0.13) at day 7, and 0.51 (IQR 0.08) at day 14 ($p=0.287$). Similar nonsignificant trends were noted in both treatment groups, indicating that dexamethasone, with or without curcumin, did not markedly affect the RP volume (**Figure 4**).

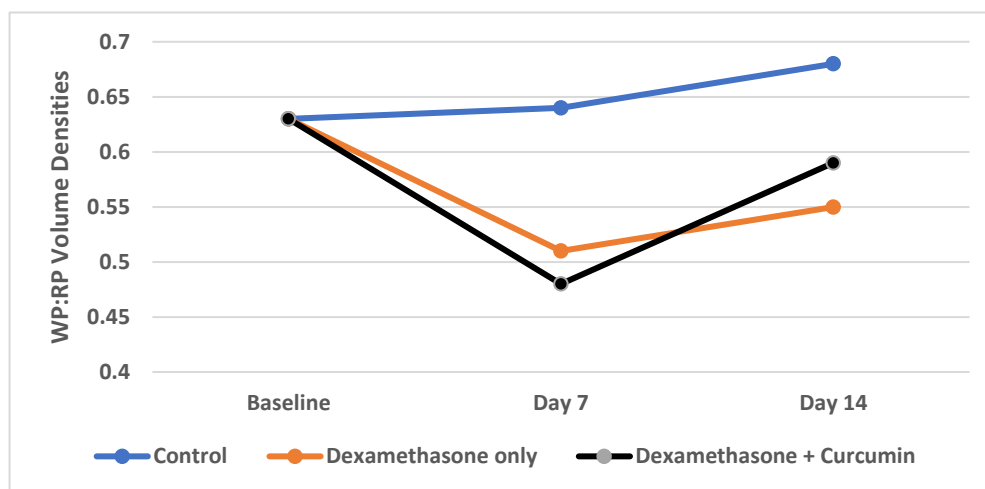
Figure 4: Comparison of red pulp volumetric densities across groups and time points



Data are median (interquartile range [IQR]). No significant differences in RPVD were observed among the control and treatment groups across all time points [$p=0.287$]. The control group exhibited RPVDs of 0.52 (IQR 0.05) at baseline, 0.53 (IQR 0.13) at day 7, and 0.51 (IQR 0.08) at day 14. Both treatment groups (dexamethasone and dexamethasone-curcumin) displayed similar nonsignificant trends, indicating no marked effect on RPVD in response to the treatments

Differences in WPVD to RP ratio across groups: The WPVD ratio exhibited significant alterations corresponding to the treatments administered. In the dexamethasone-only group, there was a notable reduction in the ratio at both day 7 0.51 (IQR 0.25) and day 14 0.55 (IQR 0.46) compared to controls, indicating a disproportionate loss of WP relative to RP ($p < 0.001$). Conversely, the dexamethasone plus curcumin group showed an initial decrease at day 7 0.48 (IQR 0.23) followed by a significant rebound at day 14 0.59 (IQR 0.25), suggesting recovery towards normal splenic architecture facilitated by curcumin administration. These findings highlight curcumin's potential role in preserving and restoring splenic structural balance disrupted by dexamethasone-induced immune-suppression (**Figure 5**).

Figure 5: Comparison of white pulp to red pulp ratios across groups and time points



Data are median [interquartile range [IQR]]. The dexamethasone-only group showed a significant reduction in WPVD compared to the control group at day 7 and day 14 ($p=0.002$, $p<0.001$), respectively. The dexamethasone-curcumin group demonstrated an increase in WPVD from day 7 to day 14, aligning with the control group and significantly exceeding the dexamethasone-only group at day 14 ($p<0.001$)

Discussion

This study investigates the impact of dexamethasone on spleen morphology and histology, focusing on curcumin's potential protective effects. Dexamethasone remarkably reduces splenic weight and affects lymphocyte-rich WP pulp areas, while curcumin appears to mitigate these changes, preserving splenic structure and function. The findings align with existing data on glucocorticoid-induced splenic alterations and suggest curcumin may offer a protective benefit, warranting further exploration of its clinical potential in managing corticosteroid-related complications. A significant reduction in the size and number of WP areas was noted in the dexamethasone-only group, in keeping with a previous study [27]. The reduction in WP indicates potential B-cell defects, which aligns with Mitevaska and others [28]. The peri-arteriolar lymphatic sheath (PALS), usually the T cell areas, did not show any marked reduction in size. This suggests that B-cell areas may be more sensitive to the effects of excess glucocorticoids than T-cell areas [29, 30]. Previous studies have shown that long-term use of dexamethasone could affect B-cell transformation by suppressing growth and causing cellular defects [11]. With regard to splenic T cells, dexamethasone was shown to exert a dose-dependent reduction in general, helper, cytotoxic, and regulatory T cells, resulting in the reduction of size or complete absence of PALS region [31]. In the present study, however, no histological differences were observed in the PALS. This could be due to the dose and duration of dexamethasone which was lower than that required to cause marked T cells changes [32]. Histological analysis revealed that the structural integrity of the WP was better preserved in the dexamethasone-curcumin group compared to the dexamethasone-only group. Specifically, the WPVD in the dexamethasone-curcumin group showed less reduction in comparison to the dexamethasone-only group. These findings are similar to those obtained by Tarasub et al. [21] who demonstrated that pretreatment of rats with curcumin before cadmium application prevents changes in the spleen WP. Also, on administration of curcumin in STZ-induced diabetic rats, observed that the ratio of RP (parenchyma and sinusoids) to WP [immune lymphocytes and macrophages] was significantly reduced with curcumin administration, suggesting increased immunological function [33]. The preservation of WP areas in the dexamethasone-curcumin group suggests that curcumin effectively counters the immunosuppressive and cytotoxic effects of dexamethasone. Curcumin's protective effects on the WP areas could be attributed to its enhancement of splenic B and T cell proliferation in *in-vitro* studies [16, 19], indicating its potential in maintaining immune function under conditions of corticosteroid-induced immunosuppression. Curcumin's mitigative effects on damage of lymphoid areas of the spleen were better seen on day 14, as evidenced by a larger WPVD compared to day 7, suggesting that the protective effects of curcumin could be time-dependent [34]. There are conflicting views on the effect of dexamethasone on splenic RP morphometry and density. Dexamethasone caused the narrowing of cords and the widening of venous sinusoids in the splenic RP of rats, especially when administered at a maximal therapeutic dosage (30 mg/kg of body weight per day) [28]. The current study, however, did not find any significant changes in the RP, similar to the previously reported findings [29]. A possible explanation for this discrepancy lies in the dose-dependent effects of dexamethasone; with higher doses of dexamethasone increasing ROS production by myeloid cells within the RP causing their apoptosis [35, 36]. Thus, the absence of morphological changes in the splenic RP in the current study could be attributed to the lower dose of dexamethasone, which may not induce the same level of reactive oxygen species production and tissue remodeling observed at higher doses. This highlights the importance of considering dosage when evaluating the histopathological impacts of glucocorticoid therapy.

Conclusion: Dexamethasone significantly impacts the white pulp areas of the spleen, with minimal effect on red pulp areas. Curcumin attenuates these adverse effects of dexamethasone on white pulp structure.

References

1. Cesta MF (2006) Normal structure, function, and histology of the spleen. *Toxicologic Pathology*. 34 (5): 455-465. doi: 10.1080/01926230600867743
2. Lewis SM, Williams A, Eisenbarth SC (2019) Structure and function of the immune system in the spleen. *Science Immunology*. 4 (33): eaau6085. doi: 10.1126/sciimmunol.aau6085
3. Falk S, Mýller H, Stutte HJ (1988) The spleen in acquired immunodeficiency syndrome (AIDS). *Pathology, Research Practice*. 183 (4): 425-433. doi: 10.1016/s0344-0338(88)80089-x
4. Vidya Vijayan KK, Karthigeyan KP, Tripathi SP, Hanna LE (2017) Pathophysiology of CD4+ T-cell depletion in HIV-1 and HIV-2 infections. *Frontiers in Immunology*. 8: 580. doi: 10.3389/fimmu.2017.00580
5. Johnson DB, Lopez MJ, Kelley B (2023) Dexamethasone. In: StatPearls [Internet]. Treasure Island (FL): StatPearls Publishing. Bookshelf ID: NBK482130. PMID: 29489240.
6. Hodgens A, Sharman T (2024) Corticosteroids. In: StatPearls [Internet]. Treasure Island (FL): StatPearls Publishing. Bookshelf ID: NBK554612PMID: 32119499
7. Noreen S, Maqbool I, Madni A (2021) Dexamethasone: Therapeutic potential, risks, and future projection during COVID-19 pandemic. *European Journal of Pharmacology*. 894: 173854. doi: 10.1016/j.ejphar.2021.173854
8. Brassard P, Bitton A, Suissa A, Sinyavskaya L, Patenaude V, Suissa S (2014) Oral corticosteroids and the risk of serious infections in patients with elderly-onset inflammatory bowel diseases. *The American Journal of Gastroenterology*. 109 (11): 1795-1802. doi: 10.1038/ajg.2014.313
9. Dixon WG, Abrahamowicz M, Beauchamp ME, Ray DW, Bernatsky S, Suissa S, Sylvestre MP (2012) Immediate and delayed impact of oral glucocorticoid therapy on risk of serious infection in older patients with rheumatoid arthritis: a nested case-control analysis. *Annals of the Rheumatic Disease*. 71 (7): 1128-1133. doi: 10.1136/annrheumdis-2011-200702
10. Jeklova E, Leva L, Jaglic Z, Faldyna M (2008) Dexamethasone-induced immunosuppression: a rabbit model. *Veterinary Immunology and Immunopathology*. 122 (3-4): 231-240. doi: 10.1016/j.vetimm.2007.11.011
11. Dehghani F, Hossieni SA, Noorafshan A, Panjehshahin MR, Esmaeelpour T (2021) Effect of selenium on quantitative structural changes in dexamethasone-induced immunodeficiency rat models. *Iranian Journal of Medical Sciences*. 46 (2): 128-135. doi: 10.30476/ijms.2020.81137.0
12. Freeman SJ (2011) Spleen. In: Allan PL, Baxter GM, Weston MJ. *Clinical Ultrasound*. 3rd Ed., Edinburgh: Churchill Livingstone. ISBN: 9780702031311.
13. Goya RG, Cónsole GM, Spinelli OM, Carino MH, Riccillo F, Corrons FJ (2003) Glucocorticoid-induced apoptosis in lymphoid organs is associated with a delayed increase in circulating deoxyribonucleic acid. *Apoptosis*. 8 (2): 171-177. doi: 10.1023/a:1022922726418
14. Menon VP, Sudheer AR (2007) Antioxidant and anti-inflammatory properties of curcumin. *Advances in Experimental Medicine and Biology*. 595: 105-125. doi: 10.1007/978-0-387-46401-5_3
15. Bhaskar N, Rojas LO, Jehu T, Beg S, Bhanusali N (2020) Curcumin: Prevalence and perceived efficacy in the treatment of rheumatoid and psoriatic arthritis. *Rheumatology*. 72 (Suppl 10): 1230. doi: Nil.
16. Jakubczyk K, Drużga A, Katarzyna J, Skonieczna-Żydecka K (2020) Antioxidant potential of curcumin-A meta-analysis of randomized clinical trials. *Antioxidants*. 9 (11): 1092. doi: 10.3390/antiox9111092
17. Mohammadi A, Mashayekhi K, Navashenaq JN, Haftcheshmeh SM (2022) Curcumin as a natural modulator of B lymphocytes: Evidence from in vitro and in vivo studies. *Mini-Reviews in Medicinal Chemistry*. 22 (18): 2361-2370. doi: 10.2174/1389557522666220304122916
18. Emam MA, Farouk SM, Aljazzar A, Abdelhameed AA, Eldeeb AA, Gad FAM (2022) Curcumin and cinnamon mitigate lead acetate-induced oxidative damage in the spleen of rats. *Frontiers in Pharmacology*. 13: 1072760. doi: 10.3389/fphar.2022.1072760
19. Mustafa R, Blumenthal E (2017) Immunomodulatory effects of turmeric: Proliferation of spleen cells in mice. *Journal of Immunoassay and Immunochemistry*. 38 (2): 140-146. doi: 10.1080/15321819.2016.1227835
20. Smith JR, Bolton ER, Dwinell MR (2019) The rat: A model used in biomedical research. *Methods in Molecular Biology*. 2018: 1-41. doi: 10.1007/978-1-4939-9581-3_1
21. Tarasub N, Tarasub C, Ayutthaya WDN (2010) Histological changes of spleen, stomach and small intestine induced by cadmium in rats and the protective effect of curcumin. 9 (3): ID: sea-132741.

22. Stopa LRS, de Souza CF, Santos GF, Martins AB, Ferreira RN, de Andrade FG, Leite CM, Zaia DAM, Zaia CTBV, Uchoa ET (2019) Sex differences in glucocorticoids-induced anabolic effects in rats. *Physiology and Behavior*. 209: 112587. doi: 10.1016/j.physbeh.2019
23. Mitevska E, Kostadinova Petrova I, Kostovska N (2015) Changes of spleen in Wistar rats exposed to therapeutic doses of dexamethasone and medroxyprogesterone acetate evaluated by stereological parameters. *Prilozi*. 36 (3): 13-25. doi: 10.1515/prilozi-2015-0074
24. Samtani MN, Jusko WJ (2005) Comparison of dexamethasone pharmacokinetics in female rats after intravenous and intramuscular administration. *Biopharmaceutics and Drug Disposition*. 26 (3): 85-91. doi: 10.1002/bdd.435
25. Na LX, Zhang YL, Li Y, Liu LY, Li R, Kong T, Sun S-H (2011) Curcumin improves insulin resistance in skeletal muscle of rats. *Nutrition, Metabolism, and Cardiovascular Diseases: NMCD*. 21 (7): 526-533. doi: 10.1016/j.numecd.2009.11.009.
26. Wang L, Li W, Cheng D, Guo Y, Wu R, Yin R, Li S, Kuo HC, Hudlikar R, Yang H, Buckley B, Kong AN (2020) Pharmacokinetics and pharmacodynamics of three oral formulations of curcumin in rats. *Journal of Pharmacokinetics and Pharmacodynamics*. 47 (2):131-144. doi: 10.1007/s10928-020-09675-3
27. Mandarim-de-Lacerda CA (2003) Stereological tools in biomedical research. *Anais da Academia Brasileira de Ciências*. 75 (4): 469-486. doi: 10.1590/s0001-37652003000400006
28. Gundersen HJG, Bendtsen TF, Korbo L, Marcussen N, Møller A, Nielsen K, Nyengaard JR, Pakkenberg B, Sørensen FB, Vesterby A (1988) Some new, simple and efficient stereological methods and their use in pathological research and diagnosis. *APMIS: Acts Pathologica, microbiologica, et immunologica Scandinavica*. 96 (5): 379-394. doi: 10.1111/j.1699-0463.1988.tb05320.x
29. Ibrahim A, Saleh R, Hassan A, Amer M (2020) Ameliorative effect of *Echinacea purpurea* and curcumin on dexamethasone-induced immunosuppressive rabbits. *Kafrelsheikh Veterinary Medical Journal*. 18 (1): 10-16. doi: 10.21608/KVMJ.2020.109085
30. Rungruang T, Chaweeborisuit P, Klosek SK (2010) Effect of malaria infection and dexamethasone on spleen morphology and histology. *The Southeast Asian Journal of Tropical Medicine and Public Health*. 41: 1290-1296. PMID: 21329300.
31. McKay LI, Cidlowski JA (2003) Physiologic and pharmacologic effects of corticosteroids. In: *Holland-Frei Cancer Medicine 6th ed.*, [Internet]. Bookshelf ID: NBK13780.
32. Chen L, Jondal M, Yakimchuk K (2018) Regulatory effects of dexamethasone on NK and T cell immunity. *Inflammopharmacology*. 26 (5): 1331-1338. doi: 10.1007/s10787-017-0418-0
33. Smyth T, Töttemeyer S, Haugland S, Willers C, Peters S, Maskell D, Bryant C (2008) Dexamethasone modulates *Salmonella enterica* serovar *Typhimurium* infection in vivo independently of the glucocorticoid-inducible protein annexin-A1. *FEMS Immunology & Medical Microbiology*. 54 (3): 339-348. doi: 10.1111/j.1574-695X.2008.00485.x
34. Den Hartogh DJ, Gabriel A, Tsiani E (2020) Antidiabetic properties of curcumin II: Evidence from in vivo studies. *Nutrients*. 12 (1): 58. doi: 10.3390/nu12010058
35. Zhu Y, Bu S (2017) Curcumin induces autophagy, apoptosis, and cell cycle arrest in human pancreatic cancer cells. *Evidence Based-Complementary and Alternative Medicine*. 2017: 5787218. doi: 10.1155/2017/5787218
36. Swildens KX, Sillevs Smitt PAE, van den Bent MJ, French PJ, Geurts M (2022) The effect of dexamethasone on the microenvironment and efficacy of checkpoint inhibitors in glioblastoma: A systematic review. *Neuro-Oncology Advances*. 4 (1): vdac087. doi: 10.1093/oaajnl/vdac087

Author contribution: All authors conceived and designed the study. GNW & BC collected the data. GNW & IC performed data analysis and interpretation of data. All authors participated to drafting and revising the manuscript for important intellectual context. All the authors approved the final version of the manuscript and agreed to be accountable for its contents.

Conflict of interest: The authors declare the absence of any commercial or financial relationships that could be construed as a potential conflict of interest.

Ethical issues: The authors completely observed ethical issues including plagiarism, informed consent, data fabrication or falsification, and double publication or submission.

Data availability statement: The raw data that support the findings of this article are available from the corresponding author upon reasonable request.

Author declarations: The authors confirm that they have followed all relevant ethical guidelines and obtained any necessary IRB and/or ethics committee approvals.