



CLINICAL IMAGES

Entrapped thrombus in transit

Sandeep Khanna ^{a,*}, Anand Mehta ^b



^a Cleveland Clinic Foundation, Department of Cardiothoracic Anesthesiology, Department of General Anesthesiology and Department of Outcomes Research, Cleveland, Ohio, USA

^b Cleveland Clinic Foundation, Department of Cardiothoracic Anesthesiology, Cleveland, Ohio, USA

Received 25 January 2023; accepted 26 February 2023

Available online 8 March 2023

A thrombus-in-transit, defined as a free-floating clot in the right heart, may be observed in patients experiencing acute pulmonary embolism.^{1,2} The accompanying image exhibits a serpentine thrombus-in-transit entrapped within a patent-foramen-ovale (Fig. 1: Panel A). In addition to the pulmonary vasculature, such a thrombus can potentially embolize systemically, precipitating life-threatening conditions such as stroke and myocardial infarction. Consequently, emergent surgical embolectomy is imperative and necessitates institution of cardiopulmonary bypass. In our patient, a 15-cm snake-like thrombus, that was extending into the left atrium from the right atrium (Fig. 1: Panel B) was extracted intact (Fig. 1: Panel C).

Anesthetic management is challenging, especially when increased pulmonary vascular resistance and tachyarrhythmias related to pulmonary embolism precipitate acute right heart failure and systemic hypotension. Anesthesia induction can further worsen systemic hypotension compromising coronary perfusion and ventricular contractility. This may precipitate hemodynamic collapse necessitating emergent institution of cardiopulmonary bypass, during or shortly after anesthesia induction. Consequently, prior to induction, the surgical team should prepare and drape the patient in readiness to make the incision. However, cannulation of femoral vessels for emergent institution of cardiopulmonary bypass is not recommended as additional thrombi in the inferior vena cava can potentially embolize during manipulation.^{2,3}

* Corresponding author.

E-mail: khannas@ccf.org (S. Khanna).

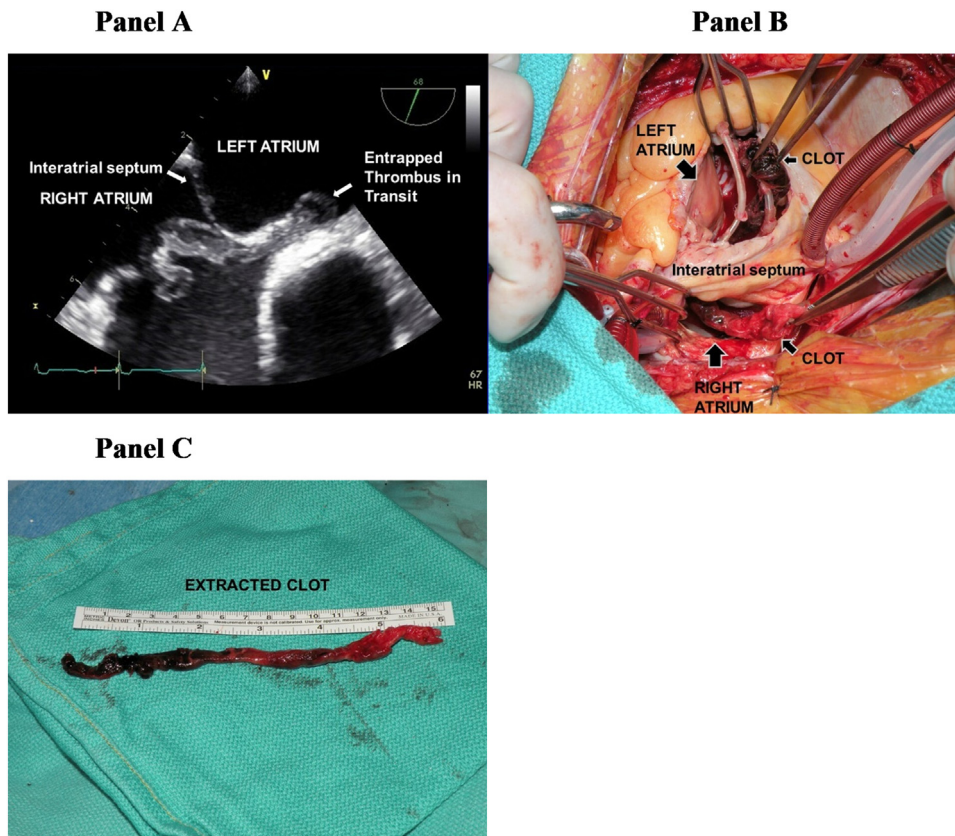


Figure 1 Caption: An entrapped thrombus in transit, visualized with transesophageal echocardiography (Panel A), was found to be extending from the right atrium into the left atrium through a patent-foramen-ovale during surgical exposure (Panel B) and was extracted in its entirety (Panel C).

Conflicts of interest

None.

References

1. Konstantinides SV, Meyer G, Becattini C, et al. The Task Force for the diagnosis and management of acute pulmonary embolism of the European Society of Cardiology (ESC). 2019 ESC Guidelines

for the diagnosis and management of acute pulmonary embolism developed in collaboration with the European Respiratory Society (ERS): The Task Force for the diagnosis and management of acute pulmonary embolism of the European Society of Cardiology (ESC). *Eur Respir J.* 2019;54:1901647.

2. Rosenberg P, Shernan SK, Shekar PS, et al. Acute hemodynamic collapse after induction of general anesthesia for emergent pulmonary embolectomy. *Anesth Analg.* 2006;102:1311–5.
3. Bennett JM, Pretorius M, Ahmad RM, et al. Hemodynamic instability in patients undergoing pulmonary embolectomy: institutional experience. *J Clin Anesth.* 2015;27:207–13.