

## CASE REPORT

# Erector spinae plane blockade in the first stage of labour: a case series

Eylem Yasar \*, Ali Ihsan Uysal

Mugla Sıtkı Kocman University Training and Research Hospital, Anesthesiology and Reanimation Department, Mugla, Turkey

Received 9 December 2020; accepted 18 September 2021

Available online 7 October 2021



### KEYWORDS

Labor pain;  
Analgesia;  
Obstetrical;  
Nerve block

### Abstract

**Introduction:** The objective of this case series was to present the importance of labour analgesia and the preference for erector spinae plane (ESP) block as a new technique that can be used for labour analgesia.

**Case reports:** The three patients were 25-year-old primipara with 5-cm cervical dilation, a 30-year-old multiparous with 5-cm cervical dilatation, and a 32-year-old primipara with 4-cm cervical dilation.

**Conclusions:** Bilateral ESP block may be an alternative analgesic technique for the first stage of labour.

© 2021 Sociedade Brasileira de Anestesiologia. Published by Elsevier Editora Ltda. This is an open access article under the CC BY-NC-ND license (<http://creativecommons.org/licenses/by-nc-nd/4.0/>).

## Introduction

Labour pains are regarded as the most memorable and, often, painful and longest events in a woman's life. Continuous epidural analgesia is a method frequently preferred for vaginal and cesarean deliveries. However, coagulopathy, increased intracranial pressure, anatomical abnormality, infection at the puncture site and patient site, and refusal are contraindications to epidural analgesia.<sup>1</sup>

Erector spinae plane (ESP) block has been used in hysterectomy and abdominal surgery because it is a fast procedure with a low risk of hypotension, can be used in patients with coagulopathy, is easy to perform, and requires less training.<sup>2</sup> The advantages of an ESP block are the observation of target tissues under ultrasound guidance, the injection site being away from the pleura and large vascular structures, and the craniocaudal spread of the local anaesthetic.

For this study, the duration of stage I labour was considered to be the interval from the beginning of labour to complete cervical dilatation. The transition phase was the interval from complete cervical dilatation to the presence of the maternal urge to push, which can be defined as the

\* Corresponding author.

E-mail: [eylemtarakci@gmail.com](mailto:eylemtarakci@gmail.com) (E. Yasar).

period in which labour pain is the longest and most severe. Stage II labour was considered to extend from the end of the transition phase to delivery.

In this case series, we aimed to evaluate ESP block as an alternative to epidural analgesia for labour analgesia.

## Case reports

ESP block was recommended as an alternative to three selected patients scheduled for vaginal delivery and graded according to the American Society of Anesthesiologists (ASA) physical status I or II, who wanted analgesia for labour but did not want epidural analgesia for various reasons. Patient consent was obtained for both the ESP block and publication of the study. After standard monitoring, including electrocardiography and non-invasive blood pressure measurement, was performed in the operating room, the patients were placed in a sitting position.

### Patient 1

A 25-year-old gravida 1, para 0 woman at 39 weeks and 7 days gestation at 5-cm cervical dilatation and a pain score of 4/10 on an 11-point numerical rating scale (NRS). The NRS ranges from "0" (no pain) to "10" (the worst pain imaginable). Her pain regressed to NRS 1/10 30 minutes after local anesthetic injection. The first phase of labour was completed in 5 hours, and the termination of labour was completed in 6 hours in total.

### Patient 2

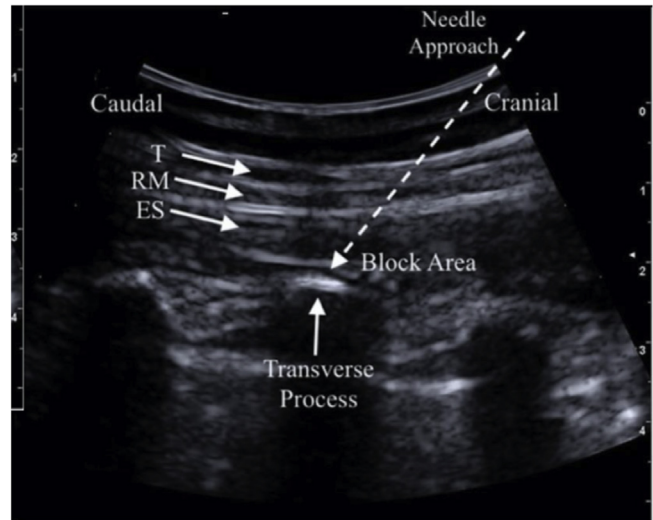
A 30-year-old gravida 3, para 2 woman at 38 weeks and 5 days gestation at 5-cm cervical dilatation and a NRS pain score of 4/10. Her pain regressed to NRS 2/10 minutes after local anesthetic injection. The first phase of labour was completed in 4 hours, and the termination of labour was completed in 5 hours in total.

### Patient 3

A 32-year-old ASA I, gravida 1, para 0 woman at 39 weeks and 5 days gestation at 4-cm cervical dilatation and a pain score 6/10 on the NRS. Her pain regressed to NRS 1/10 30 minutes after local anaesthetic injection. The first phase of labour was completed in 7 hours, and the termination of labour was completed in 8 hours in total.

## Ultrasound-guided nerve blocks

At the level of the eleventh thoracic transverse process, a linear 6–13 MHz ultrasound probe (SonoSite MTurbo; FUJIFILM SonoSite, Bothell, WA) was placed vertically 3 cm lateral to the spinous process to visualise the trapezius and erector spinae muscles. A 100-mm block needle (Stimuplex D; Braun Medical, Melsungen, Germany) was inserted in the craniocaudal direction using the in-plane method until it contacted the transverse process (Fig. 1). The correct location of the needle tip in the fascial plane deep in the erector spinae muscle was confirmed by injecting



**Figure 1** T11 transverse process and overlying erector spinae muscle.

T, trapezius; RM, rhomboid major; ES, erector spinae.

0.5–1 mL of saline to visualise the lifting of the erector spinae muscle off the transverse process without distending the muscle. In all three patients, 10 mL 0.25% bupivacaine, a total of 20 mL, was injected into the ESP after aspiration to exclude vascular puncture, and a 20G epidural catheter was then advanced through the needle. The same procedure was repeated on the other side. The sensory block area was controlled by a cold test, and the pain was assessed using the NRS. The first NRS pain assessment was made 20–30 min after the ESP block. Heart rate, blood pressure, NRS, and motor block were followed up every 30 min until labour was terminated. After birth, the patient was followed up for 24 hours by the delivery service.

In all three patients, 0.25% 5 mL bupivacaine was administered bilaterally, totalling 10 mL, due to the need for additional analgesic in stage II labour. However, there was no improvement in the patient's pain scores. The patients tolerated the initiation of the blocks well, remained hemodynamically stable, and did not suffer any adverse effects during stage I labour.

Pain decreased in the first stage of labor in all 3 patients (NRS was 1 in 2 patients and NRS 2 in 1 patient). After ESP, NRS 1 was detected in two patients and NRS 2 in one patient. However, tachycardia and hypertension developed in all three patients in the second stage of labor, and the NRS increased to 7–8/10.

## Discussion

In this case series, we found a significant decrease in NRS scores in the first stage of delivery in pregnant women who underwent an ESP block for labour analgesia. To date, there have been no published studies or case reports about the effectiveness of ESP for labour analgesia.

Continuous epidural analgesia is often preferred for both birth and anaesthesia in instrumental deliveries and cesarean deliveries as it has been shown to have the most effective and best risk/benefit ratio in obstetrics. However,

clinical contraindications (i.e., coagulopathy, increased intracranial pressure, anatomical abnormality, and infection) and personnel/institutional limitations preclude some patients from receiving an epidural.

The ESP block represents a more straightforward, safer alternative to epidural analgesia because the ultrasonic target is easily visualised; the injection point is far from the neuroaxis, pleura, and large vascular structures; and wide cranio-caudal diffusion of the anesthetic allows extensive coverage with a single injection.

The pain of labour, caused by uterine contractions and cervical dilatation, is transmitted through visceral afferent (sympathetic) nerves entering the spinal cord from T10 through L1. Later in labour, perineal stretching transmits painful stimuli through the pudendal and sacral nerves, S2 through S4. Nair and Henry<sup>3</sup> reported that for four pregnant women, the pain was decreased in the first stage of labour after applying a paravertebral block from the T11 superior and T12 inferior nerve roots, and the patients experienced a comfortable birth. Likewise, Toshiyoki et al.<sup>4</sup> reported that they applied a paravertebral block for labour from the 11th thoracic vertebra, which provided sufficient analgesia for labour. Based on these publications, we thought that the blockade we made at the T11 level might have a sacral spread. Schwartzmann et al.<sup>5</sup> reported that MRI images suggested that the ESP-block mechanism of action is likely linked to transforaminal and epidural spread. In a brief report, Adhikary et al.<sup>6</sup> reported that single-injection retrolaminar and ESP blocks in fresh cadavers produced both epidural and neural foraminal spread across several levels.

Ropivacaine and bupivacaine are the most common local anaesthetic options for lumbar ESP blocks and are usually used at a concentration of either 0.375% or 0.25%. To avoid local anesthetic toxicity in our patients, we applied 10 ml of 0.25% bupivacaine for a total of 20 ml on both sides. With the area block catheter we placed at the beginning of the second phase of labour, we added an equal amount of bilateral 0.25% 5 mL bupivacaine to all patients at the beginning of the second phase. According to our results, there was no decrease in NRS scores in the second phase of labour.

We could have added a pudendal block to the ESP block during stage II labour, but it can be difficult to position patients during delivery, and we wanted to avoid additional interventions. Since our patients were pregnant, we preferred to undertake the procedure with them in a sitting position to avoid uterine pressure. The limitations of this case series were that we had to pause urination during contractions due to cervical dilatation and the difficulty in positioning the patients due to the procedure.

## Conclusion

A bilateral ESP block provides adequate analgesia for stage I labour and could be an alternative analgesic technique for some patients with contraindications to conventional labour epidurals.

## Conflicts of interest

The authors declare no conflicts of interest.

## References

1. Chau A, Tsen LC. Update on modalities and techniques for labor epidural analgesia and anesthesia. *Adv Anesth.* 2018;36:139–62.
2. Forero M, Adhikary SD, Lopez H, et al. The erector spinae plane block: a novel analgesic technique in thoracic neuropathic pain. *Reg Anesth Pain Med.* 2016;41:621–7.
3. Nair V, Henry R. Bilateral paravertebral block: a satisfactory alternative for labour analgesia. *Can J Anaesth.* 2001;48:179–84.
4. Okutomi T, Taguchi M, Amano K, et al. Paravertebral block for labor analgesia in a parturient with idiopathic thrombocytopenia. *Masui.* 2002;51:1123–6.
5. Schwartzmann A, Peng P, Maciel MA, et al. Mechanism of the erector spinae plane block: insights from a magnetic resonance imaging study. *Can J Anaesth.* 2018;65:1165–6.
6. Adhikary SD, Bernard S, Lopez H, et al. Erector spinae plane block versus retrolaminar block: a magnetic resonance imaging and anatomical study. *Reg Anesth Pain Med.* 2018;43:756–62.