

The use of QLB in the supine position can be an efficient option in postoperative pain management in acetabular fractures. The block does not require the repositioning of the patient. In literature lumbar plexus block was reported to be effective in acetabular fracture pain management, since the primary innervation of the acetabular region originates from the lumbar plexus.<sup>4</sup> As QLB is a fascial plane block, unlike the lumbar plexus block, it is not directly applied to the nerve site; therefore, the risk of intraneural injection is lower.

We found an opportunity to perform SCAQLB in three patients. We can say that SCAQLB is easy to perform and has some advantageous for visualization of quadratus lumborum muscle than Blanco et al methodology.<sup>2</sup> Further studies on fresh cadavers may reveal the effectiveness of SCAQLB.


### Conflicts of interest

The authors declare no conflicts of interest.

### References

1. Diwan S, Blanco R, Kulkarni M, et al. The supine coronal midaxillary approach to anterior quadratus lumborum block: case report. *Braz J Anesthesiol.* 2020;70:443–7.
2. Blanco R, Ansari T, Girgis E. Quadratus lumborum block for postoperative pain after caesarean section: A randomised controlled trial. *Eur J Anaesthesiol.* 2015;32:812–8.

3. Uysal Alihsan, Yörük Mustafa Deniz, Altıparmak Başak, et al. <https://www.tard.org.tr/akademi/bildiri/?kID=9927&sec1=&session=13312885095394-26625770190788>, 2019.
4. Chelly JE, Casati A, Al-Samsam T, et al. Continuous lumbar plexus block for acute postoperative pain management after open reduction and internal fixation of acetabular fractures. *J Orthop Trauma.* 2003;17:362–7.

Ali İhsan Uysal <sup>a,\*</sup>, Mustafa Deniz Yörük<sup>b</sup>, Başak Altıparmak<sup>c</sup>, Melike Korkmaz Toker<sup>a</sup>, Cem Yalın Kılıncı<sup>d</sup>, Semra Demirebilek<sup>c</sup>

<sup>a</sup> Muğla Sıtkı Koçman University Training and Research Hospital, Department of Anesthesiology and Reanimation, Muğla, Turkey

<sup>b</sup> Muğla Sıtkı Koçman University, Department of Anatomy, Muğla, Turkey

<sup>c</sup> Muğla Sıtkı Koçman University, Department of Anesthesiology and Reanimation, Muğla, Turkey

<sup>d</sup> Muğla Sıtkı Koçman University, Department of Orthopedics and Traumatology, Muğla, Turkey

\* Corresponding author.

E-mail: [alihsanuysal@gmail.com](mailto:alihsanuysal@gmail.com) (A.İ. Uysal).

Received 16 February 2021; accepted 10 April 2021

<https://doi.org/10.1016/j.bjane.2021.04.017>

0104-0014/ © 2021 Sociedade Brasileira de Anestesiologia.

Published by Elsevier Editora Ltda. This is an open access article under the CC BY-NC-ND license (<http://creativecommons.org/licenses/by-nc-nd/4.0/>).

## The mid-point transverse process to pleura (MTP) block in chest trauma: a game-changer



Dear Editor,

Road traffic accidents have emerged as a pandemic of the modern world. Chest trauma, being commonly associated with these road traffic accidents, becomes the leading cause of morbidity and mortality. Management of pain is essential in these trauma patients as, along with patient comfort, it also decreases patient's respiratory complications.<sup>1</sup> Various techniques are designed to reduce pain-related complications, including pharmacological drug therapies, and regional or neuraxial nerve blocks techniques. Thoracic Epidural Analgesia (TEA) is considered as gold standard for relieving rib fracture pain. However, it is not free of complications, including dural puncture, accidental hypotension, and cardiovascular collapse.<sup>2</sup> Likewise, the thoracic paravertebral block might also lead to inadvertent vascular puncture, hypotension, epidural or intrathecal spread, pleural puncture, and pneumothorax.<sup>3</sup>

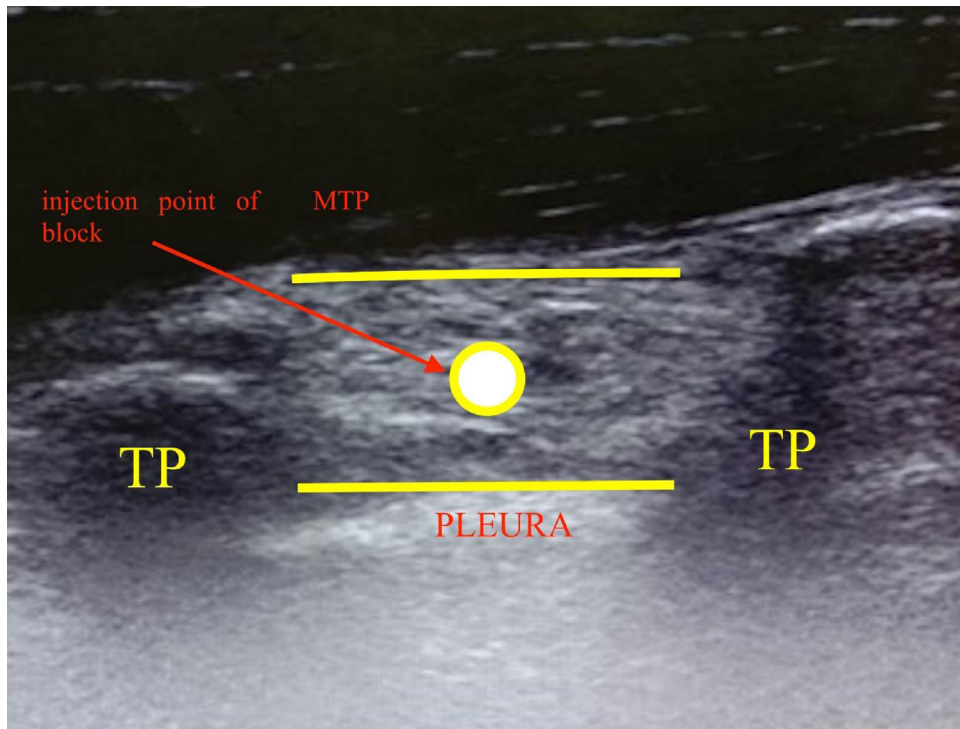
Mid-point transverse process to pleura (MTP) block is a recently described ultrasound-guided novel technique that involves injecting the drug at mid-point between the transverse process and the pleura.<sup>4</sup> In this block, a high frequency (8–15 MHz) linear ultrasound probe is placed

obliquely approximately 3 cm laterally from the midpoint of the spinous process. The block needle (50 mm long) is advanced from caudal to cranial direction of the paravertebral space. When the needle tip reaches the midpoint between the transverse process and the pleura, the drug is given. The drug spreads to the dorsal and ventral rami in the paravertebral space through the fenestrations in the superior costotransverse ligament at the level of injection (Fig. 1).<sup>4</sup> Being a superficial block, landmarks are quickly and easily felt.<sup>5</sup> Thus, it is comparatively easy to insert. It can be easily applied to obese traumatic patients with a compromised position. Due to these advantages, MTP block is much safer than thoracic epidural and thoracic paravertebral blocks by minimizing the risk of pleural puncture and inadvertent intrathecal injections.

Management of acute pain is highly advantageous for enhanced recovery after trauma to prevent the neuroendocrine stress response and thus combat the cascade of events occurring after activation of the sympathetic nervous system and catecholamine release. Therefore, we believe that MTP block can be a game-changer for the chest trauma patients due to an easy approach and reduced risk profile.

### Conflicts of interest


The authors declare no conflicts of interest.



**Figure 1** Depicts the ultrasound image of MTP block. The white circle represents the point of injection of MTP block. TP, transverse process; MTP, mid-point transverse process to pleura.

## References

1. Unsworth A, Curtis K, Asha SE. Treatments for blunt chest trauma and their impact on patient outcomes and health service delivery. *Scand J Trauma Resusc Emerg Med.* 2015;23:17.
2. Freise H, Van Aken HK. Risks and benefits of thoracic epidural anesthesia. *Br J Anaesth.* 2011;107:859–68.
3. Batra RK, Krishnan K, Agarwal A. Paravertebral block. *J Anaesthesiol Clin Pharmacol.* 2011;27:5–11.
4. Eskin MB, Ceylan A, Özhan MÖ, et al. Ultrasound-guided erector spinae block versus mid-transverse process to pleura block for postoperative analgesia in lumbar spinal surgery. *Anaesthesist.* 2020;69:742–50.
5. Syal R, Kumar R, Kamal M, et al. Novel block and new indication: Ultrasound-guided continuous mid-point transverse process to pleura block in a patient with multiple rib fractures. *Saudi J Anaesth.* 2019;13:365–7.

Manbir Kaur \*, Priyanka Sethi, Ravindra Singh, Pradeep Bhatia

*All India Institute of Medical Sciences (AIIMS), Department of Anesthesia and Critical Care, Jodhpur, India*

\*Corresponding author.

*E-mail:* [doctor.manbir@gmail.com](mailto:doctor.manbir@gmail.com) (M. Kaur).

Received 13 February 2021; accepted 14 April 2021

<https://doi.org/10.1016/j.bjane.2021.04.019>

0104-0014/ © 2021 Sociedade Brasileira de Anestesiologia.

Published by Elsevier Editora Ltda. This is an open access article under the CC BY license (<http://creativecommons.org/licenses/by/4.0/>).