

## CLINICAL RESEARCH

## Ultrasound-guided pectoral nerve block for pain control after breast augmentation: a randomized clinical study



Bahadır Ciftci <sup>a,\*</sup>, Mursel Ekinci<sup>a</sup>, Erkan Cem Celik<sup>b</sup>, Pelin Karaaslan<sup>a</sup>, İsmail Cem Tukac<sup>a</sup>

<sup>a</sup> Istanbul Medipol University, Department of Anesthesiology and Reanimation, Istanbul, Turkey

<sup>b</sup> Erzurum Regional Training and Research Hospital, Department of Anesthesiology and Reanimation, Erzurum, Turkey

Received 15 April 2019; accepted 3 October 2020

Available online 25 December 2020

### KEYWORDS

Breast augmentation surgery;  
Regional analgesia;  
Pectoral nerve block type-1

### Abstract

**Background and objective:** Pectoral nNerve (PECS) block type-1 is an Ultrasound (US)-guided interfascial block that can be performed for postoperative analgesia management after breast surgery. In the procedure, a local anesthetic solution is injected into the interfascial area between the Pectoralis Major muscles (PMm) and Pectoralis minor muscles (Pmm). The present study compared PECS block type-1 administered preoperatively or postoperatively for postoperative analgesia after breast augmentation surgery.

**Methods:** The patients were randomly divided into three groups (n = 30 in each): a preoperative PECS block group (Pregroup), postoperative PECS block group (Postgroup), and control group (Group C). Opioid consumption and Visual Analogue Scale (VAS) scores were evaluated at postoperative period.

**Results:** The pain scores in the Pregroup were significantly lower than those in the control group. Although there was no significant difference in the VAS scores of the Postgroup and control group at postoperative 1 hour, the scores in the Postgroup were significantly lower than those in the control group at all the other evaluated times ( $p < 0.05$ ). The VAS scores in the Pregroup were significantly lower than those in the Postgroup 8 hours after the surgery. Opioid consumption was significantly lower in the Pregroup as compared with that in the other two groups ( $p < 0.05$ ). The use of rescue analgesia in the Pregroup was significantly lower than that in the other groups ( $p < 0.05$ ).

**Conclusion:** Performing PECS block type-1 preoperatively reduced VAS scores and opioid consumption after breast augmentation.

© 2020 Sociedade Brasileira de Anestesiologia. Published by Elsevier Editora Ltda. This is an open access article under the CC BY-NC-ND license (<http://creativecommons.org/licenses/by-nc-nd/4.0/>).

\* Corresponding author.

E-mail: [bciftci@medipol.edu.tr](mailto:bciftci@medipol.edu.tr) (B. Ciftci).

## Introduction

Aesthetic breast augmentation is a common procedure in plastic surgery for cosmetic reasons. It may also be performed after breast cancer surgery.<sup>1</sup> Moderate-to-severe pain may occur during the postoperative period due to the insertion of subpectoral prostheses into the breast tissue and surgical dissection of the tissues.<sup>2</sup> Although opioid drugs are generally used for postoperative pain management, Opioid-Related Adverse Events (ORAEs) may occur. These include nausea, vomiting, sedation, itching, urinary retention, and extended hospital stays.<sup>3</sup> Novel techniques have been investigated for reducing ORAEs and providing more effective analgesia.<sup>4</sup>

Pectoral Nerve (PECS) block type-1 may be used for postoperative pain treatment following breast surgery. It is a novel interfascial block, which was first described by Blanco in 2011,<sup>5</sup> and is easy to perform under Ultrasound (US) guidance. In PECS block type-1, the interfascial region between the pectoral muscles (Pectoralis Major [PMm] and Minor [Pmm]) is injected with a local anesthetic. A previous study reported that this block may provide effective postoperative analgesia after subpectoral breast augmentation.<sup>5</sup>

Several studies have addressed postoperative analgesia management following breast augmentation.<sup>6–9</sup> A number of studies have also investigated the efficacy of PECS block for postoperative pain treatment following different types of breast surgery, such as carcinoma, reconstructive, and cosmetic surgeries.<sup>10–14</sup> However, to the best of our knowledge, there is no study that evaluates the timing (preoperatively or postoperatively) of the PECS block in the literature.

The aim of this study was to evaluate the efficacy of PECS block type-1 administered at different times (pre- or postoperative) for postoperative pain management following breast augmentation. The primary outcome was opioid consumption during the first postoperative 24 hours period. The secondary outcomes were pain scores (Visual Analog Scale – VAS), rescue analgesic consumption, and adverse effects.

## Patients and methods

This study included 90 female patients (aged between 18 and 65 years) who were American Society of Anesthesiologists (ASA) status I–II and underwent subpectoral breast augmentation under general anesthesia. Patients who had a history of bleeding diathesis; anticoagulant treatment; skin infections at the procedure region; major cardiac, pulmonary, renal, or liver dysfunction; thoracic abnormalities; or known allergies to local anesthetic drugs and opioid agents were excluded. Lactation or pregnancy and unwillingness to participate were additional exclusion criteria.

Prior to their arrival in the operation room, the patients were randomly divided into the following three groups using a computer program, with 30 patients in each group: a preoperative PECS group (Pregroup), a postoperative PECS group (Postgroup), and a control group (Group C).

This study was approved by the Istanbul Medipol University ethics committee. Written informed consent was obtained from all the patients.

## General anesthesia

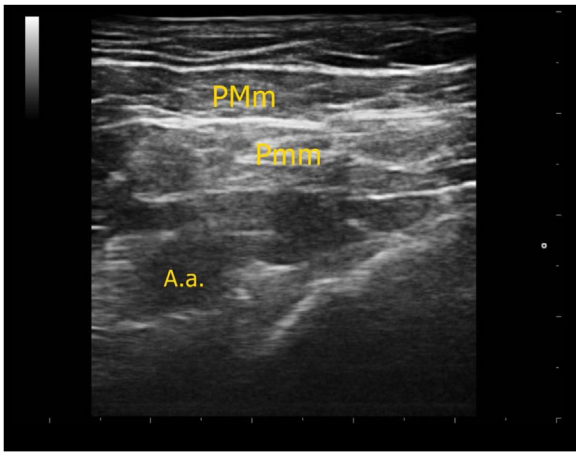
The patients were monitored as normal (electrocardiography, noninvasive blood pressure and peripheral oxygen saturation). A dose of 1–2 mg of midazolam was administered intravenously (IV) for premedication. General anesthesia was induced by the administration of 2–2.5 mg.kg<sup>-1</sup> of propofol, 1–1.5 mcg.kg<sup>-1</sup> of fentanyl, and 0.6 mg.kg<sup>-1</sup> of rocuronium IV, followed by orotracheal intubation. Mechanical ventilation was initiated with a tidal volume of 6–8 mL.kg<sup>-1</sup>, fresh gas flow rate of 2 L.min<sup>-1</sup>, end-tidal CO<sub>2</sub> 30–35 mmHg, and peak airway pressure of 30 cmH<sub>2</sub>O. Anesthesia was maintained using sevoflurane in a mixture of oxygen and fresh air, and a remifentanyl infusion IV (0.25 mcg.kg<sup>-1</sup>.min<sup>-1</sup>) was begun. The patients' heart rates, respiratory rates, peripheral oxygen saturation, non-invasive arterial pressures, and end-tidal CO<sub>2</sub> levels were recorded at 5-minute intervals during the surgery. Additional analgesia intraoperatively was provided with a 0.5 mcg.kg<sup>-1</sup> bolus of remifentanyl and a 50% increase in the concentration of sevoflurane if the patient's heart rate and mean arterial pressure exceeded 20% of the baseline. In all cases, breast augmentation was performed using a subpectoral prosthesis, and the same surgical team performed all the procedures.

A dose of 0.5 mg.kg<sup>-1</sup> of tramadol IV was administered to all the patients 20 minutes before the end of the operation. At the end of the surgery, the neuromuscular blockade was antagonized using atropine (0.01 mg.kg<sup>-1</sup>) and neostigmine (0.02 mg.kg<sup>-1</sup>) administered IV. The patients were extubated after sufficient spontaneous respiration was observed. They were then transferred to the postanesthesia care unit and transferred to the ward when they scored 12 points on the Aldrete scoring system. PECS block was not performed for control group. A 1-g dose of paracetamol was administered routinely every 8 hours in control group and a fentanyl patient-controlled analgesia device was attached to them for 24 hours in the postoperative period.

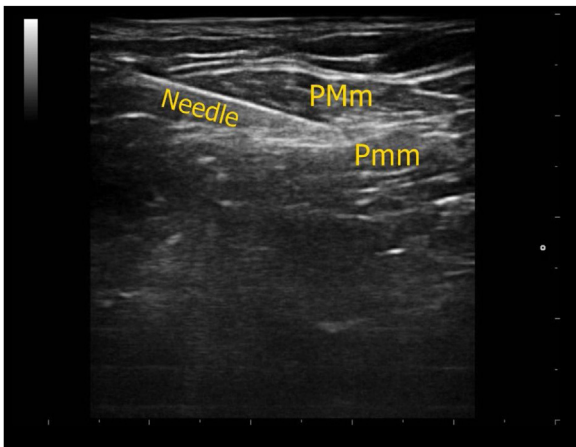
## PECS block procedure

Bilateral US-guided PECS block type-1 was administered to patients in the pre- and post- groups. In the Pregroup, the block procedure was performed following anesthesia induction and intubation before the beginning of the surgery. In the Postgroup, the procedure was performed before extubation.

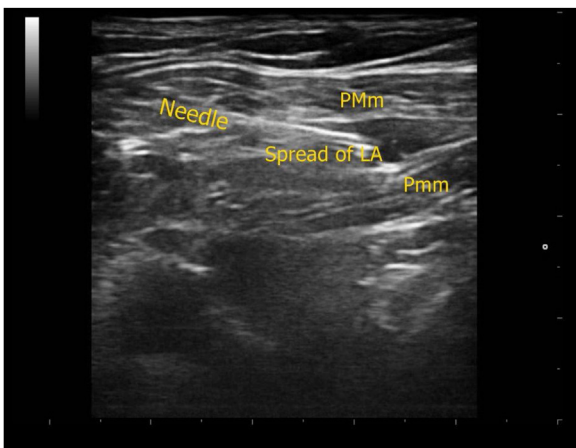
The block procedure was performed under aseptic conditions using a Vivid q US system (GE Healthcare, Wauwatosa, WI, USA). A 12 MHz linear US probe was positioned in the sagittal plane between the terminal end of the clavicle and the acromioclavicular joint in the first costae level. After visualizing the pectoral branch of the thoraco-acromial artery between the PMm and Pmm above the first rib (Fig. 1), a 22-gauge 50-mm block needle (Stimuplex Ultra 360; B. Braun, Melsungen, Germany) was inserted into the interfascial area (Fig. 2).<sup>5</sup> Once the needle tip was placed within the interfascial plane, 2 mL of saline were injected to confirm the injection site. A 0.4 mL.kg<sup>-1</sup> dose of 0.25% bupivacaine was then injected into each surgical site bilaterally (Fig. 3).



**Figure 1** Sonographic anatomy of PECS type-1 block. A.a. indicates axillary artery.



**Figure 2** Ultrasound image of needle direction between the muscles (PMm, Pectoralis major; Pmm, Pectoralis minor muscle).



**Figure 3** Spread of local anesthetic at the plane. LA indicates local anesthetic.

## Postoperative analgesia management

For postoperative analgesia, a 1 g dose of paracetamol was administered routinely every 8 hours. All the patients received fentanyl via a patient-controlled analgesia device using the following protocol: a 1 mL ( $10 \mu\text{g}\cdot\text{mL}^{-1}$ ) bolus without an infusion dose and a 10-minute lockout time. An anesthetist blinded to the study performed the postoperative evaluation using the VAS (0 = no pain, 10 = the most severe pain). The VAS scores (right/left sides) were recorded in the postoperative period (1, 2, 4, 8, 16, and 24 hours).

A dose of  $0.5 \text{ mg}\cdot\text{kg}^{-1}$  of meperidine was administered when the VAS score was  $\geq 4$ . A sedation scale (0 = awake and eyes open, 1 = sleepy but responds to verbal stimulus, 2 = sleepy and hard to wake up, and 3 = sleepy and not aroused by shaking) was used to evaluate the sedation level. Postoperative opioid consumption and side effects (breathing depression, sedation/confusion, nausea, vomiting, and pruritus) were also recorded.

## Statistical analysis

A power analysis was performed according to the total opioid consumption variable. According to the analysis, the effect size was 0.59 at the 95% Confidence Interval, and the power was 0.99 at the significance level.<sup>11,14</sup> Thus, the study sample size was sufficient. IBM SPSS 20.0 software was used to analyze the statistical data. The data distribution was analyzed using the Kolmogorov-Smirnov test. Pearson's chi-square test was used to compare the categorical data between the groups. A one-way analysis of variance was used to check differences among the groups followed by Tukey's tests, at a significance level of 5% for normally distributed continuous variables. Descriptive statistics were expressed as the mean  $\pm$  SD.

## Results

The present study consisted of 90 female patients, with 30 patients in each group. There were no statistically significant intergroup differences with respect to the demographic data ( $p > 0.05$  for each groups) (Table 1). The results are shown in a Consolidated Standards of Reporting Trials flow diagram (Fig. 4).

The VAS scores (right/left sites) 1, 2, 4, 8, 16, and 24 h postoperatively were significantly lower in the Pregroup than in the control group. The VAS scores in the Pregroup were significantly lower than those in the Postgroup 1, 2, 4, and 8 hours postoperatively. There was no significant difference in the VAS scores in the Postgroup versus those in the control group in the postoperative first hour. However, the VAS scores 2, 4, 8, 16, and 24 hours postoperatively in the Postgroup were significantly lower than those in the control group ( $p < 0.05$ ) (Table 2).

Opioid consumption 1, 2, 4, 8, 16, and 24 hours postoperatively was significantly lower in the Pregroup as compared with that in the other groups ( $p < 0.05$ ) (Table 3). Rescue analgesic use in the Pregroup was also lower than that in the other groups ( $p < 0.05$ ) (Table 3).

Other than the incidence of vomiting, which was higher in the control group as compared with that in the other

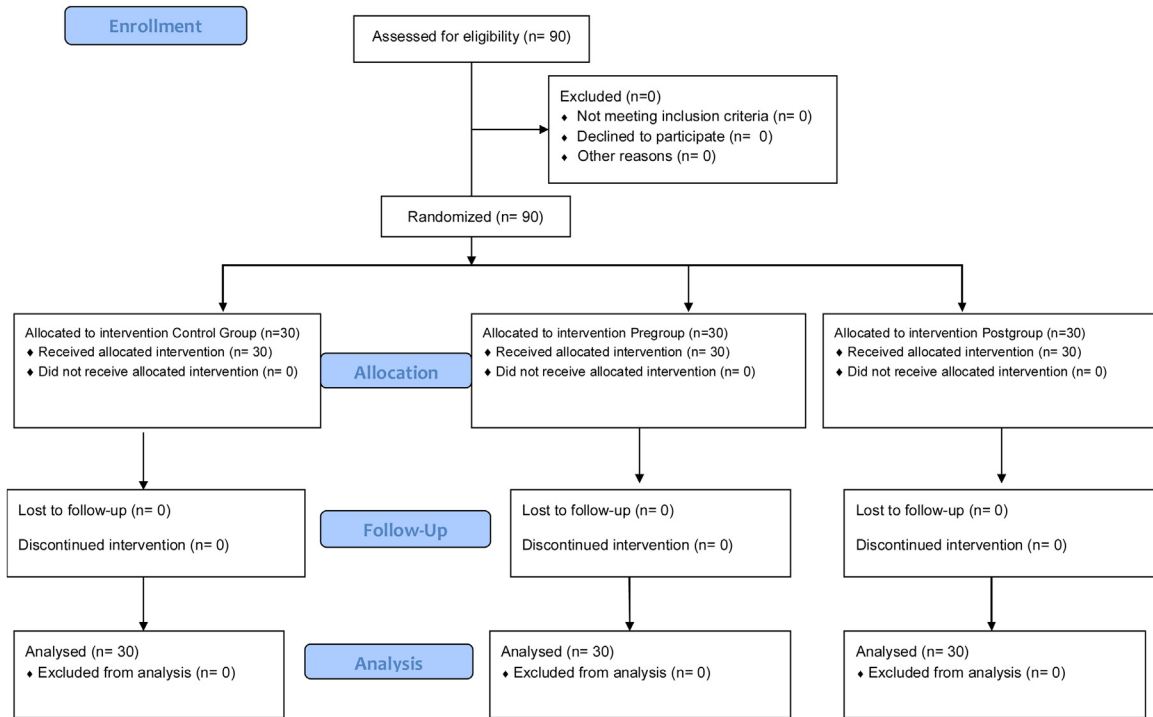
**Table 1** Demographic data and comparison of operative procedures between Group C, Pregroup and Postgroup.

|                                    | Group C<br>(n = 30) | Pregroup<br>(n = 30) | Postgroup<br>(n = 30) | p                  |
|------------------------------------|---------------------|----------------------|-----------------------|--------------------|
| Age (years)                        | 39.10 ± 7.26        | 35.60 ± 10.43        | 38.70 ± 7.51          | 0.226a             |
| Weight (kg)                        | 74.30 ± 8.49        | 70.43 ± 10.30        | 74.13 ± 8.61          | 0.188a             |
| Height (cm)                        | 163.20 ± 6.94       | 163.27 ± 5.43        | 163.30 ± 6.93         | 0.998a             |
| ASA (I/II)                         | 21/9                | 26/4                 | 20/10                 | 0.164 <sup>b</sup> |
| Operation (reduction/augmentation) | 18/12               | 13/17                | 20/10                 | 0.171 <sup>b</sup> |

Values are expressed mean ± standard deviation or number. Kg, kilogram; cm, centimeter; ASA, American Society of Anesthesiologists.

<sup>a</sup>  $p > 0.05$  One-Way ANOVA between groups.

<sup>b</sup>  $p > 0.05$  Chi-square test between groups.

**Figure 4** CONSORT flow diagram of the study.**Table 2** Comparison of VAS values between Group C, Pregroup and Postgroup.

|                                 | Group C<br>(n = 30) | Pregroup<br>(n = 30)       | Postgroup<br>(n = 30)    | p       |
|---------------------------------|---------------------|----------------------------|--------------------------|---------|
| VAS right 1 <sup>st</sup> hour  | 5.73 ± 1.50         | 3.27 ± 1.31 <sup>a,b</sup> | 5.50 ± 1.61              | < 0.001 |
| VAS right 2 <sup>nd</sup> hour  | 5.50 ± 1.19         | 2.47 ± 1.30 <sup>a,b</sup> | 4.03 ± 1.65 <sup>a</sup> | < 0.001 |
| VAS right 4 <sup>th</sup> hour  | 5.03 ± 1.12         | 2.00 ± 1.17 <sup>a,c</sup> | 3.17 ± 1.28 <sup>a</sup> | < 0.001 |
| VAS right 8 <sup>th</sup> hour  | 4.63 ± 0.99         | 1.57 ± 1.07 <sup>a,b</sup> | 3.03 ± 0.99 <sup>a</sup> | < 0.001 |
| VAS right 16 <sup>th</sup> hour | 3.87 ± 0.97         | 1.47 ± 1.07 <sup>a</sup>   | 1.77 ± 1.33 <sup>a</sup> | < 0.001 |
| VAS right 24 <sup>th</sup> hour | 3.27 ± 0.82         | 0.97 ± 0.76 <sup>a</sup>   | 1.33 ± 1.06 <sup>a</sup> | < 0.001 |
| VAS left 1 <sup>st</sup> hour   | 5.73 ± 1.50         | 3.53 ± 1.30 <sup>a,b</sup> | 5.63 ± 1.71              | < 0.001 |
| VAS left 2 <sup>nd</sup> hour   | 5.47 ± 1.16         | 2.70 ± 1.23 <sup>a,c</sup> | 3.93 ± 1.55 <sup>a</sup> | < 0.001 |
| VAS left 4 <sup>th</sup> hour   | 5.07 ± 0.98         | 1.90 ± 1.12 <sup>a,c</sup> | 2.83 ± 1.59 <sup>a</sup> | < 0.001 |
| VAS left 8 <sup>th</sup> hour   | 4.63 ± 0.99         | 1.47 ± 1.04 <sup>a,c</sup> | 2.23 ± 1.43 <sup>a</sup> | < 0.001 |
| VAS left 16 <sup>th</sup> hour  | 3.87 ± 0.97         | 1.27 ± 1.04 <sup>a</sup>   | 1.77 ± 1.30 <sup>a</sup> | < 0.001 |
| VAS left 24 <sup>th</sup> hour  | 3.27 ± 0.82         | 0.90 ± 0.80 <sup>a</sup>   | 1.20 ± 0.96 <sup>a</sup> | < 0.001 |

Values are expressed mean ± standard deviation. VAS, Visual Analog Pain Scale.

<sup>a</sup>  $p < 0.001$  One Way ANOVA compared with Group C.

<sup>b</sup>  $p < 0.001$  One Way ANOVA compared with Postgroup.

<sup>c</sup>  $p < 0.05$  One Way ANOVA compared with Postgroup.



**Table 3** Comparison of opioid consumption and rescue analgesia between Group C, Pregroup and Postgroup.

|                        | Group C<br>(n = 30) | Pregroup<br>(n = 30)          | Postgroup<br>(n = 30)       | p       |
|------------------------|---------------------|-------------------------------|-----------------------------|---------|
| 1 <sup>st</sup> hour   | 108.66 ± 30.48      | 46.66 ± 22.48 <sup>α,β</sup>  | 64.00 ± 21.27 <sup>α</sup>  | < 0.001 |
| 2 <sup>st</sup> hour   | 148.66 ± 31.81      | 70.33 ± 32.00 <sup>α,β</sup>  | 108.00 ± 31.77 <sup>α</sup> | < 0.001 |
| 4 <sup>st</sup> hour   | 174.00 ± 36.44      | 97.66 ± 51.03 <sup>α,δ</sup>  | 146.66 ± 43.41 <sup>γ</sup> | < 0.001 |
| 8 <sup>st</sup> hour   | 207.33 ± 39.82      | 117.66 ± 61.90 <sup>α,δ</sup> | 180.66 ± 62.25              | < 0.001 |
| 16 <sup>st</sup> hour  | 231.33 ± 43.21      | 137.66 ± 74.91 <sup>α,δ</sup> | 211.33 ± 76.05              | < 0.001 |
| 24 <sup>st</sup> hour  | 265.33 ± 44.85      | 153.00 ± 93.03 <sup>α,δ</sup> | 236.00 ± 91.18              | < 0.001 |
| Rescue analgesia (Y/N) | 30/0                | 16/14 <sup>a,b</sup>          | 25/5 a <sup>a</sup>         | < 0.001 |

Values are expressed mean ± standard deviation or numbers.

<sup>α</sup> p < 0.001 One Way ANOVA compared with Group C.

<sup>β</sup> p < 0.05 One Way ANOVA compared with Postgroup.

<sup>γ</sup> p < 0.05 One Way ANOVA compared with Group C.

<sup>δ</sup> p < 0.001 One Way ANOVA compared with Postgroup.

<sup>a</sup> p < 0.05 Chi-square test compared with Group C.

<sup>b</sup> p < 0.05 Chi-square test compared with group Postgroup.

**Table 4** Comparison of incidence of side effects between Group C, Pregroup and Postgroup.

|                      | Group C<br>(n = 30) | Pregroup<br>(n = 30) | Postgroup<br>(n = 30) | p                  |
|----------------------|---------------------|----------------------|-----------------------|--------------------|
| Breathing depression | 0                   | 0                    | 0                     | 1.000 <sup>a</sup> |
| Sedation/ Confusion  | 0                   | 0                    | 0                     | 1.000 <sup>a</sup> |
| Nausea (Y/N)         | 9                   | 3                    | 8                     | 0.136 <sup>a</sup> |
| Vomiting (Y/N)       | 14                  | 3 <sup>b</sup>       | 7 <sup>b</sup>        | 0.005              |
| Pruritis             | 2                   | 1                    | 2                     | 0.809 <sup>a</sup> |

Values are expressed as a number. Y, Yes; N, No.

<sup>a</sup> p > 0.05 Chi-square test between groups.

<sup>b</sup> p < 0.05 Chi-square test compared with Group C.

groups, there were no differences in adverse effects among the groups (Table 4).

## Discussion

This study showed that PECS block type-1 administered preoperatively decreased VAS scores and opioid consumption following breast augmentation surgery. Administering the block postoperatively resulted in higher VAS scores in the first hour in the postoperative period.

Various techniques, such as intravenous analgesics, thoracic epidural analgesia, thoracic paravertebral block, intercostal blockade, and PECS blocks, may be used for postoperative pain treatment following breast augmentation surgery.<sup>6–9,14</sup> PECS block type-1 is commonly used under US guidance because it is a superficial block, easy to administer, and has relatively low complication rates. The mechanism of action of PECS block type-1 is related to the neural anatomy of the chest wall, which contains three groups of nerves.<sup>10</sup> The medial pectoral and lateral pectoral nerves form the first group. Medial pectoral nerve rises from the medial cord of the brachial plexus and is composed of (C8–T1) and lateral pectoral nerve rises from the lateral cord of the brachial plexus and is composed of (C5–C7). The medial pectoral nerves are localized under the Pmm, and the lateral pectoral nerves are located between the PMm and Pmm. These nerves innervate the Pmm and Pmm. The spinal nerves (T2–6) form the second

group. These are localized between the intercostal muscles and support the chest wall via lateral and anterior branches. The final group contains the serratus anterior muscle. The latter is innervated by the long thoracic nerve (C5–7), and the latissimus dorsi muscle is innervated by the thoracodorsal nerve. PECS block type-1 targets the first neuronal group.<sup>5</sup> In breast augmentation surgery, dissection of the PMm and Pmm to facilitate the placement of the subpectoral prosthesis may give rise to postoperative pain.

Although opioids are commonly preferred for acute pain management, ORAEs are a problem. Another disadvantage of opioids is that they do not block the inflammatory process.<sup>15,16</sup> Thus, other analgesic methods, such as multimodal or regional anesthesia, are used for pain management with opioids. The aim of Multimodal Analgesia (MA) treatment is to provide effective analgesia and reduce the incidence of ORAEs based on the additive or synergistic effects between different analgesics.<sup>17</sup> Regional anesthesia techniques can be used in conjunction with MA to decrease ORAEs. A number of previous studies pointed to the success of PECS block for pain management after breast augmentation surgery.<sup>12,14</sup> According to our results, PECS block type-1 may be used effectively as part of MA following breast augmentation surgery.

According to previous research, PECS block did not affect postoperative nausea and vomiting rates.<sup>12,13</sup> In the present study, the incidence of vomiting was lower in the PECS block groups as compared with that in the control group due to the

reduced use opioids. Cros et al. reported that PECS block type-1 did not provide analgesia.<sup>18</sup> However, in their study, axillary lymph node dissection was performed during the surgery, in addition to a mastectomy. Due to the neuronal supply of the chest wall,<sup>10</sup> performing PECS block type-1 may not provide analgesia following axillary dissection.<sup>5</sup> The results of the present study support the idea that PECS block type-1 is an ideal analgesic technique following breast augmentation.

The aim of preemptive analgesia is to treat pain before the beginning of a painful stimulus.<sup>19</sup> Preemptive analgesia is administered before tissue damage to prevent peripheral and central sensitization mechanisms.<sup>20</sup> If pain transmission is blocked before a surgical incision, postoperative hyperalgesia can be prevented.<sup>21</sup> In the present study, PECS block type-1 was performed preoperatively and postoperatively to determine the optimum timing of the nerve block. According to our results, opioid consumption, and pain scores in the group in which the block was performed preoperatively were lower than those in the Postgroup. Furthermore, the VAS scores in the preoperative nerve block administration group were lower than those in the postop group 8 hours after surgery. These results support the hypothesis that decreasing the number of stimuli reaching the central nervous system from the nociceptors via the administration of local anesthetic agents preoperatively prevents the development of pain.<sup>21</sup> On the other hand, 1 hour after surgery, the VAS scores in the group in which the nerve block was administered postoperatively were higher than those in the group in which it was administered preoperatively. A sufficient time interval is required for local anesthetics to start acting.<sup>21</sup> Reduced pain scores in the early hours after surgery enable earlier mobilization and ameliorate patient anxiety due to pain.

This study has some limitations. First, pain was evaluated only during the first 24 hours after surgery, and chronic pain, which may have long-term consequences, was not monitored. Second, the studies involving administered different volumes and doses of local anesthetics may be performed. Third, no sensory testing was performed to demonstrate the block. Further studies are needed.

## Conclusion

In summary, performing PECS block type-1 preoperatively reduced opioid consumption and provided low VAS scores in patients underwent breast augmentation surgery.

The authors report no conflicts of interest. The authors alone are responsible for the content and writing of the paper.

There is no funding for the research.

## Conflicts of interest

The authors declare no conflicts of interest.

## References

- McCarthy Cm, Cano Sj, Klassen Af, et al. The magnitude of effect of cosmetic breast augmentation on patient satisfaction and health-related quality of life. *Plastic and reconstructive surgery*. 2012;130:218–23.
- Von Sperling ML, Høimyr H, Finnerup K, et al. Persistent pain, and sensory changes following cosmetic breast augmentation. *Eur J Pain*. 2011;15:328–32.
- Buenaventura R, Adlaka R, Sehgal N. Opioid complications and side effects. *Pain Physician*. 2008;11:105–20.
- Stanley SS, Hoppe IC, Ciminello FS. Pain control following breast augmentation: a qualitative systematic review. *Aesthetic Surg J*. 2012;32:964–72.
- Blanco R. The 'pecs block': a novel technique for providing analgesia after breast surgery. *Anaesthesia*. 2011;66:847–8.
- Kang CM, Kim WJ, Yoon SH, et al. Postoperative pain control by intercostal nerve block after augmentation mammoplasty. *Aesthet Plast Surg*. 2017;41:1031–6.
- Fayman M, Beeton A, Potgieter E, et al. Comparative analysis of bupivacaine and ropivacaine for infiltration analgesia for bilateral breast surgery. *Aesthetic Plast Surg*. 2003;27:100–3.
- Tan P, Martin MS, Shank N, et al. A comparison of 4 analgesic regimens for acute postoperative pain control in breast augmentation patients. *Annals Plast Surg*. 2017;78 6S suppl 5: S299–304.
- Gardiner S, Rudkin G, Cooter R, et al. Paravertebral blockade for day-case breast augmentation: a randomized clinical trial. *Anesth Analg*. 2012;115:1053–9.
- Wahba SS, Kamal SM. Thoracic paravertebral block versus pectoral nerve block for analgesia after breast surgery. *Egypt J Anaesth*. 2014;30:129–35.
- Kulhari S, Bharti N, Bala I, et al. Efficacy of pectoral nerve block versus thoracic paravertebral block for postoperative analgesia after radical mastectomy: a randomized controlled trial. *Brit J Anaesth*. 2016;117:382–6.
- Bashandy GMN, Abbas DN. Pectoral nerves I and II blocks in multimodal analgesia for breast cancer surgery: a randomized clinical trial. *Reg Anesth Pain Med*. 2015;40:68–74.
- Morioka H, Kamiya Y, Yoshida T, et al. Pectoral nerve block combined with general anesthesia for breast cancer surgery: a retrospective comparison. *JA clinical reports*. 2015;1:15.
- Karaca O, Pınar HU, Arpacı E, et al. The efficacy of ultrasound-guided type-I and type-II pectoral nerve blocks for postoperative analgesia after breast augmentation: A prospective, randomised study. *Anaesth Crit Care Pain Med*. 2019;38:47–52.
- Benyamin R, Trescot AM, Datta S, et al. Opioid complications, and side effects. *Pain Physician*. 2008;11 2 Suppl 1: S105.
- Gago Martinez A, Escontrela Rodriguez B, Planas Roca A, et al. Intravenous ibuprofen for treatment of post-operative pain: a multicenter, double blind, placebo controlled, randomized clinical trial. *PLoS One*. 2016;11:e0154004.
- Buvanendran A, Kroin JS. Multimodal analgesia for controlling acute postoperative pain. *Curr Opin Anaesthesiol*. 2009;22:588–93.
- Cros J, Sengès P, Kaprelian S, et al. Pectoral I block does not improve postoperative analgesia after breast cancer surgery: A randomized, double-blind, dual-centered controlled trial. *Reg Anesth Pain Med*. 2018;43:596–604.
- Lakdja F, Dixmérias F, Bussièrès E, et al. Preemptive analgesia on postmastectomy pain syndrome with ibuprofen-arginine. *Bulletin Du Cancer*. 1997;84:259–63.
- Kelly DJ, Ahmad M, Brull SJ. Preemptive analgesia I: physiological pathways and pharmacological modalities. *Can J Anesth*. 2001;48(10):1000–10.
- Zielinski J, Jaworski R, Smietanska I, et al. A randomized, double-blind, placebo-controlled trial of preemptive analgesia with bupivacaine in patients undergoing mastectomy for carcinoma of the breast. *Med Sci Monit*. 2011;17. CR589-97.