

## CLINICAL RESEARCH

# Airway patency in children undergoing magnetic resonance imaging using neck collars: a single center, randomized, double-blind, prospective study



Gulseren Yilmaz  <sup>a,\*</sup>, Kenan Varol <sup>b</sup>, Osman Esen <sup>c</sup>, Arda Kayhan <sup>b</sup>, Ziya Salihoglu <sup>a</sup>

<sup>a</sup> University of Health Sciences, Faculty of Medicine, Kanuni Sultan Suleyman Hospital, Department of Anesthesiology & Reanimation, Istanbul, Turkey

<sup>b</sup> University of Health Sciences, Faculty of Medicine, Kanuni Sultan Suleyman Hospital, Department of Radiology, Istanbul, Turkey

<sup>c</sup> University of Health Sciences, Faculty of Medicine, Mehmet Akif Ersoy Hospital, Department of Anesthesiology & Reanimation, Istanbul, Turkey

Received 5 February 2019; accepted 18 October 2020

Available online 26 December 2020

### KEYWORDS

Airway;  
Children;  
Magnetic resonance  
imaging;  
Deep sedation

### Abstract

**Background and objectives:** Maneuvers precluding the downward shift of the mandibula and providing slight extension of the head have been shown to increase upper airway dimensions. This study aimed to investigate the role of Neck Collars (NC) in maintaining airway patency during Magnetic Resonance Imaging (MRI) examination in a pediatric population aged between 0 and 16 years.

**Methods:** One hundred twenty-five children were recruited in this prospective study. Subjects were randomly assigned to NC group (NC+) or standard imaging group (NC-). Measurements of anteroposterior and transverse dimensions and cross-sectional area were performed to determine the upper airway size at three distinct levels: soft palate, base of the tongue, and tip of the epiglottis.

**Results:** The anteroposterior diameter and cross-sectional area at the levels of base of the tongue and soft palate were significantly higher in NC+ patients compared to NC- patients. However, anteroposterior dimensions and cross-sectional areas at the epiglottis level were similar in the two groups. When patients were analyzed according to age groups of 0–2, 2–8, and 8–16 years, the anteroposterior diameter and cross-sectional area at the levels of base of the tongue and soft palate were significantly higher in NC+ patients compared to NC- patients in all age groups.

**Conclusions:** This study clearly demonstrates that the application of a NC may improve retropalatal end and retroglottal airway dimensions in a pediatric population undergoing MRI examination and receiving sedation in supine position.

© 2020 Published by Elsevier Editora Ltda. on behalf of Sociedade Brasileira de Anestesiologia. This is an open access article under the CC BY-NC-ND license (<http://creativecommons.org/licenses/by-nc-nd/4.0/>).

\* Corresponding author.

E-mail: [drgulseren83@gmail.com](mailto:drgulseren83@gmail.com) (G. Yilmaz).

## Introduction

Deep sedation is essential to favorably execute Magnetic Resonance Imaging (MRI) examinations in children. Degradation in image quality caused by the motion warrants a high degree of sedation in this unique population.<sup>1</sup> Evidence of airway obstruction during MRI examination has been demonstrated in a significant proportion of spontaneously breathing neonates and infants.<sup>2</sup> Moreover, agents used for sedation of children might impend airway patency and seldom lead to total airway obstruction.<sup>3</sup>

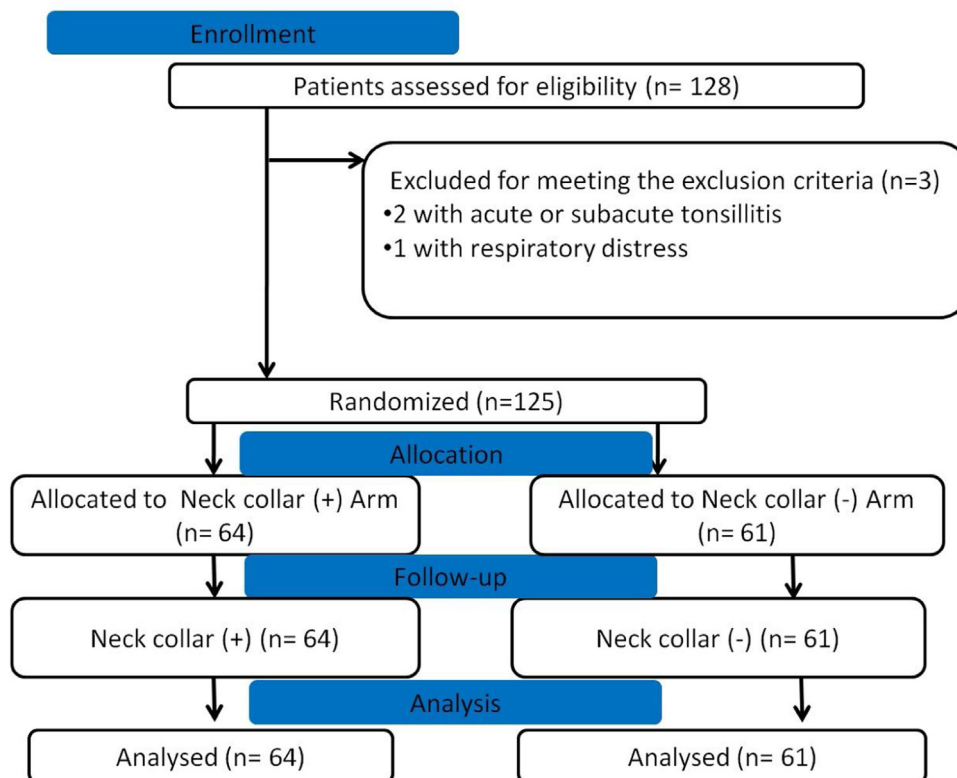
Head position is also critical in the maintenance of upper airway patency in children undergoing MRI examination. Maneuvers precluding the downward shift of the mandibula and providing slight extension of the head have been shown to increase upper airway dimensions.<sup>4</sup> Recently, the impact of Neck Collars (NC), which prevent downward dislocation of the mandibula, was shown to improve the airway patency in children undergoing MRI examination.<sup>5</sup> However, in that study, only children aged between 2 and 4 years were investigated.

This study aimed to investigate the role of NCs in maintaining airway patency by measuring anteroposterior (AP) and transverse dimensions and cross-sectional area (CSA) of the upper airway at different levels during MRI examination in a pediatric population sub grouped according to age (0–2, 2–8, and 8–16 years).

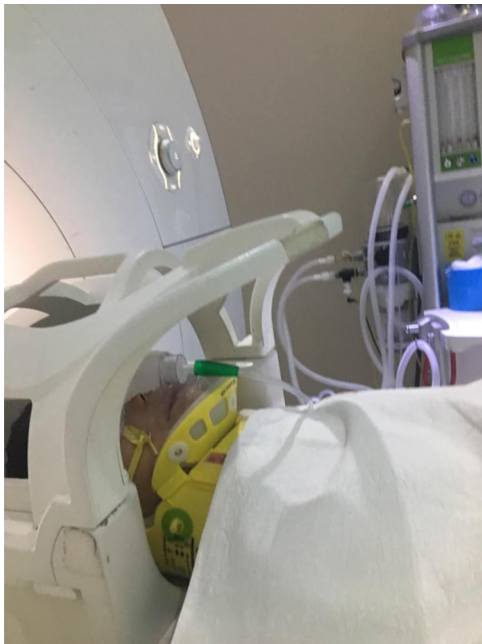
## Methods

### Patient selection

The present randomized, double-blind, prospective, and two-arm parallel study was conducted in patients aged 0 to 16 years and scheduled for MRI examination of the brain, lumbar area, and abdomen at the Education and Research Hospital, Department of Pediatrics, between February 2017 and March 2018. Patients with ASA (American Society of Anesthesiologists) physical status IV, respiratory distress, or any disease affecting the upper airway size were excluded. Written informed consent was obtained from all parents. The study protocol was approved by the Institutional Ethical Committee, and the study was performed in accordance with the most recent version of Helsinki Declaration. Power calculation was based on the authors' pilot study with the first 15 patients aged between 2 and 8 years. Priori *t*-tests, "the difference between two independent means", were used for the comparison of CSA of the Base Of the Tongue (BOT) measurements in the two groups (patients with NC,  $1.1 \pm 0.4 \text{ cm}^2$ ; patients without NC,  $0.8 \pm 0.3 \text{ cm}^2$ ;  $\alpha$  error = 0.05; power = 0.95; effect size = 0.85). Results showed that at least 31 patients were required in each group for an adequate sample size. The study was registered at the National Ministry of Health, Health Sciences University (Istanbul, Turkey).



**Figure 1** CONSORT flow diagram demonstrating patient allocation.



**Figure 2** Child using a NC during MRI examination.

### Study design

All patients without exclusion criteria were consecutively enrolled in the study by GY. After obtaining a detailed medical history of the patients, those without any exclusion criteria were admitted at the anesthesia preparation area (Fig. 1). Subjects were randomized NC+ or NC- groups using computer generated randomization. The randomization result of each subject was printed and placed in a sealed envelope by OE. Simple randomization was used, and the allocation ratio was 1:1. The sealed envelopes were opened, and NCs were placed in the MRI preparation room by GY. Patients in NC+ group received a rigid pediatric NC to prevent the downward displacement of the mandible and maintain a slight neck extension (Fig. 2). Patients in standard imaging group were allowed to lie supine with a slight extension of the head by approximately 20°.

A standardized sedation protocol was applied to all participants. Intramuscular midazolam (0.1 mg.kg<sup>-1</sup>) was administered 30 minutes before the procedure. Intravenous propofol (1 mg.kg<sup>-1</sup>) was then administered slowly for 1 minute just before imaging, and sedation was then continued with propofol (50 µg.kg<sup>-1</sup>.min<sup>-1</sup>) to avoid arousal without a significant physical stimulant.<sup>6</sup> During MRI examination, blood pressure, heart rate, and arterial oxygen saturation (SatO<sub>2</sub>) were monitored with monitors not interfering with MRI examination. Supplemental oxygen was provided with a pediatric face mask with gas flow rate of 2 L.min<sup>-1</sup>. In case of desaturation < 90% imaging was interrupted and airway patency was maintained with head tilt-chin lift, special airway devices, or bag-mask valve ventilation. Any bradycardia or hypotension was also managed in accordance with current treatment guidelines.<sup>7</sup>

Imaging was carried out on a 1.5 T whole-body system (Magnetom Avanto; Siemens Medical Solutions, Erlangen, Germany). MRI examination of the brain with a special

sequence on the neck region, from skull base down to subglottic region, was obtained using a dedicated head-neck coil. After MRI examination, image processing on a joined workstation using SYNGO (Siemens Medical Solutions) software was analyzed by two investigators experienced in pediatric MRI examination blinded to the study protocol and the imaging indications. Measurements of AP and transverse dimensions and CSA were performed to determine the upper airway size at three distinct levels: Soft Palate (SP), BOT, and tip of the epiglottis (Fig. 3). Patients were divided into three subgroups according to age (0–2, 2–8, and 8–16 years). Following overall comparison of the patients with and without NC, subgroup analysis was performed to show differences in airway patency among the three groups.

### Statistical analysis

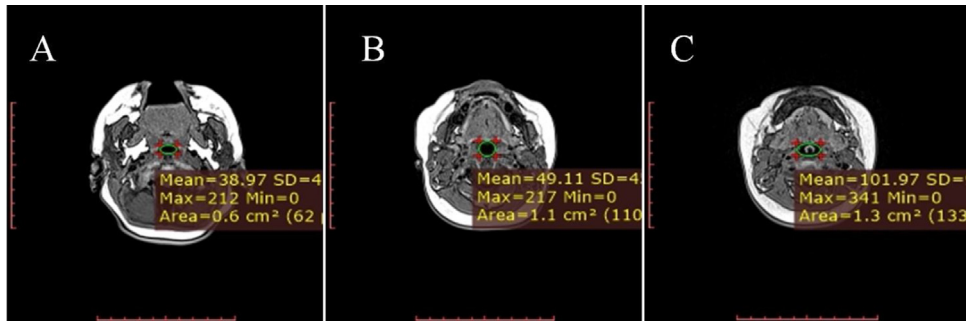
Statistical analyses were carried out using SPSS for Windows version 17 (SPSS, Chicago, IL, USA). The distribution of variables was studied using the Kolmogorov-Smirnov test. Continuous variables were presented as mean ± standard deviation, and categorical variables were presented as percentage. The AP and transverse diameters and CSA at the levels of BOT, SP, and epiglottis were compared in patients receiving a NC and patients not receiving a NC using Student's *t*-test. A second comparison was performed to detect the differences in airway diameters and CSAs in patients receiving and not receiving NC by dividing all patients into three groups according to their ages (0–2, 2–8, and 8–16 years). The second comparison was also carried out using Student's *t*-test. Chi-squared (χ<sup>2</sup>) test was used for univariate analysis of categorical variables. Two-sided  $p \leq 0.05$  was interpreted as statistically significant.

### Results

One hundred twenty-five children (56% male; mean age, 3.7 ± 2.3 years) were recruited in this study. Thirty-three children were from 0 to 2 years old, 62 children were from 2 to 8 years old, and 30 children were from 8 to 16 years old. Patients receiving a NC and those not receiving a NC were similar with respect to age, gender, induction time, MRI examination time, recovery time, ASA physical status, and hemodynamic parameters. However, mean SatO<sub>2</sub> was significantly higher in those receiving a NC compared to those not receiving a NC (97% ± 5% vs. 94% ± 8%,  $p = 0.003$ ). Although there was a significant difference in SatO<sub>2</sub> between subjects receiving a NC and those not receiving a NC, no significant clinical hypoxia event occurred in the two groups. The AP diameter and CSA at the levels of BOT and SP were significantly higher in NC+ patients compared to NC- ones. However, AP dimensions and CSAs at the epiglottis level were similar in the two groups (Table 1).

### Airway dimensions in different age groups

Subgroup analysis showed that AP diameter and CSA at the levels of BOT and SP were significantly higher in NC+ patients compared to NC- patients in all age groups (Table 2). At the



**Figure 3** Measurement of the upper airway CSA at different levels: (A) nasopharynx level, (B) oropharynx level, and (C) epiglottis level.

**Table 1** Demographic features and the airway dimensions of the study population.

	NC- (n = 61)	NC+ (n = 64)	p-value
Age, years	3.6 ± 2.3	3.8 ± 2.4	0.584 <sup>a</sup>
Gender, male (%)	34 (55.7%)	36 (59.0%)	0.769 <sup>b</sup>
Height, cm	96 ± 14	98 ± 14	0.283 <sup>a</sup>
Weight, kg	15 ± 7	16 ± 10	0.396 <sup>a</sup>
ASA physical status classification	1.9 ± 0.6	2.1 ± 0.6	0.067 <sup>a</sup>
Induction time, min	3.1 ± 0.3	2.9 ± 0.7	0.063 <sup>a</sup>
MRI time, min	21 ± 7	22 ± 6	0.279 <sup>a</sup>
Recovery time, min	88 ± 13	85 ± 16	0.473 <sup>a</sup>
Mean SBP, mmHg	94 ± 16	97 ± 14	0.296 <sup>a</sup>
Mean DBP, mmHg	54 ± 15	57 ± 12	0.312 <sup>a</sup>
Mean HR, n.min <sup>-1</sup>	113 ± 16	107 ± 15	0.067 <sup>a</sup>
Mean SatO <sub>2</sub> (%)	94 ± 8	97 ± 5	0.003 <sup>a</sup>
<b>Base of the tongue</b>			
AP (mm)	8.9 ± 3.2	12.1 ± 3.6	< 0.001 <sup>a</sup>
Transverse (mm)	11.1 ± 3.3	10.2 ± 3.6	0.229 <sup>a</sup>
CSA (cm <sup>2</sup> )	0.81 ± 0.3	1.13 ± 0.4	0.012 <sup>a</sup>
<b>Soft palate</b>			
AP (mm)	10.9 ± 3.8	14.2 ± 4.1	< 0.001 <sup>a</sup>
Transverse (mm)	5.5 ± 2.2	6.4 ± 2.5	0.074 <sup>a</sup>
CSA (cm <sup>2</sup> )	0.62 ± 0.2	0.74 ± 0.3	0.042 <sup>a</sup>
<b>Epiglottis</b>			
AP (mm)	8.9 ± 3.2	8.9 ± 2.2	0.984 <sup>a</sup>
Transverse (mm)	9.2 ± 4.1	10.1 ± 3.4	0.264 <sup>a</sup>
CSA (cm <sup>2</sup> )	0.75 ± 0.4	0.71 ± 0.3	0.399 <sup>a</sup>

Data are presented as mean ± standard deviation.

AP, Anteroposterior Diameter; CSA, Cross-Sectional Area; DBP, Diastolic Blood Pressure; HR, Heart Rate; SBP, Systolic Blood Pressure.

<sup>a</sup> p-value is the result of the Student *t*-test.

<sup>b</sup> p-value is the result of the Chi-square test.

epiglottis level, AP dimensions and CSAs were similar in NC+ and NC- patients in all age groups.

## Discussion

This study demonstrates that, compared to standard imaging without a NC, using a NC provides higher AP dimension and CSA at the levels of BOT and SP, indicating improved airway patency in all age groups of children undergoing MRI examination in supine position.

In children, the most favorable position of the head to preserve airway patency during sedation for MRI examination has been an issue of debate for years and led to

numerous trials reviewing this question. Although some of the trials reported the retrolingual area as the most responsive site of the upper airway for obstruction during sedation of children, contemporary data revealed that velopharynx is the most frequent site of obstruction in the course of sedation.<sup>8,9</sup> The depth of sedation was also associated with airway obstruction in a few studies. The study conducted by Evans et al. found that increasing depth of propofol anesthesia was related to the impairment in upper airway patency right through the whole upper airway and was most evident at the level of the epiglottis.<sup>10</sup> More recent data investigating airway patency during a minimal dose of propofol sedation in 138 children showed that AP dimensions at the

**Table 2** Comparison of the airway dimensions at the selected levels in different age groups.

	Age 0–2 years			Age 2–8 years			Age 8–16 years		
	NC- (n = 18)	NC+ (n = 15)	p-value <sup>a</sup>	NC- (n = 29)	NC+ (n = 33)	p-value <sup>a</sup>	NC- (n = 14)	NC+ (n = 16)	p-value <sup>a</sup>
<b>Base of the tongue</b>									
AP (mm)	8.4 ± 2.5	11.8 ± 3.3	0.001	8.9 ± 2.8	11.9 ± 3.5	0.048	9.1 ± 3.2	12.6 ± 3.9	0.010
Transverse (mm)	10.4 ± 3.1	9.9 ± 2.5	0.644	10.8 ± 2.9	10.3 ± 3.1	0.546	11.6 ± 3.3	10.7 ± 4.1	0.298
Area (cm <sup>2</sup> )	0.6 ± 0.2	1.0 ± 0.4	0.004	0.7 ± 0.3	1.0 ± 0.3	0.024	0.8 ± 0.4	1.1 ± 0.5	0.042
<b>Soft palate</b>									
AP (mm)	10.7 ± 2.3	13.1 ± 4.6	0.019	10.9 ± 3.3	13.6 ± 4.6	0.009	10.9 ± 3.9	14.3 ± 4.1	0.001
Transverse (mm)	5.2 ± 1.4	6.7 ± 2.4	0.058	5.6 ± 2.8	6.8 ± 2.6	0.422	5.7 ± 2.6	6.5 ± 2.5	0.253
Area (cm <sup>2</sup> )	0.5 ± 0.4	0.7 ± 0.3	0.036	0.6 ± 0.2	0.8 ± 0.4	0.046	0.7 ± 0.2	1.0 ± 0.1	0.010
<b>Epiglottis</b>									
AP (mm)	8.9 ± 3.8	8.9 ± 1.9	0.943	8.6 ± 3.7	8.9 ± 2.7	0.764	11.8 ± 6.4	8.9 ± 4.2	0.510
Transverse (mm)	8.9 ± 3.8	10.2 ± 2.9	0.283	9.0 ± 3.7	9.6 ± 3.1	0.754	9.2 ± 4.1	9.9 ± 3.5	0.461
Area (cm <sup>2</sup> )	0.7 ± 0.4	0.6 ± 0.3	0.419	0.7 ± 0.4	0.6 ± 0.5	0.396	0.8 ± 0.5	0.9 ± 0.3	0.785

Data are presented as mean ± standard deviation.

AP, Anteroposterior diameter; CSA, Cross-Sectional Area.

<sup>a</sup> p-value is the result of the Student *t*-test.

level of BOT were the most frequently influenced site of the upper airway.<sup>11</sup> Based on the results of previous studies, it appears that a slight extension of the head in supine posture is optimal in improving the alignment of the axes of the airway. In patients with obstructive sleep apnea, mandibular advancement splints were shown to increase the volume of the upper airway predominantly by increasing the volume of the velopharynx.<sup>12</sup> Hence, it is logical to consider that, in conjunction with the slight extension of the head, anterior protrusion of mandible achieved by a device such as NC might improve airway patency during sedation.

Moving the mandibula ahead using a NC removes the tongue forward and expands the caliber of the retrolingual and retropalatal airway, whereas SP, which is connected to the tongue, is removed forward as well.<sup>13–15</sup> Nevertheless, this application might also lead to a concurrent decrease in CSA at the level of the epiglottis. Recently, Moustafa et al. carried out a study investigating the role of NC on upper airway dimension and CSA in 60 patients aged 2 to 4 years scheduled for MRI examination and who received propofol-midazolam sedation.<sup>5</sup> These authors reported that the AP diameter and CSA of the upper airway were significantly enhanced when a NC was applied to the index patient. The authors also noted that CSA at the level of the epiglottis was decreased after the application of a NC. A source of uncertainty regarding these data is that the only enrolled children were aged 2 to 4 years. However, whether these findings could be generalized to the whole pediatric population is worthy of consideration. Thus, in this study, children in all age groups were enrolled to better represent the whole pediatric population.

In the study, the findings are consistent with that of Moustafa et al., who reported enhanced retropalatal and retroglottal airway dimensions with the application of a soft pediatric NC. Moreover, the results raise the knowledge regarding the application of NC in the sedation of children to an upper level by expanding the relevant population to all pediatric patients. The improvement in retropalatal and ret-

roglossal airway dimensions demonstrated in this study may partly be explained by the ability of a NC in displacing the mandibula and tongue forward and accordingly expanding the caliber of the airway.

This study has several limitations. First, we did not obtain NC+ and NC- images for the same index patient and randomized all enrolled children to groups receiving and not receiving NC. We considered that imaging the patient first with a NC and then without a NC would cause an ethical issue as a consequence of increased imaging time and increased sedation, which might also affect the measurements concerning the upper airway. Second, we did not perform the sequences at a specific time of the respiratory cycle because of high respiratory rate in the majority of the imagined population. Third, we have not recorded end-tidal CO<sub>2</sub>, which would provide additional information regarding ventilation improvement with the use of NC. Finally, sample size calculation was based on a pilot study with 15 patients aged between 2 and 8 years, which do not encompass the whole study population recruited in this study. These results therefore need to be interpreted with caution.

## Conclusion

In summary, this study clearly demonstrates that the application of a NC enhances the retropalatal end and retroglottal airway dimensions in the whole pediatric population undergoing MRI examination and receiving sedation in supine position. The use of a NC in MRI examination of the pediatric population is suggested, particularly in patients who need an increased duration of sedation due to the underlying disease.

## Conflicts of interest

The authors declare no conflicts of interest.

## References

1. Barkovich MJ, Xu D, Desikan RS, et al. Pediatric neuro MRI: tricks to minimize sedation. *Pediatr Radiol*. 2018;48:50–5.
2. Bosemani T, Hemani M, Cruz A, et al. Assessment of upper airway patency in spontaneously breathing non-intubated neonates and infants undergoing conventional MRI of head and neck. *Childs Nerv Syst*. 2015;31:1521–5.
3. Heng Vong C, Bajard A, Thiesse P, et al. Deep sedation in pediatric imaging: efficacy and safety of intravenous chlorpromazine. *Pediatr Radiol*. 2012;42:552–61.
4. Vialet R, Nau A, Chaumoitre K, et al. Effects of head posture on the oral, pharyngeal and laryngeal axis alignment in infants and young children by magnetic resonance imaging. *Pediatr Anesth*. 2008;18:525–31.
5. Moustafa MA, Emara DM, Nouh MR. Effect of a neck collar on upper airway size in children sedated with propofol-midazolam combination during magnetic resonance imaging. *Paediatr Anaesth*. 2015;25:421–7.
6. Malviya S, Voepel-Lewis T, Tait AR, et al. Depth of sedation in children undergoing computed tomography: validity and reliability of the University of Michigan Sedation Scale (UMSS). *Br J Anaesth*. 2002;88:241–5.
7. Duff JP, Topjian A, Berg MD, et al. 2018 American heart association focused update on pediatric advanced life support: An update to the American heart association guidelines for cardiopulmonary resuscitation and emergency cardiovascular care. *Circulation*. 2018;138:e731–9.
8. Morikawa S, Safar P, DeCarlo J. Influence of the headjaw position upon upper airway patency. *Anesthesiology*. 1961;22:265–70.
9. Mathru M, Esch O, Lang J, et al. Magnetic resonance imaging of the upper airway. Effects of propofol anesthesia and nasal continuous positive airway pressure in humans. *Anesthesiology*. 1996;84:273–9.
10. Evans RG, Crawford MW, Noseworthy MD, et al. Effect of increasing depth of propofol anesthesia on upper airway configuration in children. *Anesthesiology*. 2003;99:596–602.
11. Machata AM, Kabon B, Willschke H, et al. Upper airway size and configuration during propofol-based sedation for magnetic resonance imaging: An analysis of 138 infants and children. *Paediatr Anaesth*. 2010;20:994–1000.
12. Chan AS, Sutherland K, Schwab RJ, et al. The effect of mandibular advancement on upper airway structure in obstructive sleep apnoea. *Thorax*. 2010;65:726–32.
13. Isono S, Tanaka A, Sho Y, et al. Advancement of the mandible improves velopharyngeal airway patency. *J Appl Physiol (1985)*. 1995;79:2132–8.
14. Isono S, Tanaka A, Tagaito Y, et al. Pharyngeal patency in response to advancement of the mandible in obese anesthetized persons. *Anesthesiology*. 1997;87:1055–62.
15. Isono S, Tanaka A, Ishikawa T, et al. Sniffing position improves pharyngeal airway patency in anesthetized patients with obstructive sleep apnea. *Anesthesiology*. 2005;103:489–94.