



SCIENTIFIC ARTICLE

Comparison between erector spinal plane block and epidural block techniques for postoperative analgesia in open cholecystectomies: a randomized clinical trial



Thiago Mamoru Sakae  ^{a,b,*}, Luiz Henrique Ide Yamauchi ^{a,c,d},
Augusto Key Karazawa Takaschima ^{a,c,d}, Julio C. Brandão ^d,
Roberto Henrique Benedetti ^{a,b,c,d}

^a Serviço de Anestesiologia SIANEST, Florianópolis, SC, Brazil

^b Universidade do Sul de Santa Catarina (UNISUL), Florianópolis, SC, Brazil

^c Hospital Florianópolis, Florianópolis, SC, Brazil

^d TSA Sociedade Brasileira de Anestesiologia (SBA), Rio de Janeiro, RJ, Brazil

Received 15 July 2019; accepted 1 December 2019

Available online 10 February 2020

KEYWORDS

Cholecystectomy;
Analgesia;
Regional anesthesia;
Randomized
controlled trial;
ESP block;
Epidural block

Abstract

Introduction and objectives: Blockade of the Erector Spinal Muscle (ESP Block) is a relatively new block, initially described for chronic thoracic pain analgesia, but it has already been described for anesthesia and analgesia in thoracic surgical procedures and, more recently, for high abdominal surgeries. The aim of the study was to compare two techniques, ESP Block and Epidural Block, with morphine and local anesthetic for postoperative analgesia of open cholecystectomy surgeries.

Methods: Controlled single-blind randomized clinical trial with 31 patients (ESP Block, n = 15; Epidural, n = 16), of both genders, ages between 27 and 77 years. The ESP block was performed at the T8 level with injection of 20 mL of 0.5% ropivacaine bilaterally. The epidural block was performed at the T8–T9 space with 20 mL of 0.5% ropivacaine and 1 mg of morphine.

Results: The ESP Block group presented higher mean Numeric Pain Scale (NPS) values for pain in the up to 2 hour ($p = 0.001$) and in the 24 hour ($p = 0.001$) assessments. The ESP Block group had a three-fold increased risk (43.7% vs. 13.3%) of rescue opioid use in the 24 postoperative hours when compared to the epidural group (RR = 3.72, 95% CI: 0.91 to 15.31, $p = 0.046$).

Conclusion: ESP Block did not prove to be an effective technique for postoperative analgesia of open cholecystectomy, at the doses performed in this study, having required more use of rescue opioid, and without differences in NPS. More comprehensive studies are required to assess the efficacy of ESP block for the visceral and abdominal somatic component, considering the specific blockade level.

© 2020 Sociedade Brasileira de Anestesiologia. Published by Elsevier Editora Ltda. This is an open access article under the CC BY-NC-ND license (<http://creativecommons.org/licenses/by-nc-nd/4.0/>).

* Corresponding author.

E-mails: thiago.sakae@unisul.br, thiagosakae@gmail.com (T.M. Sakae).

PALAVRAS CHAVE

Colecistectomia;
 Analgesia;
 Anestesia regional;
 Ensaio controlado
 randomizado;
 ESP block;
 Bloqueio epidural

Comparaç o entre as t cnicas de bloqueio do plano do m sculo eretor da espinha e bloqueio epidural para analgesia p s-operat ria em colecistectomias abertas: um ensaio cl nico randomizado

Resumo

Justificativa e objetivo: O Bloqueio do Plano do M sculo Eretor da Espinha (ESP block)   um bloqueio relativamente novo, inicialmente descrito para analgesia de dor tor cica cr nica, por m j  descrito para anestesia e analgesia em procedimentos cir rgicos tor cicos e, mais recentemente, para cirurgias abdominais altas. O estudo objetivou comparar as t cnicas de bloqueio ESP block e bloqueio epidural com morfina e anest sico local para analgesia p s-operat ria de cirurgias de colecistectomia aberta.

M todo: Estudo cl nico randomizado controlado, unicego com 31 pacientes (ESP block, n = 15; Epidural, n = 16), de ambos os sexos, idades entre 27 e 77 anos. O ESP block foi realizado no n vel de T8 com injeç o de 20 mL de ropivaca na 0,5% bilateral. O bloqueio Epidural foi realizado no espaço T8-T9 com 20 mL de ropivaca na 0,5% e 1 mg de morfina.

Resultados: O grupo ESP block apresentou valores m dios de dor pela Escala Visual Num rica (EVN) maiores nas avaliaç es at  2 horas ($p = 0,001$) e em 24 horas ($p = 0,001$). O grupo ESP block apresentou um risco tr s vezes maior – 43,7% vs. 13,3% – de uso de opioide de resgate nas 24 horas p s-operat rias do que o grupo epidural (RR = 3,72; 95% IC 0,91 a 15,31; $p = 0,046$).

Conclus o: Nas doses realizadas nesse estudo, o ESP block n o se mostrou uma t cnica efetiva para analgesia p s-operat ria de colecistectomia aberta, com mais uso de opioide de resgate e sem diferenças na escala visual num rica de dor. Necessita-se de estudos mais abrangentes avaliando a efic cia do ESP block para o componente visceral e som tico abdominal, considerando o n vel do bloqueio espec fico.

  2020 Sociedade Brasileira de Anestesiologia. Publicado por Elsevier Editora Ltda. Este   um artigo Open Access sob uma licena CC BY-NC-ND (<http://creativecommons.org/licenses/by-nc-nd/4.0/>).

Introduction

Post-operative analgesia for medium and large thoracic and upper abdominal surgeries still pose a challenge to modern anesthesiology.^{1,2} Neuraxial block techniques (thoracic epidural block, spinal lumbar anesthesia) for this region are usually associated with general anesthesia. Adjuvants aim to extend postoperative analgesia time and promote improved quality to anesthesia, in addition to decreasing consumption of anesthetics and of opioids (intra and post-operative), with all the positive consequences, including early mobilization and reduction in the incidence and extension of atelectasis in the immediate post-operative period.^{1,2}

Multiple ultrasound guided (USG) procedures have been described as single or associated techniques, and also for treating chronic thoracic and abdominal pain. Erector Spinae Plane Block (ESP) is a relatively new ultrasound-guided technique, originally described to manage thoracic pain when performed at the T5 vertebra level,^{3,4} but it has also been successfully used for abdominal analgesia when performed at the lower T8–10 levels.^{5,6}

ESP has also been described as relatively easier to perform when compared to other conventional blocks, such as epidural anesthesia and paravertebral block.^{5–7}

Clinical findings of previous studies^{3–7} have been supported by studies in cadavers that have shown the spread of the anesthetic solution injected in the deep interfascial plane of the erector spinae muscle, near the intervertebral foramen, surrounding the dorsal and ventral branches of the thoracic spine nerve roots.^{8–10}

The post-operative pain that follows a cholecystectomy using a Kocher incision has both a somatic and visceral component. More recently, the erector spinae muscle plane block (ESP) has proved its effectiveness by providing ample thoracic,^{1,2,7,10} high abdominal^{5,6,8,9} somatic and visceral analgesia, when performed at the level of T5–T6, in addition to analgesia for vertebral spine procedures.^{11–13} Therefore, bilateral ESP block on the transverse process of T8 may provide effective post-cholecystectomy analgesia and reduce the incidence of excessive opioid use-associated adverse effects.^{6–9}

The effectiveness of the block has been shown in several studies, and this has made the same pattern of blocks to be performed in the lumbar and even cervical regions.^{11–13} ESP block is expected to result in less complications, such as nerve paralysis, hematoma, pulmonary lesions, among others, given the injection target in the ESP block is the transverse process of the vertebra, which is not close to more vulnerable anatomical structures.³

The comparison with well-established techniques, such as the epidural block, is mandatory. The epidural block, due to possible counterindications, opens the possibility to other safe alternatives that provide appropriate analgesia, without approaching the neuroaxis and decreasing likelihood of epidural anesthesia-associated sympathetic blocks.^{8,14,15}

The objective of the present study was to compare erector spinae plane block and epidural block techniques in relation to post-operative analgesia in open cholecystectomies.

Methods

A single-blind, non-inferiority, randomized clinical trial was performed after approval by the Research Ethics Committee of *Universidade do Sul de Santa Catarina* (CAAE 96216918.7.0000.5369) and registration on the Brazilian Clinical Trial Registry (ReBEC – Registro de Ensaios Clínicos Brasileiros) registry RBR-29r8nr <http://www.ensaiosclinicos.gov.br/rg/RBR-29r8nr/>.

Sample size was calculated according to non-inferiority trials,¹⁶ the parameters adopted were 0.05 alfa, 0.20 beta, 7.9 z^2 errors, measurement standard deviation of 3.0, and a clinically important difference on the Numeric Pain Scale (NPS) for pain over 4 points. Thus, the number required for non-inferiority between the epidural block and erector spinae plane block groups was 15 patients per group.

Patients over 18 years of age, both sexes, ASA I and II, submitted to open cholecystectomy surgery and elective Kocher incision were included. Patients with urgent/emergency indication cholecystectomy, intraoperative cholangiography or posterior biliary tract handling, ASA III or higher, history of allergy to any study medication, use of anticoagulants, block failure, use of anticonvulsants or postoperative cognitive deficit that prevented the patient from understanding/answering the questionnaire were excluded.

Surveyors in the postoperative were blind to the group to which patients belonged and to intraoperative management and complications (hypotension, bradycardia, use of vasoactive drugs).

Patients were chosen randomly by random number draw of the Epiinfo 6 software EpiTab function, for group samples: 1 – “Positive control” group with epidural anesthesia; and 2 – Intervention group with Erector Spinae Plane Block (ESP block).

Variables assessed were sex, age, BMI, ASA classification, 0 to 10 (2 hours and 24 hours) Numeric Pain Scale (NPS), intraoperative complications (bradycardia, hypotension, vasoactive drug required), postoperative nausea and vomiting and adverse reactions (pruritus, urinary retention). Urinary retention was defined as requiring urethral catheter in 24 hours.

Both block groups (epidural – Group 1 or ESP block – Group 2) were submitted to aseptic technique, after venous access, monitoring (pulse oximetry, cardioscopy and non-invasive pressure) and light sedation (1 to 5 mg midazolam and 25 to 75 mcg intravenous fentanyl), receiving oxygen supplementation and duly positioned with the help of an assistant.

The positive control group was submitted to epidural anesthesia with 20 mL 0.5% ropivacaine and 1 mg of morphine. Epidural anesthesia was performed with a Tuohy 18G median needle, T8–T9 level, in addition to administration of 2% lidocaine with vasoconstrictor, 4 mL given as test-dose.

The intervention group was submitted to bilateral erector spinae plane block (ESP block). The ESP block was performed with patient sitting, and a high frequency, 5–13 MHz linear transducer (LOGIQe; GE Healthcare) was used in the longitudinal parasagittal direction to identify the T8 transverse process, counting the first to eighth rib. The device was then pulled medially until the tip of the transverse process of T8 was identified. The 22G 5 cm needle (BBraun, Stimu-

Table 1 Clinical characteristics.

| Variable | ESP block group | Epidural group | <i>p</i> |
|----------------------------|-----------------|----------------|----------|
| Sex | | | |
| Male | 6 (40%) | 6 (37.5%) | 0.886 |
| Female | 9 (60%) | 10 (53.5%) | |
| Age (mean;SD) | 56.40 (16,21) | 57.38 (11.69) | 0.848 |
| BMI (kg. m ⁻²) | | | |
| 18–24 | 4 (26.7%) | 5 (31.2%) | 0.803 |
| 25–29 | 10 (66.7%) | 10 (62.5%) | |
| > 30 | 1 (6.7%) | 1 (6.2%) | |
| ASA | | | |
| I | 5 (33.3%) | 5 (31.2%) | 0.902 |
| II | 10 (66.7%) | 11 (68.8%) | |

BMI, Body Mass Index; ASA, American Society of Anesthesiology classification; *p*, *p*-value.

plex A50, 22G) was inserted into the plane, craniocaudal direction, going through skin, subcutaneous and muscle layers (trapeze muscle, greater dorsal muscle fascia and spinal erector muscle) until the tip was between the anterior fascia of the spinal erector muscle and transverse process of T8. The plane was checked with dispersion of 0.5 to 1 mL saline solution and visualization of linear dispersion of fluid in the spinal erector muscle plane, followed by injection of 20 mL of 0.5% ropivacaine. The technique was bilateral.

After being submitted to epidural anesthesia or ESP block, both groups were submitted to general anesthesia, and anesthesia induction was performed with 3 mcg.kg⁻¹ of fentanyl, 0.4 mg.kg⁻¹ of atracurium and 1 to 2 mg.kg⁻¹ propofol. All patients received prophylactic antibiotics with 2 g cefazoline, analgesia with 100 mg ketoprofen, 10 mg dexamethasone and 8 mg ondansetron intraoperatively for prophylaxis of postoperative nausea and vomiting.

Mean, median and standard-deviation for continuous variables and proportions for categorical variables were calculated. Pearson Chi-Square test or Fisher exact test to check association among categorical variables were used, as appropriate. For the association of numerical variables, Kolmogorov Smirnov or Wilcoxon tests were used. The level of significance adopted was 95%. Cut-off points of independent variables were based on conceptual models. Data stored were analyzed on the SPSS 20.0 program.

Results

The study included 31 patients submitted to open cholecystectomy, of which 15 patients in the intervention group (ESP block) and 16 patients in the positive control group (epidural) (Fig. 1). Mean age ranged between 27 and 77 years (mean: 57.23 years), with a slight predominance of women (61.3%). BMI ranged between 18 and 38 kg.m⁻², with predominance of BMI between 25–29 (64.5%). ASA classification was predominantly ASA 2 (67.7%) (Table 1).

There were statistically significant differences between the groups in the post-surgical up to two-hour and 24-hour assessments on the Numeric Pain Scale (NPS). The intervention group had mean pain NPS values higher in the up to

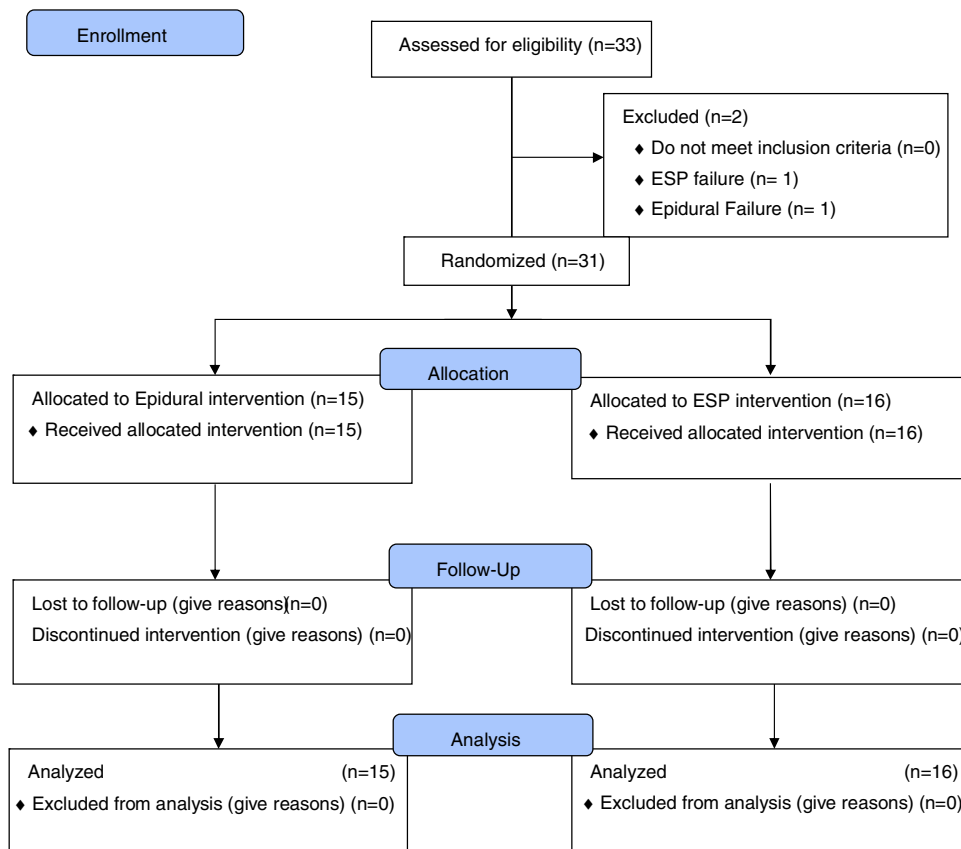


Figure 1 Study flow chart (CONSORT standard).

Table 2 Comparison of numeric pain scale between groups.

| Group | Pain 2 hours | <i>p</i> | Pain 24 hours | <i>p</i> |
|-----------|--|----------|--|----------|
| ESP block | Mean: 6.00 Median: 5.50 Standard-deviation: 1.89 | 0.001 | Mean: 3.69 Median: 3.00 Standard-deviation: 2.44 | 0.001 |
| Epidural | Mean: 3.00 Median: 3.00 Standard-deviation: 2.29 | | Mean: 0.53 Median: 0.00 Standard-deviation: 1.23 | |

two-hour ($p = 0.001$) and 24-hour ($p = 0.001$) assessments (Table 2).

The use of opioid required in the post-anesthetic care unit was seven-fold higher in the intervention group (ESP block) (RR = 7.87; 95% IC: 1.08 to 57.25; $p = 0.026$). Regarding rescue opioid use in post-operative 24 hours, the intervention group had a three-fold higher risk – 43.7% vs. 13.3% – than the epidural group (RR = 3.72; 95% IC: 0.91 to 15.31; $p = 0.046$). The most frequently used opioid among these patients was tramadol, at a dose of 100 mg (18.1% of patients), followed by morphine (9.1% of patients).

There were no statistically significant differences in the incidence of intraoperative complications ($p = 0.277$), adverse reactions ($p = 0.381$) or postoperative nausea and vomiting ($p = 0.531$).

Discussion

The results of the present study show inferiority of ESP block associated analgesic plane, when compared to the group submitted to epidural anesthesia.

Technically, based on anatomical studies on fresh cadavers, the likely site of action of the ESP block covers an extensive area after the injection of local anesthetics, spread both through the dorsal and ventral regions of the thoracic spinal bundles and nerve branches.^{2,3,15-18} Therefore, the effective block of the ventral branch and the sympathetic fibers concomitantly is expected to occur, and may promote effective anesthesia and analgesia, controlling somatic and visceral pain. In practical terms, however, we have perceived this satisfactory analgesia response in

thoracic and some abdominal wall surgeries, with still some limited evidence in the literature on the variable response as to the control of abdominal visceral and somatic pain.^{15–19}

After the injection of efficacious concentrations and volumes of local anesthetics using ESP, although there have been reports showing relief of visceral and somatic pains, there is still some variability in the management of visceral pain, without seeming to be a consensus established on the control of this kind of pain when anesthesia with ESP is performed.^{8,19,20} Some studies performed on cadavers have shown that spread of local anesthetics injected through ESP to ventral branches at multiple levels, to the neural foramen and to epidural spaces were not well established.^{19,20}

In a study by Yang et al.,²¹ the reach of local anesthetics was limited only to ventral branches when performed at multiple levels and hardly spread to the thoracic paravertebral space. There are studies reporting that the ESP block was more limited to dorsal branches and only roughly 10% involved the ventral branch or dorsal root ganglion,^{18,20} corroborating the findings of our study.

A study in cadavers designed to simulate ESP by Ivanusik et al.¹⁸ documented an extensive craniocaudal and medial-lateral spread of dye, both deep and superficial to spinal erector muscles. However, there was no spread of the dye anterior to the paravertebral space where it surrounds the ventral and dorsal origins of thoracic spinal nerve branches. The involvement of the dorsal branch was mostly posterior to the costotransverse foramen. There was potential involvement of the lateral cutaneous branches and of the lateral intercostal nerves at the angle of the ipsilateral ribs.^{18,21}

Among the limitations of the study, the choice of the volume of ropivacaine, 20 mL instead of the higher volumes used in other studies may have interfered in wider spread of the anesthetic and influenced the block level in the ESP group. In theory, the volume of 3 mL to block each dermatome¹⁷ would provide appropriate dispersion for the volume adopted in the present study. The impossibility to control more dorsal or caudal dispersion could also influence results. Moreover, using adjuvants (corticosteroids, alfa 2 agonists, ketamine), already well-established in other types of block, has not been described for the ESP block yet, and could improve the potential of the block to control visceral pain that apparently did not occur in the present study.

The small sample size, with characteristics of non-inferiority clinical trials, and the low statistical power of the study, may reveal major differences between treatments in which the null hypothesis is not rejected, due to the insufficient number of patients or to the over variability of data. This may lead to a more likely type II error (not finding a difference where there actually is), one of the characteristics included in the current study, not being able, however, to find differences where there actually are, which would be more harmful from the scientific and ethical point of view. This inference error has been, frequently, underscored with the expression “The absence of evidence is not an evidence of absence”.¹⁶

This can explain statistically significant differences being found between groups for adverse reactions, complications and postoperative nausea and vomiting.

Conclusions

The fact that ESP does not seem to block the visceral abdominal component well may be effectively one of the limitations for using ESP for some types of abdominal surgeries, unlike what is perceived for thoracic, breast surgeries and other surgeries of the thoracic and abdominal walls and even hip arthroplasties, depending on the level where the block is performed.

More comprehensive studies are required to assess the efficacy of ESP for the visceral and somatic abdominal component, considering the specific block level.

Conflicts of interest

The authors declare no conflicts of interest.

References

1. Droguethi A, Fusco P. The ultrasound-guided continuous erector spinae plane block for postoperative analgesia in video-assisted thoracoscopic lobectomy. *Reg Anesth Pain Med.* 2017;42:537.
2. Leyva FM, Mendiola WE, Bonilla AJ, et al. Continuous erector spinae plane (ESP) block for postoperative analgesia after minimally invasive mitral valve surgery: a case report. *J Cardiothorac Vasc Anesth.* 2018;32:2271–4.
3. Forero M, Adhikary SD, Lopez H, et al. The erector spinae plane block: a novel analgesic technique in thoracic neuropathic pain. *Reg Anesth Pain Med.* 2016;41:621–7.
4. Forero M, Rajarathinam M, Adhikary SD, Chin KJ. Erector spinae plane block for the management of chronic shoulder pain: a case report. *Can J Anaesth.* 2018;65:288–93.
5. Restrepo-Garces CE, Chin KJ, Suarez P, et al. Bilateral continuous erector spinae plane block contributes to effective postoperative analgesia after major open abdominal surgery: a case report. *A A Case Rep.* 2017;9:319–21.
6. Chin KJ, Malhas L, Perlas A. The erector spinae plane block provides visceral abdominal analgesia in bariatric surgery: a report of 3 cases. *Reg Anesth Pain Med.* 2017;42:372–6.
7. Khalil AE, Abdallah NM, Bashandy GM, et al. Ultrasound-guided serratus anterior plane block versus thoracic epidural analgesia for thoracotomy pain. *J Cardiothorac Vasc Anesth.* 2017;31:152–8.
8. Chin KJ, Adhikary S, Sarwani N, et al. The analgesic efficacy of pre-operative bilateral erector spinae plane (ESP) blocks in patients having ventral hernia repair. *Anaesthesia.* 2017;72:452–60.
9. Altinpulluk EY, Simón DG, Fajardo-Pérez M. Bloqueo del plano del erector del espinal para analgesia tras cesárea del segmento inferior: informe de caso. *Rev Esp Anestesiología Reanim.* 2018;65:287–90.
10. Muñoz F, Cubillos J, Bonilla AJ, et al. Erector spinae plane block for postoperative analgesia in pediatric oncological thoracic surgery. *Can J Anesth.* 2017;64:880–2.
11. Kline J, Chin KJ. Modified dual-injection lumbar erector spine plane (ESP) block for opioid-free anesthesia in multi-level lumbar laminectomy. *Korean J Anesthesiol.* 2019;72:188–90.
12. Tulgar S, Thomas DT, Suslu H. Ultrasound guided erector spinae plane block relieves lower cervical and interscapular myofascial pain, a new indication. *J Clin Anesth.* 2018;53:74.

13. Ilker I, Zafeer KM, Tetsuya S. Ultrasound guided erector spinae plane block for bilateral lumbar transverse process fracture: A new or a pushing indication? *Am J Emerg Med.* 2019;37:557.
14. Kim E, Kwon W, Oh S, et al. The erector spinae plane block for postoperative analgesia after percutaneous nephrolithotomy. *Chin Med J (Engl).* 2018;131:1877–8.
15. Bang S. Erector spinae plane block: an innovation or a delusion? *Korean J Anesthesiol.* 2019;72:1–3.
16. Pinto VF. Estudos clínicos de não inferioridade: fundamentos e controvérsias. *J Vasc Bras.* 2010;9:145–51.
17. Ueshima H, Hiroshi O. Spread of local anesthetic solution in the erector spinae plane block. *J Clin Anesth.* 2018;45:23.
18. Ivanusic J, Konishi Y, Barrington MJ. A cadaveric study investigating the mechanism of action of erector spinae blockade. *Reg Anesth Pain Med.* 2018;43:567–71.
19. Lee TH, Barrington MJ, Tran TM, et al. Comparison of extent of sensory block following posterior and subcostal approaches to ultrasound-guided transversus abdominis plane block. *Anaesth Intensive Care.* 2010;38:452–60.
20. Barrington MJ, Ivanusic JJ, Rozen WM, et al. Spread of injectate after ultrasound-guided subcostal transversus abdominis plane block: a cadaveric study. *Anaesthesia.* 2009;64:745–50.
21. Yang H, Choi YJ, Kwon HOJ, et al. Comparison of injectate spread and nerve involvement between retrolaminar and erector spinae plane blocks in the thoracic region: a cadaveric study. *Anaesthesia.* 2018;73:1244–50.