



REVISTA BRASILEIRA DE ANESTESIOLOGIA

Publicação Oficial da Sociedade Brasileira de Anestesiologia
www.sba.com.br



SCIENTIFIC ARTICLE

Evaluation of the neurotoxic effects of intrathecal administration of (S)-(+)-Ketoprofen on rat spinal cords: randomized controlled experimental study[☆]



Cengiz Kaya ^{a,*}, Yunus O. Atalay ^b, Bilge C. Meydan ^c, Yasemin B. Ustun ^a,
Ersin Koksal ^a, Sultan Caliskan ^c

^a Ondokuz Mayıs University, School of Medicine, Department of Anesthesiology, Kurupelit, Samsun, Turkey

^b Ondokuz Mayıs University, School of Medicine, Department of Radiology, Outpatient Service, Kurupelit, Samsun, Turkey

^c Ondokuz Mayıs University, School of Medicine, Department of Pathology, Kurupelit, Samsun, Turkey

Received 10 October 2018; accepted 17 March 2019

Available online 21 May 2019

KEYWORDS

Cyclooxygenase inhibitor;
Intrathecal injection;
(S)-(+)-Ketoprofen;
Neurotoxicity;
Inflammation

Abstract

Background and objectives: Intrathecal administration of non-steroidal anti-inflammatory drugs is more efficacious for post-operative pain management. Cyclooxygenase inhibiting non-steroidal anti-inflammatory drugs like (S)-(+)-Ketoprofen, may be effective at lower intrathecal doses than parenteral ones. Preclinical safety regarding possible neurotoxicity associated with the intrathecal (S)-(+)-Ketoprofen was not evaluated. Here we analysed the neurotoxicity of intrathecally administered (S)-(+)-Ketoprofen in rats.

Methods: A randomized placebo-controlled experimental study was conducted. Sprague-Dawley rats (250–300 g) aged 12–16 weeks were randomly divided into 2 treatments [100 and 800 µg (S)-(+)-Ketoprofen] and control (sterile water) groups. Intrathecal catheters were placed via the atlantoaxial space in anesthetized rats. Pinch-toe tests, motor function evaluations and histopathological examinations of the spinal cord and nerve roots were performed at days 3, 7 and 21. Spinal cord sections were evaluated by light microscopy for the dorsal axonal funiculus vacuolation, axonal myelin loss, neuronal chromatolysis, neuritis, meningeal inflammation, adhesions, and fibrosis.

[☆] Preliminary data for this study were submitted as a poster presentation at the Turkish Society of Anesthesiology and Reanimation Congress, 26–30 October, 2016, Istanbul, Turkey. The randomized placebo-controlled experimental study was conducted at the Experimental Animals and Application Research Center, Samsun, Turkey.

* Corresponding author.

E-mail: cengiz.kaya@omu.edu.tr (C. Kaya).

PALAVRAS-CHAVE

Inibidor da
ciclooxigenase;
Injeção intratecal;
(S)-(+)-cetoprofeno;
Neurotoxicidade;
Inflamação

Results: Rats in all the groups exhibited normal pinch-toe testing response (score = 0) and normal gait at each observed time (motor function evaluation score = 1). Neurotoxicity was higher with treatments on days 3 and 7 than that on day 21 (2, 3, 0, $p=0.044$; 2, 5, 0, $p=0.029$, respectively). On day 7, the total scores reflecting neuronal damage were higher in the 800 μg group than those in the 100 μg and Control Groups (5, 3, 0, $p=0.048$, respectively).

Conclusion: Intrathecal (S)-(+)-Ketoprofen caused dose-dependent neurohistopathological changes in rats on days 3 and 7 after injection, suggesting that (S)-(+)-Ketoprofen should not be intrathecally administered.

© 2019 Sociedade Brasileira de Anestesiologia. Published by Elsevier Editora Ltda. This is an open access article under the CC BY-NC-ND license (<http://creativecommons.org/licenses/by-nc-nd/4.0/>).

Avaliação dos efeitos neurotóxicos da administração intratecal do (S)-(+)-cetoprofeno em medula espinhal de rato: estudo experimental randômico e controlado

Resumo

Justificativa e objetivos: A administração intratecal de anti-inflamatórios não esteroides é mais eficaz no tratamento da dor pós-operatória. Anti-inflamatórios não esteroides, como o (S)-(+)-cetoprofeno, pode ser eficaz em doses intratecais inferiores às parenterais. A segurança pré-clínica relativa à possível neurotoxicidade associada ao (S)-(+)-cetoprofeno intratecal não foi avaliada. Neste estudo avaliamos a neurotoxicidade do (S)-(+)-cetoprofeno administrado por via intratecal em ratos.

Métodos: Conduzimos um estudo experimental randomizado e controlado por placebo em ratos Sprague-Dawley (250–300 g) com idades entre 12 e 16 semanas. Eles foram randomicamente divididos em dois grupos de tratamento [100 e 800 μg de (S)-(+)-cetoprofeno] e um de controle (água estéril). Cateteres intratecais foram colocados através do espaço atlantoaxial nos ratos anestesiados. Testes de pinça, avaliações da função motora e exames histopatológicos da medula espinhal e das raízes nervosas foram realizados nos dias 3, 7 e 21 do estudo. Os cortes da medula espinhal foram avaliados por microscopia de luz para vacuolização do funículo axonal dorsal, perda de mielina axonal, cromatólise neuronal, neurite, inflamação, aderências e fibrose das meninges.

Resultados: Em todos os grupos, os ratos exibiram resposta normal ao teste de pinça (pontuação = 0) e marcha normal em cada tempo observado (escore de avaliação da função motora = 1). A neurotoxicidade foi maior com os tratamentos nos dias 3 e 7 que no dia 21 (2, 3, 0, $p=0,044$; 2, 5, 0, $p=0,029$, respectivamente). No dia 7, os escores totais refletindo o dano neuronal foram maiores no grupo com 800 μg que nos grupos com 100 μg e controle (5, 3, 0, $p=0,048$, respectivamente).

Conclusão: A administração intratecal de (S)-(+)-cetoprofeno causou alterações neurohistopatológicas dose-dependentes em ratos nos dias 3 e 7 após a aplicação sugerindo que o (S)-(+)-cetoprofeno não deve ser administrado por via intratecal.

© 2019 Sociedade Brasileira de Anestesiologia. Publicado por Elsevier Editora Ltda. Este é um artigo Open Access sob uma licença CC BY-NC-ND (<http://creativecommons.org/licenses/by-nc-nd/4.0/>).

Introduction

Postoperative pain is caused by tissue injury and the disruption of physiological homeostasis.¹ Depending on the type of surgery, 75% of patients suffer from postoperative pain and 80% of these report severe pain.² Opioids are often used as postoperative analgesics, but cause side effects such as respiratory depression, sedation, nausea, vomiting, and pruritus.³ Multimodal analgesia, which often includes Non Steroidal Anti-Inflammatory Drugs (NSAIDs), decreases opioid doses and side effects and increases the pain relief through additive or synergistic effects.^{3,4}

However, systemically administered doses of NSAIDs cause side effects, including gastric ulceration, reduced renal blood flow, and inhibited platelet function. Alternatively, NSAIDs can be administered intrathecally with 100–300 fold lower doses, potentially leading to reduced side effects.^{5,6} Other studies have indicated that (S)-(+)-Ketoprofen (Dex-ketoprofen) has fewer side effects and a higher analgesic activity than conventional NSAIDs.^{7,8}

Experimental animal models used in pain studies have demonstrated that the intrathecal use of NSAIDs causes an increase in cyclooxygenase activity in the spinal cord and a decrease in the perception of pain. However, a limited

number of studies have been performed on human beings.⁹ In healthy volunteers, Eisenach et al.¹⁰ found that increasing doses of intrathecal ketorolac (0.25–2 mg) did not have a significant impact on the response to acute noxious heat stimuli in normal skin. There were no neurological or cardiorespiratory side effects, although there was a small, but statistically significant, reduction in the heart rate for 1 h after the ketorolac injection.¹⁰ In the study on healthy volunteers, it was also found that 2 mg of intrathecal ketorolac exerted minimal effects on acute nociceptive pain and chronic neuropathic pain, although the drug was more effective in pain models with inflammatory and hypersensitivity components, such as postoperative pain and arthritis.⁹ In both studies, the only side effect was a mild headache, while no long-term side effects were seen for up to 6 months after termination of the study. In a study by the same group on patients with chronic pain, increased doses of intrathecal ketorolac (0.5–2.0 mg) caused a decrease in pain scores, and mild or moderate headache and nausea were the most frequently encountered side effects.¹¹ Although there are few side effects associated with NSAIDs, further studies using repeated doses or formulations of these drugs containing preservatives are needed before NSAIDs can be introduced into routine clinical practice. The non-selective NSAID (S)-(+)-Ketoprofen inhibits cyclooxygenase-1 and cyclooxygenase-2, leading to reduced peripheral sensitization and nociceptive responses from inflamed areas and central inhibition of wind-up curves that are mediated by spinal cord nociceptive neurons.^{7,12} According to Cabré et al.,¹³ (S)-(+)-Ketoprofen is more antinociceptive than (R)-(–)-Ketoprofen; the researchers attributed the difference between the enantiomers to stereoselectivity.

Considering the effectiveness of (S)-(+)-Ketoprofen, its intrathecal use could be a better choice for pain management, if it has no neurotoxicity. However, the neurotoxicity of (S)-(+)-Ketoprofen was not evaluated in the earlier studies. Therefore, the aim of this study was to clinically and histopathologically evaluate the potential neurotoxicity of different doses of intrathecal (S)-(+)-Ketoprofen in rats.

Methods

Animals

The experimental protocol of this study was reviewed and approved by the Animal Care and Use Committee (Ethical Committee Number 2013/28). Male Sprague–Dawley rats ($n = 27$), 12–16 weeks of age and weighing 250–300 g (Experimental Animals and Application Research Center), were kept in individual cages under 12 h of light and 12 h of dark cycles at 20–22 °C room temperature, with free access to water and food. Body weight was measured before the intrathecal drug injection (baseline) and 3, 7, and 21 days after injection.

Exclusion criteria

Rats were excluded if they displayed abnormalities in sensory or motor function, behavioral or neurological deficits during the three-day interval between catheter placement and intrathecal injection of (S)-(+)-Ketoprofen. They were also excluded if they developed an infection

during follow-up. Also excluded were rats with an incorrectly placed catheter tip, which was discovered during subsequent laminectomy. Rats with an incorrectly placed catheter that was discovered as no paralysis was seen in the hind legs 30 s after lidocaine hydrochloride administration through the catheter, the day following catheter placement, were also excluded from the study. New rats were substituted for the excluded rats.

Intrathecal delivery

For the surgical procedure, the rats were given an intraperitoneal injection of ketamine (80–100 mg.kg⁻¹) and xylazine (5–10 mg.kg⁻¹), which allowed the rats to continue breathing spontaneously. The intrathecal catheter was placed through the atlanto-occipital membrane using the method described by Yaksh and Rudy¹⁴ and modified by Korkmaz et al.¹⁵ First, the rats were anesthetized and then fixed in a prone position using a stereotactic surgical device. The skin was sterilized and an incision was made in the occipitocervical region to expose the atlanto-occipital membrane. After cerebrospinal fluid was observed through a small incision in the membrane, an ALZET® catheter (PU-10 28G, Durect Corporation, Cupertino, CA, USA) was introduced 8 cm, caudally. The muscle and subcutaneous tissue were sutured, and the external catheter tip was fixed to the skin. The catheter was flushed with 10 µL of sterile saline, and the tip was then covered with tape.

Antibiotherapy using 40 mg.kg⁻¹.day⁻¹ intraperitoneal cefazolin was administered to each rat beginning the day before surgery and continuing for 6 days. After the rats recovered from anesthesia, they were placed in individual cages and monitored.

To verify the location of the catheter, 10 µL of 2% lidocaine hydrochloride (200 µg) followed by 10 µL of sterile saline were administered through the catheter the day after surgery. Bilateral motor paralysis in the hind legs within 30 s after the injection indicated that the catheter was placed correctly. The rats were then monitored for 3 days for irregular gait, spinal deformity and behavioral abnormalities.

Drug preparation

A mixture of 200 mg (S)-(+)-Ketoprofen (Sigma–Aldrich, Saint Louis, MO, USA), 3 mL preservative-free sterile water, and 1 M NaOH (0.2 mL) was prepared for a total volume of 5 mL with a concentration of 40 µg.µL⁻¹ and a pH ranging from 7 to 7.4.

The rats were distributed randomly to one of the three study groups:

- Group C (Control Group) – 20 µL of sterile water ($n = 9$);
- Group 1 – 100 µg (S)-(+)-Ketoprofen 2.5 µL mixture and 17.5 µL of sterile water ($n = 9$);
- Group 2 – 800 µg (S)-(+)-ketoprofen 20 µL mixture ($n = 9$).

After the drug application, sterile saline (10 µL) was injected into the catheter. All drug and sterile saline applications were made with an intrathecal catheter syringe (Hamilton Bonaduz AG, Bonaduz, Switzerland).

Neurofunctional evaluation

To evaluate nervous system function at various levels in rats, we performed motor function evaluations and pinch-toe tests on days 3, 7 and 21 post-injection by one investigator blinded to the experimental procedure.

Pinch-toe tests

Pinch-toe tests were performed by applying pressure across dorsal surfaces of the lateral toe using blunt surgical forceps for a maximum of 6 s. Compressive pinch-toe tests were applied at 5 min intervals up to 3 times. Under these conditions, deep mechanical noxious stimuli are sufficient to cause reflexive motions but do not cause injury to the rats. Nocifensive reactions were scored from 0 to 3 based on withdrawal reflexes, attempts to bite the forceps, and vocalization. Nocifensive scores were generated as described by Bajrovic et al.¹⁶ with some modifications. According to this scoring system, a score of 0 is considered normal and is assigned if the rat has strong vocalization, reflexive limb withdrawal, and bites the forceps within s of the hind limb being pinched. A score of 1 indicates mild impairment of responses, a score of 2 corresponds with moderate impairment, and a score of 3 is given to rats that fail to respond. Scores of ≥ 1 are considered abnormal and indicative of motor and sensory nerve damage.

Motor function evaluations

Motor functions were evaluated according to gait and hind limb positioning, and were graded using scores from 1 to 4. To evaluate motor nerve disorders, we used the scores described by Chataniet et al.¹⁷ with some modifications as follows: 1 – Normal gait and no motor paresis; 2 – Normal gait but mild irregularity of hind limbs, such as plantar flexion of the toes; 3 – Mildly disordered gait and/or inversion of the hind paw and 4 – Incorrect foot position with significant limping. Scores of ≥ 2 were considered indicative of motor nerve injury.

Histopathological evaluation

Three rats in each group were euthanized using inhalation anesthesia and evaluated on days 3rd, 7th and 21st after injection. The left ventricle was cannulated and perfused with 50 mL phosphate buffer (0.2M), followed by 400 mL of 4% paraformaldehyde. Bilateral laminectomies were performed (Fig. 1).

Three tissue blocks were prepared from specimens excised from the level of the catheter tip, and 0.5 cm rostral and 0.5 cm caudal to the catheter tip. Four slides containing sections of 5 μ m thickness were prepared from each tissue block. The sections were stained with hematoxylin and eosin, Luxol fast blue, and neurofilament stain (monoclonal mouse anti-human neurofilament protein, clone 2F11; Dako, Glostrup, Denmark).^{18,19}

A histopathological evaluation was made in 3 areas: neuronal damage (chromatolysis, gliosis, and neuritis); meningeal damage (inflammation, adhesion, and fibrosis);

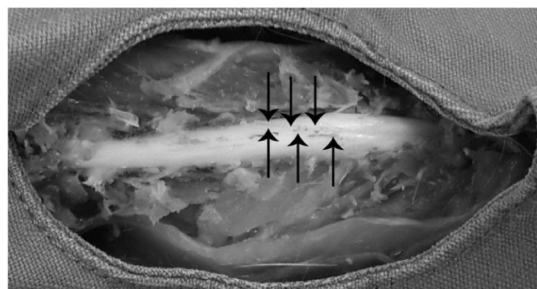

Figure 1 Spinal cord. Slender arrows indicate PU-10 catheter on the dorsal side of the lower part of the spinal cord.

and axonal damage (vacuolation of dorsal funiculus, and myelin loss). Each area was semiquantitatively given a score of 0 (no damage), 1 (moderate damage < 50%), or 2 (severe damage > 50%), as suggested by Kim et al.¹⁷ The scores were then totaled (min = 0 and max = 6). To prevent bias, the histopathological changes were analyzed by two pathologists who were blinded to the study.

Statistical analysis

The data were analyzed using the Statistical Package for the Social Sciences Version 20.0 software (IBM SPSS Statistics Inc., IBM Corp., Armonk, NY, USA). Intragroup and intergroup comparisons were analyzed using Kruskal–Wallis one-way ANOVA on ranks and this was followed by Dunn's multiple comparison test. The parameters were expressed as median (min–max) values. A $p < 0.05$ was considered significant.

Results

In total, four rats died among all the groups during the catheterization of the intrathecal space due to complications, such as spinal compression or injury, and subarachnoid hemorrhage.²⁰ Three rats pulled out the catheter the day after surgery, and were excluded.

The remaining rats exhibited normal behavior during the 3 day interval between catheter placement and (S)-(+)-Ketoprofen administration. They also gained weight normally over the course of the study.

Neurofunctional evaluation

Following the administration of (S)-(+)-Ketoprofen, all the rats responded normally to the pinch-toe tests, with scores being zero for each of the groups and displayed typical motor functions at day 3, 7 and 21, with a score of 1, for all the groups. All rats showed normal evasive responses (score of 0) in pinch-toe tests and had normal gait patterns without hind limb deformities in motor function evaluations (score of 1) at all time points (Table 1). Thus, data from pinch-toe tests and motor function evaluations were not analyzed statistically.

Table 1 Pinch-toe tests and motor function evaluations after intrathecal injections.

Days after intrathecal injection		Groups	Median (min–max)
3rd day (n = 9)	Pinch-toe test score ^a	Group C	0 (0–0)
		Group 1	0 (0–0)
		Group 2	0 (0–0)
	Motor function evaluation score ^b	Group C	1 (1–1)
		Group 1	1 (1–1)
		Group 2	1 (1–1)
7th day (n = 9)	Pinch-toe test score	Group C	0 (0–0)
		Group 1	0 (0–0)
		Group 2	0 (0–0)
	Motor function evaluation score	Group C	1 (1–1)
		Group 1	1 (1–1)
		Group 2	1 (1–1)
21st day (n = 9)	Pinch-toe test score	Group C	0 (0–0)
		Group 1	0 (0–0)
		Group 2	0 (0–0)
	Motor function evaluation score	Group C	1 (1–1)
		Group 1	1 (1–1)
		Group 2	1 (1–1)

All rats had normal responses in Pinch-toe tests and motor function evaluations at all time points. Thus, the ensuing data were not analyzed statistically.

^a Pinch-toe test scores were graded on a 4 point scale as follows: 0, normal response with strong vocalization, reflexive limb withdrawal immediately after pinching, and biting of forceps within 6 s of the hind limb being pinched; 1, mildly impaired response; 2, moderately impaired response and 3, no response. Scores of 1 and higher are considered abnormal and indicative of motor and sensory nerve damage.

^b Motor function scores were graded on a 4 point scale as follows: 1, normal gait with no motor paresis; 2, normal gait with mild irregularity of the hind limbs, such as plantar flexion of the toes; 3, mildly disordered gait and/or inversion of the hind paw and 4, incorrect foot position with significant limping. Scores of 2 and higher were considered indicative of motor nerve injury.

Group C (Control Group): 20 µL of sterile water.

Group 1: 100 µg (S)-(+)-Ketoprofen 2.5 µL mixture + 17.5 µL of sterile water.

Group 2: 800 µg (S)-(+)-Ketoprofen (20 µL mixture).

Histopathological evaluation

There were no incidences of bleeding, necrosis, or non-central nervous system tissue damage during the laminectomies and spinal cord excisions. Both the dosage groups (100 µg and 800 µg) showed significantly higher total scores from the combined categories of central nervous system damage on day 3 and day 7 than on day 21 ($p < 0.05$) (Table 2). No statistically significant intra-group differences were detected in meningeal inflammation, axonal damage, or neuronal damage among Groups 1 and 2 and also in the controls throughout the study (Table 3).

Inter-group comparisons between the dosage groups revealed no statistically significant differences in meningeal inflammation, axonal damage, or neuronal damage, and the total scores were the same on day 3 (Table 4). However, on day 7, the total scores were significantly higher in Group 2 compared with Group 1 and the Control Group ($p = 0.048$). On day 21, the total score was significantly lower in Group 1 than in Group 2 or the Control Group ($p = 0.044$) (Table 5) (Fig. 2A–H).

Discussion

Considering the potential of intrathecal (S)-(+)-Ketoprofen in pain management, we evaluated this drug's neurotoxicity

Table 2 Intragroup comparisons of total scores.

	Days after intrathecal injection	Median (min–max)	<i>p</i> -Value
Group C (n = 9)	3rd day	0 (0–1)	0.87
	7th day	0 (0–1)	
	21st day	2 (1–2)	
Group 1 (n = 9)	3rd day	2 (1–3)	0.044
	7th day	3 (2–5)	
	21st day	0 ^a (0–0)	
Group 2 (n = 9)	3rd day	2 (2–3)	0.029
	7th day	5 (3–5)	
	21st day	0 ^a (0–1)	

^a $p < 0.05$ versus corresponding data of days 3 and 7.

Total score was graded from 0 to 6 (0 = minimum, 6 = maximum).

Group C (Control Group): 20 µL of sterile water.

Group 1: 100 µg (S)-(+)-Ketoprofen 2.5 µL mixture + 17.5 µL of sterile water.

Group 2: 800 µg (S)-(+)-Ketoprofen 20 µL mixture.

in rat model, in order to assess its possible clinical application. The present study showed that even though at low and high dose of (S)-(+)-Ketoprofen, a normal response was seen in pinch-toe testing and motor function testing at each

Table 3 Intragroup comparisons of neuropathological findings.

	Type of damage	Days after intrathecal injection	Median (min–max)	p-Value
Group C (n = 9)	Meningeal	3rd day	0 (0–1)	0.67
		7th day	1 (0–1)	
		21st day	0 (0–1)	
	Axonal	3rd day	1 (0–1)	0.67
		7th day	1 (0–1)	
		21st day	1 (0–1)	
	Neuronal	3rd day	0 (0–0)	0.64
		7th day	1 (0–1)	
		21st day	1 (0–1)	
Group 1 (n = 9)	Meningeal	3rd day	0 (0–0)	0.20
		7th day	0 (0–2)	
		21st day	2 (0–2)	
	Axonal	3rd day	1 (0–1)	1
		7th day	1 (0–2)	
		21st day	2 (0–2)	
	Neuronal	3rd day	1 (0–1)	1
		7th day	1 (0–1)	
		21st day	1 (0–1)	
Group 2 (n = 9)	Meningeal	3rd day	0 (0–1)	1
		7th day	0 (0–1)	
		21st day	1 (0–1)	
	Axonal	3rd day	0 (0–1)	0.56
		7th day	0 (0–0)	
		21st day	0 (0–1)	
	Neuronal	3rd day	0 (0–0)	0.64
		7th day	0 (0–0)	
		21st day	0 (0–0)	

Degree of meningeal inflammation, neuronal damage, and axonal damage were graded on a 3 point scale as follows: 0 = none, 1 = moderate, 2 = severe.

Group C (Control Group): 20 μ L of sterile water.

Group 1: 100 μ g (S)-(+)-Ketoprofen 2.5 μ L mixture + 17.5 μ L of sterile water.

Group 2: 800 μ g (S)-(+)-Ketoprofen 20 μ L mixture.

observation time point, there was neurotoxicity in both test groups on days 3 and 7 than on day 21. The observed neurotoxicity on day 7, in terms of meningeal inflammation, axonal damage, and neuronal damage was much higher in rats receiving high dose (800 μ g) of (S)-(+)-Ketoprofen than in the controls or the low dose (100 μ g) (S)-(+)-Ketoprofen receiving rats, indicating dose dependent neurotoxicity.

Nociceptive stimulation markedly increases the expression of spinal prostaglandins, which augment pain signal transmission in the spinal cord and cause central sensitization.²¹ Intrathecal treatments allow direct administration of analgesic to the CSF, thus circumventing the blood-brain barrier and providing superior analgesic effects.²² Accordingly, intrathecally administered cyclooxygenase inhibitors strongly reduce hypersensitivity compared with peripheral formalin injections, and suppress delayed hypersensitivity to mechanical stimuli following fentanyl exposure.^{5,23}

While some NSAIDs, such as indomethacin, acetaminophen, tolmetin, etodolac, ketorolac and oxaprozin, are able to activate several neuroprotective mechanisms including inhibition of inflammatory prostaglandin synthesis, other NSAIDs such as diclofenac and celecoxib, do not produce this

neuroprotective effect, and may even have neurotoxic effects on the central nervous system.²⁴

Intrathecal drug application of NSAIDs can injure the spinal cord and nerve roots, dose dependently.^{25,26} The damage is related to the concentration of the drug and the exposure time and likely include diminished antioxidant effects, arrested cell cycles, increased intracellular accumulation of toxins, inhibited multidrug resistance, increased production of reactive oxygen species, and increased apoptosis.²⁴ Pain and loss of motor function and sensation result from gliosis, inflammation, and damage to the myelin sheath, and other neuron damage.²⁵

The neurotoxic effects of intrathecally administered drugs is dependent on the type of drug and dosage employed, and the effects may be more subtle and not always be evident in physical pain or motor function tests. Canduz et al.²⁷ demonstrated the neurotoxic effects caused by three different doses of lornoxicam delivered through an epidural catheter. Yaksh et al.²⁶ delivered ketorolac infusions to dogs through an intrathecal catheter for 28d, and administered intrathecal ketorolac injections to rats 4 times a day for 6d, and found no signs of toxicity in the spinal cord or the nerve roots. Guevara-López et al.¹⁸ infused indo-

Table 4 Intergroup comparisons of neuropathological findings.

Days after intrathecal injection	Type of damage	Groups	Median (min–max)	p-Value
3rd day (n = 9)	Meningeal	Group C	0 (0–1)	0.202
		Group 1	0 (0–0)	
		Group 2	0 (0–1)	
	Axonal	Group C	1 (0–1)	0.396
		Group 1	1 (0–1)	
		Group 2	0 (0–1)	
	Neuronal	Group C	0 (0–0)	0.801
		Group 1	1 (0–1)	
		Group 2	0 (0–0)	
7th day (n = 9)	Meningeal	Group C	1 (0–1)	0.102
		Group 1	0 (0–2)	
		Group 2	0 (0–1)	
	Axonal	Group C	1 (0–1)	0.202
		Group 1	1 (0–2)	
		Group 2	0 (0–0)	
	Neuronal	Group C	1 (0–1)	0.202
		Group 1	1 (0–1)	
		Group 2	0 (0–0)	
21st day (n = 9)	Meningeal	Group C	0 (0–1)	0.670
		Group 1	2 (0–2)	
		Group 2	1 (0–1)	
	Axonal	Group C	1 (0–1)	0.396
		Group 1	2 (0–2)	
		Group 2	0 (0–1)	
	Neuronal	Group C	1 (0–1)	0.211
		Group 1	1 (0–1)	
		Group 2	0 (0–0)	

Degree of meningeal inflammation, neuronal damage and axonal damage were graded on a 3 point scale as follows: 0 = none, 1 = moderate, 2 = severe.

Group C (Control Group): 20 μ L of sterile water.

Group 1: 100 μ g (S)-(+)-Ketoprofen 2.5 μ L mixture + 17.5 μ L of sterile water.

Group 2: 800 μ g (S)-(+)-Ketoprofen 20 μ L mixture.

Table 5 Intergroup comparisons of total scores.

Days after intrathecal injection		Groups	Median (min–max)	p-Value
3rd day (n = 9)	Total score	Group C	0 (0–1)	0.72
		Group 1	2 (1–3)	
		Group 2	2 (2–3)	
7th day (n = 9)	Total score	Group C	0 (0–1)	0.048
		Group 1	3 (2–5)	
		Group 2	5 ^a (3–5)	
21st day (n = 9)	Total score	Group C	1 (0–1)	0.044
		Group 1	0 ^b (0–0)	
		Group 2	0 (0–1)	

^a $p < 0.05$ vs. corresponding data of Group C and Group 1.

^b $p < 0.05$ vs. corresponding data of Group C and Group 2.

Total score was graded from 0 to 6 (0 = minimum, 6 = maximum).

Group C (Control Group): 20 μ L of sterile water.

Group 1: 100 μ g (S)-(+)-Ketoprofen 2.5 μ L mixture + 17.5 μ L of sterile water.

Group 2: 800 μ g (S)-(+)-Ketoprofen 20 μ L mixture.

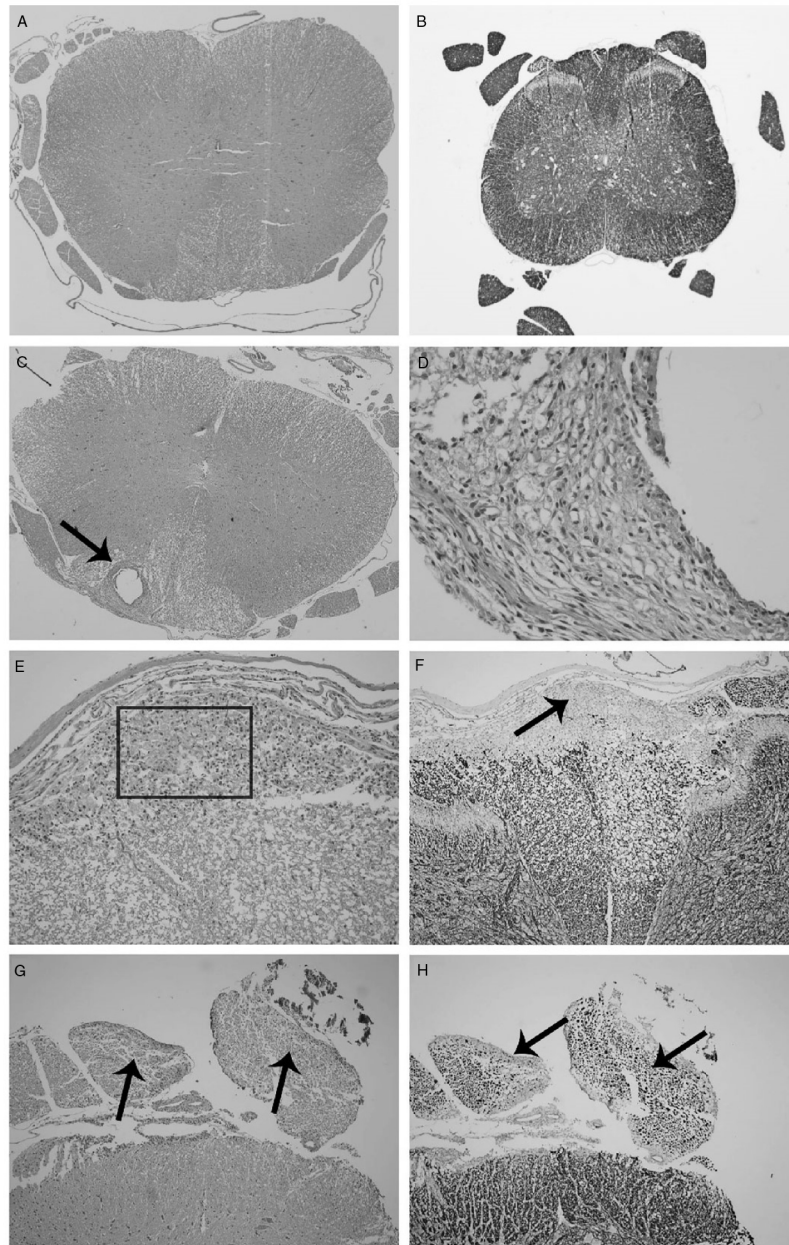


Figure 2 A–H. The light micrographic findings of rat spinal cord after subarachnoid administration of 100 μg (Group 1) and 800 μg (Group 2) (S)-(+)-Ketoprofen. (A) Group C (day 3): Spinal cord in normal histomorphology (hematoxylin and eosin stain, original magnification 40 \times). (B) Immunohistochemical staining with neurofilament stain, 40 \times . (C) Group 1 (day 7): Histiocytic inflammation and cystic formation in the dorsal funiculus of the spinal cord (indicated by the slender arrow), (hematoxylin and eosin stain, original magnification 40 \times). (D) A closer look at the section in (a) reveals that the inflammation consists of histiocytes, eosinophils, and neutrophils (hematoxylin and eosin stain, 400 \times). (E) Group 2 (day 7): Inflammation in the dorsal region of the spinal cord (indicated by the square), (hematoxylin and eosin stain, 200 \times). (F) Group 2 (day 7): Immunohistochemical study with neurofilament protein demonstrates unstained inflammatory areas in the dorsal region (indicated by the slender arrow), (immunohistochemical staining with neurofilament stain, 100 \times). (G) Group 2 (day 7): Axonal vacuolization (indicated by slender arrows), (hematoxylin and eosin, 100 \times). (H) Group 2 (day 7): Axonal degeneration and decreased myelin (indicated by slender arrows), (immunohistochemical staining with neurofilament stain, 100 \times).

methacin to guinea pigs through an intrathecal catheter for 14d and were unable to detect neurotoxicity in the spinal cord.

In the current study, both the spinal cord and nerve roots were evaluated, and we found that

neurotoxicity occurred in a dose-dependent manner with (S)-(+)-Ketoprofen. Ossipov et al.²⁸ reported that a 100 μg dose of intrathecal (S)-(+)-Ketoprofen demonstrated a 50% antinociceptive effect in a formalin test. Therefore, in the present study, 100 μg was used as

one of the doses. Because the maximum water-soluble dose of (S)-(+)-Ketoprofen is $40.76 \text{ mg}\cdot\text{mL}^{-1}$,²⁹ the other dose used in this study was $800 \mu\text{g}$. The maximum recommended parenteral dose of (S)-(+)-Ketoprofen (as dexketoprofen trometamol) for adult humans is $150 \text{ mg}\cdot\text{d}^{-1}$.³⁰ Intrathecal doses of $100 \mu\text{g}$ and $800 \mu\text{g}$ of (S)-(+)-Ketoprofen in rats are equivalent to parenteral doses of 2,800 mg and 22,400 mg, respectively, in adult human beings. The recommended NSAID dose by the intrathecal route is about 1/100th of that required for parenteral administration.¹⁹

Kim et al.¹⁹ reported that a single dose of parecoxib, which is a cyclooxygenase-2 inhibitor, demonstrated no neurotoxic effects. However, the study did not include a histopathological examination of the nerve roots; only the spinal cord was assessed. Previous animal studies indicate that intrathecal drugs cause neurotoxicity in different regions. For example, neurotoxic lesions that are induced by some intrathecal drugs are mainly observed in the nerve roots. This is particularly the case for local anesthetics, because their primary site of action is the dorsal root ganglia neuron.^{31,32} Neurotoxic changes induced by other intrathecal drugs, including fentanyl and diclofenac, also occur in the spinal cord.^{33,34} Therefore, in this study, histopathological examinations of the spinal cord and the nerve roots were performed.

In this study, there was no apparent association of neurological injury with motor or sensory loss as observed in the pinch-toe test or during motor function assessment. However, the histopathological damage score, which was determined by the total scores for the combined categories of damage, was higher on day 3 and day 7 than it was on day 21, which was interpreted as acute tissue damage caused by (S)-(+)-Ketoprofen that had healed over time. The dose-dependent increase in damage suggested that there was a dose-related toxic effect. Even though, there were no remarkable motor and sensory function deficits, histopathological damage was obvious, indicating potential low level of neurotoxicity, which may be because of the very low scores (0 or 1) for meningeal inflammation, and neuronal and axonal damage throughout the study.

The most important limitation of our study was our inability to evaluate the distribution of (S)-(+)-Ketoprofen in the cerebrospinal fluid. Additional information might be obtained by evaluating neuronal structures with an electron microscope.

Conclusion

Intrathecal (S)-(+)-Ketoprofen administration caused dose-dependent neurohistopathological changes in rats. These changes were evident on day 3 and day 7, but declined by day 21. Although the presence of neuronal lesions did not correlate with neurological symptoms, it is impossible to conclude that the drug is not neurotoxic. Therefore, intrathecal administration of (S)-(+)-Ketoprofen cannot be recommended for use in animals and humans.

Funding

This study was supported by the Commission Presidency of Scientific Research Projects of Ondokuz Mayıs University, Samsun, Turkey, under project number PYO.TIP.1901.13.03.

Conflicts of interest

The authors declare no conflicts of interest.

Acknowledgements

We would like to show our gratitude to Fatih Ilkaya, M.D., Ondokuz Mayıs University, Department of Pharmacology and Hasan Guzel, M.D., Ondokuz Mayıs University, Department of Pharmacology for their assistance in data collection. We also thank Ali Haydar Sahinoglu, M.D., Ondokuz Mayıs University, Department of Anesthesiology for comments that greatly improved the manuscript.

References

1. Ceyhan D, Gulec MS. Is postoperative pain only a nociceptive pain? *Agri*. 2010;22:47–52.
2. Gan TJ, Habib AS, Miller TE, et al. Incidence, patient satisfaction, and perceptions of post-surgical pain: results from a US national survey. *Curr Med Res Opin*. 2014;30:149–60.
3. Chou R, Gordon DB, de Leon-Casasola OA, et al. Management of postoperative pain: a clinical practice guideline from the American Pain Society, the American Society of Regional Anesthesia and Pain Medicine, and the American Society of Anesthesiologists' Committee on Regional Anesthesia, Executive Committee, and Administrative Council. *J Pain*. 2016;17:131–57.
4. Yucel E, Kol IO, Duger C, et al. Ilioinguinal-iliohypogastric nerve block with intravenous dexketoprofen improves postoperative analgesia in abdominal hysterectomies. *Rev Bras Anesthesiol*. 2013;63:334–9.
5. Malmberg AB, Yaksh TL. Antinociceptive actions of spinal nonsteroidal anti-inflammatory agents on the formalin test in the rat. *J Pharmacol Exp Ther*. 1992;263:136–46.
6. Zhu X, Conklin D, Eisenach JC. Cyclooxygenase-1 in the spinal cord plays an important role in postoperative pain. *Pain*. 2003;104:15–23.
7. Mauleon D, Artigas R, Garcia ML, et al. Preclinical and clinical development of dexketoprofen. *Drugs*. 1996;52 Suppl 5:24–46.
8. Barbanoj MJ, Antonijoan RM, Gich I. Clinical pharmacokinetics of dexketoprofen. *Clin Pharmacokinet*. 2001;40:245–62.
9. Eisenach JC, Curry R, Tong C, et al. Effects of intrathecal ketorolac on human experimental pain. *Anesthesiology*. 2010;112:1216–24.
10. Eisenach JC, Curry R, Hood DD, et al. Phase I safety assessment of intrathecal ketorolac. *Pain*. 2002;99:599–604.
11. Eisenach JC, Curry R, Rauck R, et al. Role of spinal cyclooxygenase in human postoperative and chronic pain. *Anesthesiology*. 2010;112:1225–33.
12. Mazarío J, Gaitan G, Herrero JF. Cyclooxygenase-1 vs. cyclooxygenase-2 inhibitors in the induction of antinociception in rodent withdrawal reflexes. *Neuropharmacology*. 2001;40:937–46.
13. Cabre F, Fernandez MF, Calvo L, et al. Analgesic, antiinflammatory, and antipyretic effects of S(+)-Ketoprofen in vivo. *J Clin Pharmacol*. 1998;38:35–10S.

14. Yaksh TL, Rudy TA. Chronic catheterization of the spinal subarachnoid space. *Physiol Behav.* 1976;17:1031–6.
15. Korkmaz HA, Maltepe F, Erbayraktar S, et al. Antinociceptive and neurotoxicologic screening of chronic intrathecal administration of ketorolac tromethamine in the rat. *Anesth Analg.* 2004;98:148–52.
16. Bajrovic F, Sketelj J. Extent of nociceptive dermatomes in adult rats is not primarily maintained by axonal competition. *Exp Neurol.* 1998;150:115–21.
17. Chatani K, Kawakami M, Weinstein JN, et al. Characterization of thermal hyperalgesia, c-fos expression, and alterations in neuropeptides after mechanical irritation of the dorsal root ganglion. *Spine.* 1995;20:277–90.
18. Guevara-Lopez U, Covarrubias-Gomez A, Gutierrez-Acar H, et al. Chronic subarachnoid administration of 1-(4chlorobenzoyl)-5methoxy-2methyl-1H-indole-3 acetic acid (indomethacin): an evaluation of its neurotoxic effects in an animal model. *Anesth Analg.* 2006;103:99–102.
19. Kim YH, Lee PB, Park J, et al. The neurological safety of epidural parecoxib in rats. *Neurotoxicology.* 2011;32:864–70.
20. Hou Y, Wang L, Gao J, et al. A modified procedure for lumbar intrathecal catheterization in rats. *Neurol Res.* 2016;38:725–32.
21. Chen L, Yang G, Grosser T. Prostanoids and inflammatory pain. *Prostaglandins Other Lipid Mediat.* 2013;104–105:58–66.
22. Dodou K. Intrathecal route of drug delivery can save lives or improve quality of life. *Pharm J.* 2012;289:501.
23. Kang YJ, Vincler M, Li X, et al. Intrathecal ketorolac reverses hypersensitivity following acute fentanyl exposure. *Anesthesiology.* 2002;97:1641–4.
24. Aygun D, Kaplan S, Odaci E, et al. Toxicity of non-steroidal anti-inflammatory drugs: a review of melatonin and diclofenac sodium association. *Histol Histopathol.* 2012;27:417–36.
25. Hodgson PS, Neal JM, Pollock JE, et al. The neurotoxicity of drugs given intrathecally (spinal). *Anesth Analg.* 1999;88:797–809.
26. Yaksh TL, Horais KA, Tozier N, et al. Intrathecal ketorolac in dogs and rats. *Toxicol Sci.* 2004;80:322–34.
27. Canduz B, Aktug H, Mavioglu O, et al. Epidural lornoxicam administration – innocent. *J Clin Neurosci.* 2007;14:968–74.
28. Ossipov MH, Jerussi TP, Ren K, et al. Differential effects of spinal (R)-Ketoprofen and (S)-Ketoprofen against signs of neuropathic pain and tonic nociception: evidence for a novel mechanism of action of (R)-ketoprofen against tactile allodynia. *Pain.* 2000;87:193–9.
29. Shohin IE, Kulinich JI, Ramenskaya GV, et al. Evaluation of in vitro equivalence for drugs containing BCS class II compound ketoprofen. *Dissolut Technol.* 2011;18:26–9.
30. Rodriguez MJ, Arbos RM, Amaro SR. Dexketoprofen trometamol: clinical evidence supporting its role as a painkiller. *Expert Rev Neurother.* 2008;8:1625–40.
31. Takenami T, Yagishita S, Murase S, et al. Neurotoxicity of intrathecally administered bupivacaine involves the posterior roots/posterior white matter and is milder than lidocaine in rats. *Reg Anesth Pain Med.* 2005;30:464–72.
32. Doan LV, Eydlin O, Piskoun B, et al. Despite differences in cytosolic calcium regulation, lidocaine toxicity is similar in adult and neonatal rat dorsal root ganglia in vitro. *Anesthesiology.* 2014;120:50–61.
33. Abut YC, Turkmen AZ, Midi A, et al. Neurotoxic effects of levobupivacaine and fentanyl on rat spinal cord. *Rev Bras Anesthesiol.* 2015;65:27–33.
34. Ozdogan L, Ayerden T, Ornek D, et al. The neurotoxic effect of intrathecal diclofenac sodium in rats. *Kafkas Univ Vet Fak.* 2011;17:309–14.