



REVISTA BRASILEIRA DE ANESTESIOLOGIA

Publicação Oficial da Sociedade Brasileira de Anestesiologia
www.sba.com.br



CLINICAL INFORMATION

Chronic hepatothorax due to right diaphragmatic rupture: an anesthetic challenge in a rare case



Maria Teresa Rincón Vieira Lugarinho-Monteiro*, Luciane Pereira, Carlos Seco

Serviço de Anestesiologia do Centro Hospitalar e Universitário de Coimbra, Coimbra, Portugal

Received 20 May 2015; accepted 17 August 2015

Available online 25 November 2016

KEYWORDS

Hepatotorax;
Anesthesia;
Diaphragmatic injury

Abstract

Background: Diaphragmatic rupture is an uncommon condition, with 90% of ruptures occurring on the left side. However, its incidence on the right side is increasing along with the increase in traffic accidents. Liver herniation may become progressive causing severe atelectasis of the right lung, resulting in impaired respiratory status and hemodynamic changes.

Case report: We report the case of a 40 years old female, ASA III, scheduled for hepatothorax repair that evolved from right diaphragmatic hernia after a car accident when she was 8 years old. Clinically, she had severe restrictive respiratory syndrome caused by the hepatothorax. The anesthetic evaluation was normal, except for the chest x-ray showing elevation of the dome of the right hemidiaphragm without tracheal deviation. Diagnosis was confirmed by CT scan. After liver replacement in the abdominal cavity, a transient increase in central venous pressure, stroke volume index and flow time corrected (35%), and a decrease in systemic vascular resistance were observed. After complete hemodynamic and hepatosplenic stabilization, as well as ventilation, the patient was transferred intubated, under controlled ventilation and monitored, to the liver transplant unit.

Conclusions: Hepatothorax is a rare condition and its repair may represent an anesthetic challenge. After liver replacement in the abdominal cavity during corrective surgery under general anesthesia complications may occur, particularly associated with pulmonary re-expansion. Effective teamwork and careful planning of surgery, between the surgical and anesthetic teams, are the key to success.

© 2016 Sociedade Brasileira de Anestesiologia. Published by Elsevier Editora Ltda. This is an open access article under the CC BY-NC-ND license (<http://creativecommons.org/licenses/by-nc-nd/4.0/>).

* Corresponding author.

E-mail: mteresarvlm@hotmail.com (M.T. Lugarinho-Monteiro).

<https://doi.org/10.1016/j.bjane.2015.08.010>

0104-0014/© 2016 Sociedade Brasileira de Anestesiologia. Published by Elsevier Editora Ltda. This is an open access article under the CC BY-NC-ND license (<http://creativecommons.org/licenses/by-nc-nd/4.0/>).

PALAVRAS-CHAVE

Hepatotórax;
Anestesia;
Lesão diafragmática

Hepatotórax crônico devido à ruptura do diafragma direito: um desafio anestésico em um caso raro**Resumo**

Justificativa: A ruptura diafragmática é uma condição incomum e ocorre em 90% no lado esquerdo. No entanto, a incidência de ruptura à direita tem vindo a aumentar junto com o aumento dos acidentes automobilísticos. A herniação do fígado pode tornar-se progressiva, causar atelectasia grave do pulmão direito, resultar num débil estado respiratório e alterações hemodinâmicas.

Relato de caso: Mulher de 40 anos, estado físico ASA 3, marcada para reparação de hepatotórax que evoluiu de hérnia diafragmática direita, adquirida aos 8 anos, após um acidente automobilístico. Clinicamente apresentava síndrome respiratória restritiva grave, causada pelo hepatotórax. A avaliação anestésica era normal, com exceção da radiografia do tórax, que evidenciava elevação da hemicúpula diafragmática direita, sem desvio traqueal. Diagnóstico foi confirmado por tomografia computadorizada. Depois da recolocação do fígado na cavidade abdominal foram observados um aumento transitório da pressão venosa central, do Stroke Volume Index e Flow Time Corrected (35%) e uma diminuição da resistência vascular sistêmica. Uma vez alcançada a estabilização hemodinâmica geral e hepatoesplênica, bem como da ventilação, a paciente foi transferida entubada, sob ventilação controlada e monitorada para a Unidade de Transplantação Hepática.

Conclusões: O hepatotórax é uma condição rara e a sua correção pode representar um desafio anestésico. Após a recolocação abdominal do fígado, durante uma cirurgia corretiva, sob anestesia geral, podem ocorrer complicações, principalmente as associadas à reexpansão pulmonar. Um trabalho em equipe eficaz e o planejamento cuidadoso da cirurgia, entre as equipes cirúrgica e anestésica, são a chave para o sucesso.

© 2016 Sociedade Brasileira de Anestesiologia. Publicado por Elsevier Editora Ltda. Este é um artigo Open Access sob uma licença CC BY-NC-ND (<http://creativecommons.org/licenses/by-nc-nd/4.0/>).

Introduction

Traumatic diaphragmatic rupture is an uncommon condition. About 90% of cases occur on the left side; although occurrence on the right side has increased due to the increased frequency of traffic accidents.¹ A traumatic right sided diaphragmatic rupture can lead to progressive liver herniation, right lung atelectasis, and promote respiratory and hemodynamic changes.² Hepatothorax repair is always through surgery, which poses major anesthetic challenges, particularly those associated with the possibility of edema due to pulmonary reexpansion, and hemodynamic changes.^{1,2}

Case report

Female patient; 40 years of age; ASA 3 according to the American Society of Anesthesiology (ASA) physical classification; scheduled for an elective hepatothorax repair due to right diaphragm chronic rupture. The onset of this condition occurred after a car crash when she was eight years old and, at that time, the only documented need was a maxillofacial surgery for jaw fracture, without other problems being noticed. Over time, the unidentified diaphragmatic rupture led to the progressive development of a hepatothorax, which led to the gradual onset of dyspnea and the development of a severe respiratory restrictive syndrome.

In the pre-anesthetic evaluation, physical examination revealed only a decrease in breath sounds in the right hemithorax. Preoperative laboratory tests, blood gas analysis, and electrocardiogram showed no significant changes. Echocardiogram showed a good global systolic function with ejection fraction of 62%. Chest X-ray showed an elevation of the right hemidiaphragm, without trachea deviation (Fig. 1), and respiratory function tests revealed a mixed obstructive and restrictive ventilatory pattern with positive bronchodilator response.

The diagnosis was confirmed by thoracic and abdominal computed tomography (CT), which revealed a diaphragmatic hernia, with complete liver herniation in the right hemithorax with periportal edema, pulmonary venovenous shunt, and kinking at portal vein (Fig. 2). She also presented with compression of the right heart chambers by the liver and a contralateral mediastinal shift.

In view of the imaging findings and clinical presentation, a preoperative surgical anesthetic briefing was performed, in which management and procedures were planned taking into account the potential difficulties in dissection, vascular reconstruction, and need for liver autograft transplantation (Fig. 3).

Because it was a chronic injury with several years of evolution, the risk of developing reexpansion pulmonary edema was significant, so double-lumen tube and fiberoptic bronchoscope were available in the operating room.

Balanced general anesthesia was induced with fentanyl (75 μ g), propofol (170 mg), and cisatracurium (14 mg). Sevoflurane and remifentanyl were used in perfusion throughout the surgery for maintenance of anesthesia.

ASA physical status, central venous pressure (after ultrasound guided central venous catheter placement in the right internal jugular vein), invasive blood pressure (left radial artery), depth of anesthesia (bispectral index), diuresis, and intra-abdominal pressure were monitored. Esophageal Doppler was also used during the procedure.

A laparoscopic surgery with a hockey stick type incision was performed. During liver repositioning after placement of the liver in the abdominal cavity, there was a transient increase in central venous pressure, stroke volume index (SVI), and corrected flow time (FTc) of 35%, as well as a decreased systemic vascular resistance (SVR) through the esophageal Doppler. Posteriorly, we proceeded to pulmonary reexpansion maneuvers without complications. At the end, once verified a general hemodynamic stabilization,

a hepatosplenic and also ventilator stable conditions, the surgery was completed, and monitoring during the process of abdominal wall closure showed intra-abdominal pressure always within safety thresholds.

The patient was transferred intubated, under controlled ventilation and monitoring to the liver transplant unit of (LTU) our hospital, as planned.

Because the patient remained hemodynamically stable and with no significant changes on abdominal Doppler, she was extubated 16 h after surgery without complications. The patient was discharged from the LTU five days after surgery.

Discussion

The diaphragm is an extremely important muscle for breathing. Diaphragmatic rupture can lead to functional damage, resulting in the emergence of respiratory distress, atelectasis, and mediastinal shift³; the hemidiaphragmatic right hernia is more unusual than the left.

Right diaphragmatic hernia is a rare lesion, with an incidence of 0.25–1% after blunt abdominal trauma. The diagnosis may be delayed and only determined years after the traumatic event.⁴ Considering the type of the traumatic event, it usually may be associated with other abdominal, pelvic, thoracic, and limb injuries.^{5,6}

Herniation of abdominal organs into the chest cavity may cause damage and changes in herniated organ function; induce cardiocirculatory symptoms, such as arrhythmias; and respiratory system involvement, as in our patient. Clinical presentation may vary widely, depending on the degree of diaphragmatic injury. However, although rarely, the herniation of abdominal organs into the chest cavity may be asymptomatic.^{7,8}

To date, there is not a quick and reliable means of diaphragmatic rupture screening. Previous case reports estimated that chest X-ray identifies only one in three patients and the sensitivity is lower if the patient is intubated.^{9,10} Although focused assessment with sonography in trauma

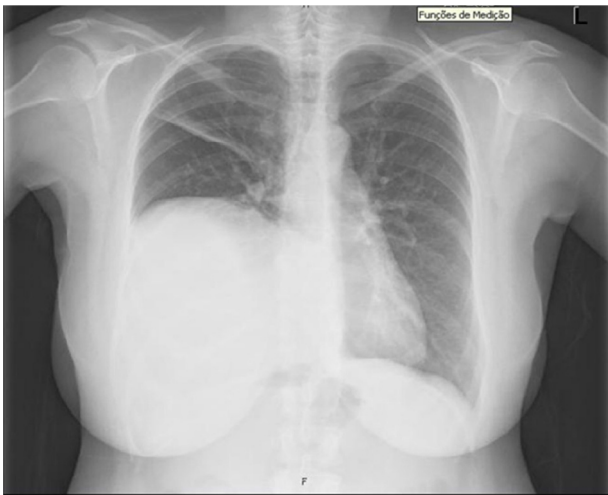


Figure 1 Chest X-ray showing right hemidiaphragm elevation.

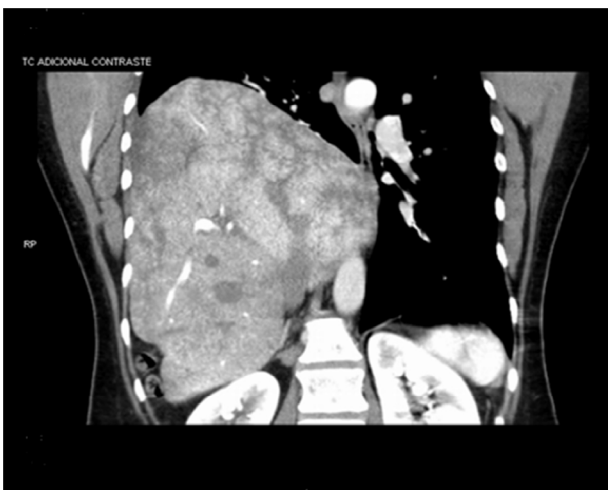

Figure 2 Diagnosis confirmed by axial CT: diaphragmatic hernia with almost complete herniation of the liver into the right hemithorax.

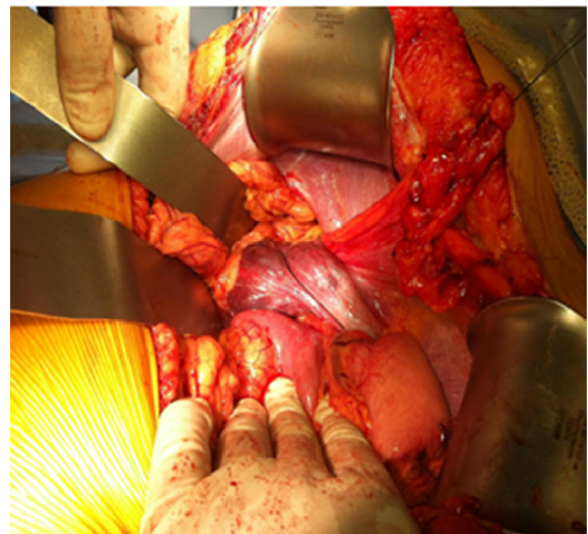


Figure 3 Intraoperative image showing the absence of the liver into the abdominal cavity.

(FAST) is primarily used to detect free intraperitoneal blood, it can occasionally detect a diaphragmatic defect. Axial CT imaging may help in the diagnosis.¹¹ However, some studies report a higher sensitivity to helical CT imaging.¹²

The preoperative diagnosis of diaphragmatic rupture is a challenge, with rates ranging from 30% to 61%.^{10,13}

In this case reported, the patient underwent a complex surgical procedure with the potential for serious complications, so the multidisciplinary approach of the anesthetic-surgical team was essential. After liver replacement into the abdominal cavity, there were the hemodynamic changes already reported, but the team was prepared for an eventual loss of dwelling-place by the organ or vessel injury and progress to a liver autograft, which was not necessary.

Conclusion

We reported a rare case of a patient with a chronic hepatothorax undergoing surgical repair under successful general anesthesia, even after replacing the liver into the abdominal cavity and lung reexpansion.

Chronic hepatothorax is a rare condition, but its repair is associated with important anesthetic and surgical challenges for which this case especially recommends a preoperative meeting between the anesthetic and surgical team, the planning of airway approach, endotracheal intubation, ventilatory pattern, and general and hepatic hemodynamic monitoring.

We believe that this case presentation is useful to recall the existence of this rare condition and warn of the possible anesthetic challenges associated with its repair.

Conflicts of interest

The authors declare no conflicts of interest.

References

1. Igai H, Yokomise H, Kumagai K, et al. Delayed hepatothorax due to right-side traumatic diaphragmatic rupture. *Gen Thorac Cardiovasc Surg.* 2007;55:434–6.
2. Baek SJ, Kim J, Lee SH. Hepatothorax due to a right diaphragmatic rupture related to duodenal ulcer perforation. *World J Gastroenterol.* 2012;18:5649–52.
3. Hwang SW, Kim HY, Byun JH. Management of patients with traumatic rupture of the diaphragm. *Korean J Thorac Cardiovasc Surg.* 2011;44:348–54.
4. Peker Y, Tatar F, Kahya MC, et al. Dislocation of three segments of the liver due to hernia of the right diaphragm: report of a case and review of the literature. *Hernia.* 2007;11:63–5.
5. Tiberio GA, Portolani N, Coniglio A, et al. Traumatic lesions of the diaphragm. Our experience in 33 cases and review of the literature. *Acta Chir Belg.* 2005;1:82–8.
6. Rubikas R. Diaphragmatic injuries. *Eur J Cardiothorac Surg.* 2001;1:53–7.
7. Stagnitti F, Priore F, Corona F, et al. Traumatic lesions of the diaphragm. *G Chi.* 2004;276–82, 8–9.
8. Ould-Ahmed M, Choplain JN, Andre M, et al. Delayed and fortuitous diagnosis of right diaphragmatic rupture during preoperative evaluation. *Ann Fr Anesth Reanim.* 2005;4:416–20.
9. Gelman R, Mirvis SE, Gens D. Diaphragmatic rupture due to blunt trauma: sensitivity of plain chest radiographs. *AJR.* 1991;156:51–7.
10. Shapiro MJ, Heiberg E, Durham RM, et al. The unreliability of CT scans and initial chest radiographs in evaluating blunt trauma induced diaphragmatic rupture. *Clin Radiol.* 1996;51:27–30.
11. Porcelli M, Prychyna O, Rosenthal A, et al. Hepatothorax: a rare outcome of high-speed trauma. *Case Rep Emerg Med.* 2011, <http://dx.doi.org/10.1155/2011/905641>.
12. Nchimi A, Szapiro D, Ghaye B, et al. Helical CT of blunt diaphragmatic rupture. *AJR Am J Roentgenol.* 2005;184:24–30.
13. Hoang AD, De Backer D, Bouazza F, et al. Undiagnosed rupture of right hemidiaphragm–hepatothorax: a case report. *Acta Chir Belg.* 2002;102:353–5.