



REVISTA BRASILEIRA DE ANESTESIOLOGIA

Publicação Oficial da Sociedade Brasileira de Anestesiologia
www.sba.com.br



CLINICAL INFORMATION

Dissection of the wired endotracheal tube's lumen during general anesthesia: a case report



Fabricio Tavares Mendonça*, Leonardo Damasceno Martins, Rodrigo Gazzi, Jose Tadeu dos Santos Palmieri

Centro de Ensino e Treinamento do Hospital de Base do Distrito Federal, Brasília, DF, Brazil

Received 16 January 2015; accepted 11 February 2015
Available online 22 September 2017

KEYWORDS

Airway obstruction;
Complication of intubation;
Obstruction in ventilation

Abstract

Objective: The aim of this study is to report a case of a clinically significant obstruction during mechanical ventilation caused by the dissection of the wired endotracheal tube's lumen during general anesthesia in a pediatric patient.

Case report: A 12-years old patient undergoing general anesthesia for open appendectomy was intubated with a wired endotracheal tube and difficult removal of the guide. After starting the mechanical ventilation, there was increased expiratory fraction of CO₂ and need for increased inspiratory pressure. Chance of complications with higher incidences were raised and treated unsuccessfully. Finally, during patient reintubation, the dissection of the endotracheal tube lumen was observed, and ventilation was restored to normal.

Conclusion: Anesthesia involves numerous possible complications. Suspicion and constant vigilance are essential for early diagnosis and treatment of any threat to the individual integrity. This case is relevant for emphasizing a possible very rare complication related to airway, which can quickly cause hypoxia and irreversible damage. Thus, this case contributes to the detection of this complication more frequently.

© 2015 Sociedade Brasileira de Anestesiologia. Published by Elsevier Editora Ltda. This is an open access article under the CC BY-NC-ND license (<http://creativecommons.org/licenses/by-nc-nd/4.0/>).

PALAVRAS-CHAVE

Obstrução de via aérea;
Complicação na intubação;
Obstrução na ventilação

Dissecção de lúmen de tubo endotraqueal aramado durante anestesia geral: relato de caso

Resumo

Objetivo: Relatar um caso de obstrução à ventilação mecânica clinicamente significativa causada por dissecção do lúmen do tubo endotraqueal aramado durante anestesia geral em um paciente pediátrico.

* Corresponding author.

E-mails: fabriciotmendonca@hotmail.com, fabricio.tavares@me.com (F.T. Mendonça).

Relato: Paciente de 12 anos submetido à anestesia geral para apendicectomia aberta foi intubado com tubo endotraqueal aramado e retirada de guia do tubo difícil. Após iniciar a ventilação mecânica houve aumento da fração expiratória de CO₂ e necessidade de aumento da pressão inspiratória. Hipóteses de complicações com maiores incidências foram aventadas e tratadas sem sucesso. Finalmente, ao reintubar o doente, foi verificada dissecação do lúmen do tubo endotraqueal e a ventilação foi restaurada à normalidade.

Conclusão: O ato anestésico envolve inúmeras possíveis complicações. A suspeição e a vigilância constantes são essenciais para diagnosticar e tratar precocemente qualquer ameaça à integridade do indivíduo. O presente caso é relevante por enfatizar uma possível complicação muito incomum relacionada às vias aéreas capaz de causar hipóxia e danos irreversíveis rapidamente. Dessa forma, o caso contribui para que essa intercorrência seja detectada com maior frequência.

© 2015 Sociedade Brasileira de Anestesiologia. Publicado por Elsevier Editora Ltda. Este é um artigo Open Access sob uma licença CC BY-NC-ND (<http://creativecommons.org/licenses/by-nc-nd/4.0/>).

Introduction

Tracheal intubation in general anesthesia is an essential technique for numerous surgical procedures. Airway protection and mechanical ventilation enable the safe administration of anesthetics to ensure adequate hypnosis, pain inhibition, and muscle relaxation.¹

However, the use of this technique depends on the correct operation of a set of equipment and materials related to the anesthesia. Any defect in any of these materials can compromise the intubation technique and determine a potentially tragic event due to ventilation problem and airway protection. Defects may appear anywhere on the ventilator (bellow, corrugated pipe, capnography, gas input) and endotracheal tube (mucus, foreign body, kinking, cuff herniation or leakage). Because the problem manifestation is common to several clinical complications, it is often not readily identified and corrected, which leads to rapid deterioration of respiratory symptoms and may lead to death.²

We report an uncommon case of deformity and obstruction of the wired endotracheal tube caused by a very difficult removal of the guide wire inserted into the tube.

Case report

Male patient, 12 years old, 35 kg, referred to the operation room (OR) by the emergency service to receive an open appendectomy. He arrived at the OR accompanied by his mother who denied allergies, comorbidities or regular use of medications. Patient's physical status ASA I, HR 110 bpm, blood pressure (BP) 108 × 52 mmHg, SpO₂ 96% in room air; good general condition normal skin color, mild dehydration, eupneic, lucid and oriented. Regarding airway, he had appropriate mouth opening and neck mobility (Mallampati I).

Intravenous infusion was made in left arm with Jelco 20G. After intravenous induction with fentanyl (250 mcg), lidocaine (20 mg), propofol (110 mg) and cisatracurium (7 mg), ventilation under face mask was started.

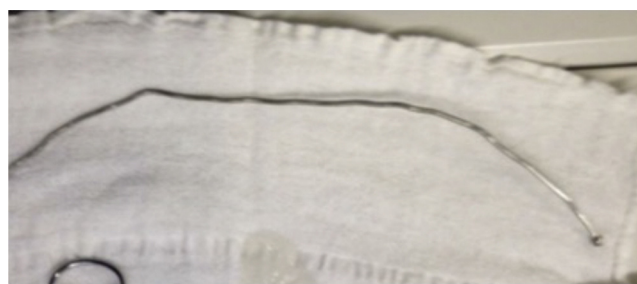

Figure 1 The guide wire used.

After intubation with the help of a Macintosh curved blade #3 and the introduction of the wired endotracheal tube (ETT) #6, the tube guide was removed with great difficulty (Fig. 1). The cuff was inflated and confirmed the position by symmetrical bilateral auscultation and compatible capnographic curve.

Coupled to the automatic mechanical ventilator in the PCV mode, the inspired pressure was 17 cmH₂O at respiratory rate (RR) 16 rpm and positive end expiratory pressure (PEEP) 5 cmH₂O, FiO₂ 40% with 3% sevoflurane. After 20 min, a tidal volume of 120 mL was seen. Therefore, the inspired pressure was increased to 25 cmH₂O to obtain a tidal volume of 280 mL. Subsequently, the gas analyzer indicated increasing rate of ET-CO₂ up to 68 mmHg. Symmetrical and bilateral auscultation was performed, with reduction of murmurs. Administration of ketamine IV (25 mg), did not change the ventilatory pattern. RR was reduced to 10 rpm and a ratio of 1:5 in expiratory time.

After collecting arterial blood gases, intravenous propofol (50 mg) was administered as well as an increasing fraction of inspired sevoflurane. At that point, BP was 97 × 54 mmHg. Arterial blood gas measurement showed pH 7.2; PCO₂ 56.6 mmHg; HCO₃⁻ 22.3; Hb 10.7; Na⁺ 143; K⁺ 3.9; Cl⁻ 101; Ca²⁺ 0.7.

It was decided to change the endotracheal tube to another wired #6. Intubation was performed with no difficulties. The patient was coupled to the ventilator in PCV

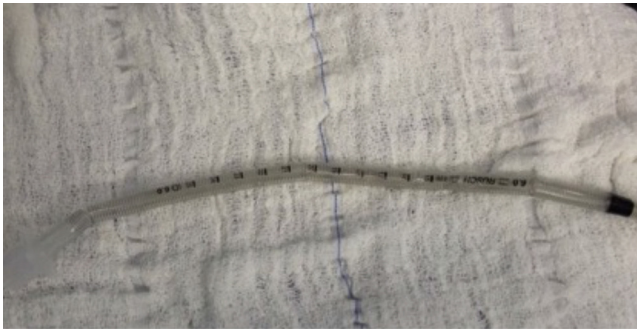


Figure 2 Wired endotracheal tube, outside view.




Figure 3 Sectioned wired endotracheal tube, lumen view with dissection.

mode with inspired pressure of 16 cmH₂O and tidal volume of 260 mL. There was a rapid reduction of ETCO₂ rate from 70 to 50 mmHg.

Evaluation of the removed ETT indicated that there was a deformity with irregular reduction of its internal gauge, which caused obstructive ventilation and required high inspiratory pressures (Figs. 2 and 3).

Discussion

Inadequate airway management remains a very important element, as it is associated with perioperative morbidity and mortality. It may include problems related to the patient or anesthesia equipment failure and anesthetic agent complications.

Among the cases of airway complications reported in the literature there are injuries occurred during the introduction of the intubation tube; inadequate immobilization of patients; difficulties related to humidifiers; complications related to endotracheal tube involving the reuse of these devices; heat exposure; stretching the tube by use of anesthetics such as nitrous oxide (N₂O); detachment of parts of the endotracheal tube, which generate a valve mechanism and, rarely, dissection of the internal wall of the endotracheal tube, as shown in this case.³⁻⁹

Mercanoglu et al.⁸ reported a case of dissection of the inner wall of a wired ETT after its reuse. It was concluded that the resterilization and reuse of this material predispose the reported complication. Based on published data, as well as on this report, measures for bronchospasm treatment were initiated, with unsatisfactory results. We opted for exchanging the ETT and the returning to the parameters prior to tube dissection.⁸

In the case described here, because it is a rare situation, there was no immediate suspicion of the wired tube inner wall dissection. Thus, as soon as the patient began to show the mentioned symptoms, the first hypothesis was bronchospasm that was treated with deeper anesthesia, administration of vasodilators, and ventilator adjustment with lower respiratory rate and increased expiratory time. After these measures and with no reversal of symptoms, it was decided to change the disposable wired endotracheal tube. Only after inspection of this device, it was noted that its inner walls were dissected.

Among the possible causes reported in the literature, the wired tube dissection may occur due to the reuse or resterilization of the device.⁷ Once the aforementioned situations do not apply to this case report, it can be assumed that there was quality control problems in the manufacture of the endotracheal tube.

Conclusion

Knowledge of possible complications, such as the one presented in this report, as well as careful evaluation of patients and routine making the anesthetic-surgical checklist enables doctors to predict unwanted situations and allows immediate intervention to decrease repercussions imposing risk to the patient's life.

Conflicts of interest

The authors declare no conflicts of interest.

References

1. Matsumoto T, de Carvalho WB. Tracheal intubation. *J Pediatr (Rio J)*. 2007;83: 583-90.
2. Holsbah LR, Fornazier C, Trindade E, et al. Abordagem de Vigilância Sanitária de Produtos para Saúde Comercializados no Brasil: Sistema de Anestesia. *Bol Inf Tecnovigilância*. ISSN 2178-440X 2012.
3. Blanc VF, Tremblay Na. The complications of tracheal intubation: a new classification with a review of the literature. *Anesth Analg*. 1974;53:202-13.
4. Husain T, Gatward JJ, Hambidge ORH, et al. Strategies to prevent airway complications: a survey of adult intensive care units in Australia and New Zealand. *Br J Anaesth*. 2012;108:800-6.
5. Khatami SF, Parvaresh P, Behjati S. Common complications of endotracheal intubation in newborns. *Iran J Neonatol*. 2011;2:12-7.
6. Martins RHG, Dias NH, Braz JRC, et al. Complicações das vias aéreas relacionadas à intubação endotraqueal. *Rev Bras Otorrinolaringol*. 2004;70:671-7.
7. Mota LAA, de Cavalho GB, Brito VA. Complicações laringeas por intubação orotraqueal: revisão da literatura. *Int Arch Otorhinolaryngol*. 2012;16:236-45.

8. Mercanoglu E, Topuz D, Kaya N. Dissecção da parede interna de tubo endotraqueal aramado que causa obstrução das vias aéreas no intraoperatório sob anestesia geral. Relato de caso. *Rev Bras Anesthesiol.* 2013;63:372–4.
9. Stauffer JL, Olson DE, Petty TL. Complications and consequences of endotracheal intubation and tracheotomy. A prospective study of 150 critically ill adult patients. *Am J Med.* 1981;70: 65–76.