



# REVISTA BRASILEIRA DE ANESTESIOLOGIA

Publicação Oficial da Sociedade Brasileira de Anestesiologia  
[www.sba.com.br](http://www.sba.com.br)



## CLINICAL INFORMATION

# Intractable intraoperative brain herniation secondary to tension pneumocephalus: a rare life-threatening complication during drainage of subdural empyema



Li Lian Foo<sup>a,\*</sup>, Sook Hui Chaw<sup>a</sup>, Lucy Chan<sup>a</sup>, Dharmendra Ganesan<sup>b</sup>, Ravindran Karuppiah<sup>c</sup>

<sup>a</sup> University of Malaya, Faculty of Medicine, Department of Anesthesiology, Kuala Lumpur, Malaysia

<sup>b</sup> University of Malaya, Faculty of Medicine, Department of Surgery, Kuala Lumpur, Malaysia

<sup>c</sup> University Malaya Medical Centre, Department of Surgery, Kuala Lumpur, Malaysia

Received 25 December 2014; accepted 28 January 2015

Available online 3 October 2015

### KEYWORDS

Intraoperative brain herniation;  
Tension pneumocephalus;  
Hydrogen peroxide;  
Brain amputation

**Abstract** Tension pneumocephalus is rare but has been well documented following trauma and neurosurgical procedures. It is a surgical emergency as it can lead to neurological deterioration, brainstem herniation and death. Unlike previous cases where tension pneumocephalus developed postoperatively, we describe a case of intraoperative tension pneumocephalus leading to sudden, massive open brain herniation out of the craniotomy site. The possible causative factors are outlined. It is imperative to rapidly identify possible causes of acute intraoperative brain herniation, including tension pneumocephalus, and institute appropriate measures to minimize neurological damage.

© 2015 Sociedade Brasileira de Anestesiologia. Published by Elsevier Editora Ltda. This is an open access article under the CC BY-NC-ND license (<http://creativecommons.org/licenses/by-nc-nd/4.0/>).

### PALAVRAS-CHAVE

Herniação cerebral no intraoperatório;  
Pneumoencéfalo hipertensivo;  
Peróxido de hidrogênio;  
Amputação cerebral

**Herniação cerebral intratável secundária a pneumoencéfalo hipertensivo no intraoperatório: uma complicação rara com risco para a vida durante a drenagem de empiema subdural**

**Resumo** O pneumoencéfalo hipertensivo é raro, mas foi bem documentado após trauma e procedimentos neurocirúrgicos. Trata-se de uma emergência cirúrgica porque pode levar à deterioração neurológica, herniação do tronco cerebral e morte. Ao contrário de casos anteriores nos quais o pneumoencéfalo hipertensivo se desenvolveu no pós-operatório, descrevemos um caso de pneumoencéfalo hipertensivo desenvolvido no período intraoperatório levando

\* Corresponding author.

E-mail: [foolilian79@yahoo.com](mailto:foolilian79@yahoo.com) (L.L. Foo).

a uma herniação cerebral súbita, maciça e aberta para fora do local da craniotomia. Os possíveis fatores causais são destacados. É imperativo identificar rapidamente as possíveis causas da herniação cerebral aguda no intraoperatório, incluindo o pneumoencefalo hipertensivo, e instituir medidas apropriadas para minimizar os danos neurológicos.

© 2015 Sociedade Brasileira de Anestesiologia. Publicado por Elsevier Editora Ltda. Este é um artigo Open Access sob uma licença CC BY-NC-ND (<http://creativecommons.org/licenses/by-nc-nd/4.0/>).

## Introduction

Tension pneumocephalus is rare but well documented, with studies showing an incidence of 2.5–16%<sup>1</sup> since it was first described in 1962. Most cases occur postoperatively and present with neurological deterioration. To our knowledge this is the first such case report of intraoperative tension pneumocephalus which presented with immediate consequences – massive brain herniation from the operative site. Anesthetic and surgical considerations in the management of tension pneumocephalus and intraoperative brain herniation are outlined.

## Case report

A 27 year-old female presented with right sided weakness and blurring of vision. CT scan showed a left parietal tumour and she underwent craniotomy and excision. She recovered well and was discharged with persistent right sided weakness.

Three weeks later, she presented again with wound breakdown and pus discharge from the craniotomy site. CT (Fig. 1) revealed a subdural empyema in both frontal regions measuring 1.3 cm in depth with post-surgical encephalomalacic changes in the left parasagittal region. She was posted for an emergency craniectomy and wound debridement.

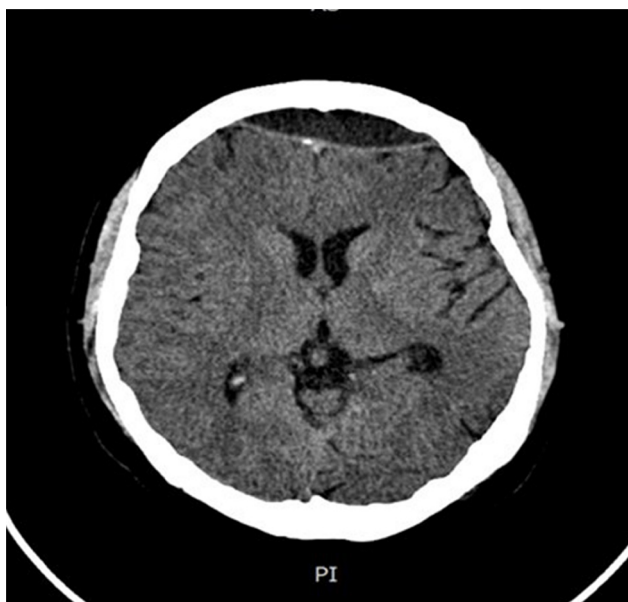

Figure 1 Preoperative CT scan.

Pre-operatively, she was afebrile with GCS of 15/15. Her baseline blood pressure (BP) was 115/75 mmHg and heart rate was 105 beats per minute (bpm). In the operating theatre, under standard monitoring, induction of anesthesia proceeded with intravenous fentanyl 2 mcg.kg<sup>-1</sup> and IV propofol 2.5 mg.kg<sup>-1</sup>. Muscle paralysis was achieved with IV rocuronium 1 mg.kg<sup>-1</sup>. Her airway was secured with a size 7.5 cm cuffed PVC endotracheal tube and she was positioned supine with her head on a horseshoe headrest. We maintained general anesthesia with Sevoflurane in oxygen: air (FiO<sub>2</sub> of 0.5).

Her previous incision wound over the frontal area was opened and bone flap removed. Slough and pus discharge was noted on the brain surface. The wound was debrided and then irrigated with approximately 10 mL of 3% hydrogen peroxide mixed with normal saline in a bulb syringe. Upon completion of irrigation, profound brain herniation occurred through the operative site. It happened acutely and wound closure was impossible. There was no obvious bleeding seen.

Physiological parameters prior to herniation were all within normal range (BP: 100/50 mmHg; HR: 95–115 bpm, saturation: 99–100%, end tidal CO<sub>2</sub>: 33–36 mmHg). Minimum Alveolar Concentration had been maintained at 0.9. She had been given intermittent boluses of rocuronium for muscle relaxation. Analgesia was achieved with intravenous morphine 4 mg and an IV alfentanil 1 mg bolus was given during the incident. During acute brain herniation, transient hypotension and tachycardia were observed which resolved with a fluid bolus.

Immediate measures to decrease brain bulk included hyperventilation to decrease the PaCO<sub>2</sub> to 30–35 mmHg and administration of intravenous mannitol (0.5 g.kg<sup>-1</sup>). IV phenytoin 1 g was given for seizure prophylaxis. The head position was checked to ensure the neck veins were not compressed. However, the brain herniation persisted. The surgeon then proceeded with amputation of the herniated brain for decompression and closure.

An urgent CT brain post-operation showed left parietal brain herniation and cerebral oedema of herniated brain and part of the left parietal lobe. Extensive subdural pneumocephalus was seen in both frontal regions (Fig. 2). A new subdural collection was also noted in the left parieto-temporo-occipital region.

She was cerebral protected post-operatively and another wound debridement and burr hole was done two days later for persistent discharge and the presence of extensive subdural pneumocephalus from CT scan.

Despite the profound intraoperative open brain herniation and brain amputation, the patient had a reasonably good neurological outcome with expressive aphasia.

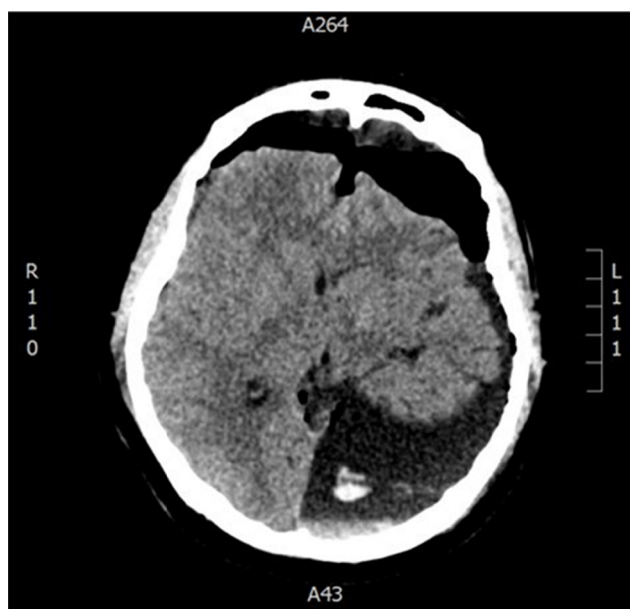


Figure 2 Post operative CT scan.

## Discussion

Acute intraoperative brain herniation through the craniotomy site is uncommon. It has been described during traumatic brain injuries and excision of brain tumour.<sup>2</sup> The exact incidence is unknown, but Whittle et al. estimated a 0.7% incidence in his practice.<sup>2</sup>

Herniation of brain tissue leads to tension on crossing vessels at the dural edge. This results in venous then arterial compression, impaired perfusion and eventual infarction of the herniating brain tissue.<sup>3</sup>

The causes of herniation include malignant brain oedema,<sup>3</sup> hyperemia,<sup>4,5</sup> and haemorrhage<sup>2</sup> (subdural, subarachnoid or intraventricular) at a site distant to the craniotomy, acutely increasing intracranial pressure and forcing brain tissue out of the dural defect.<sup>2,3,6</sup> In this patient, extensive subdural tension pneumocephalus was the main cause as shown in the post operative CT Scan (Fig. 2). Several factors may have led to its rapid development which is outlined below.

Firstly, irrigation of the operative field after drainage of subdural empyema may have introduced air into the subdural cavity. Two previous studies showed a higher incidence of post-operative pneumocephalus after drainage with irrigation for chronic subdural hematomas as compared to drainage alone.<sup>7,8</sup> Air in the bulb irrigation syringe may have been flushed at high pressures into the subdural space.

Secondly, the use of hydrogen peroxide may have introduced air intracranially. Hydrogen peroxide is commonly used in neurosurgery for hemostasis and for disinfection. It decomposes to water and oxygen in an exothermic reaction, catalyzed by tissue catalase. 1 mL of 3% H<sub>2</sub>O<sub>2</sub> releases approximately 10 mL of oxygen.<sup>9</sup> This liberated oxygen can lead to well documented complications such as venous oxygen embolism, pneumocephalus and cardiac dysrhythmias.<sup>10</sup>

Lastly, air from the two mechanisms above may have been trapped in the subdural space by a dural flap producing a ball valve mechanism, leading to the development of an intraoperative tension pneumocephalus.

Preexisting cerebral oedema, combined with new subdural collection in the left parieto-temporo-occipital region may also have contributed to increased intracranial pressure (ICP).

Pneumocephalus is a common finding, with 100% of post craniotomy patients having pneumocephalus on the first postoperative day,<sup>1,11</sup> reducing to 26% by the third postoperative week.<sup>11</sup> Tension pneumocephalus, however, is rare, and occurs when intracranial air exerts a pressure effect and manifests with neurological deterioration.<sup>1,12</sup> It has been reported following trauma, or as a complication of surgery – commonly drainage of chronic subdural haemorrhage, shunt surgeries, craniofacial and transsphenoidal procedures, and posterior fossa craniotomies in the sitting position.<sup>1</sup>

The following mechanisms have been proposed<sup>1</sup>:

1. Inverted soda bottle phenomenon  
Leakage of CSF causes negative intracranial pressure and sucks air in.
2. Ball valve mechanism  
Air enters intracranial cavity through a defect. Raised intracranial pressure forces brain parenchyma to block the entry site and traps the intracranial air.
3. Expansion of intracranial air-filled spaces by nitrous oxide anesthesia.
4. Gas forming organisms such as *Escherichia coli*.<sup>13</sup>

Tension pneumocephalus should be managed as a surgical emergency by immediate release of air through a burr hole, needle aspiration or insertion of a drain.<sup>1,12</sup>

All published reports of tension pneumocephalus have occurred post operatively except for one case of cardiac arrest which occurred at the end of operation as the dural edges were sutured.<sup>14</sup> In this case the tension pneumocephalus developed intraoperatively and was so extensive as to cause an acute external brain herniation through the craniotomy site.

## Anesthetic and surgical considerations

The first consideration should be to avoid further increases in ICP. This includes ensuring adequate depth of anesthesia, adequate analgesia, avoiding hyperthermia, hypertension and stopping all drugs known to increase ICP such as nitrous oxide, ketamine and suxamethonium. The next step should be to reduce ICP by simple measures – head up tilt, neck in neutral position to avoid venous obstruction. Cerebral oedema can be reduced by diuretics including frusemide and mannitol and moderate hyperventilation as a temporary measure. Barbiturates or propofol have been used to reduce the cerebral metabolic rate.

The best surgical management for acute intraoperative open brain herniation has not been established. In a series of 7 patients, Whittle and Viswanathan found that rapid closure of the skull and scalp, followed by medical measures or ventricular drainage to maintain normal intracranial pressure produced relatively good outcomes.<sup>2</sup> Temporary closure

of the brain with a sterile silicone sheet has also been reported.<sup>15</sup> In our case, the brain herniated at such high pressures that the surgeon was unable to manually reduce it. Therefore brain amputation was performed. This is a matter of controversy as amputation of healthy brain will inevitably result in neurological deficits.

A hybrid operating theatre containing advanced imaging facilities such as CT and MRI would have been beneficial in this scenario, enabling timely intra-operative diagnosis and appropriate interventions.

## Conclusion

We present the first case report to our knowledge of an intra-operative tension pneumocephalus leading to catastrophic open brain herniation. Due to the rarity of this complication, the diagnosis was not immediately recognized intraoperatively. Timely diagnosis, immediate aspiration of air and closure of the scalp may have prevented the distressing alternative of a brain amputation.

## Consent

Published with the written consent of the patient.

## Conflicts of interest

The authors declare no conflicts of interest.

## References

1. Sprague A, Poulgrain P. Tension pneumocephalus: a case report and literature review. *J Clin Neurosci.* 1999;6:418–24.
2. Whittle IR, Viswanathan R. Acute intraoperative brain herniation during elective neurosurgery: pathophysiology and management considerations. *J Neurol Neurosurg Psychiatry.* 1996;61:584–90.
3. Khu KJ, Ng WH. Intraoperative swelling leading to neurological deterioration: an argument for large craniotomy in awake surgery for glioma resection. *J Clin Neurosci.* 2009;16:886–8.
4. Kobrine AI, Kempe LG. Studies in head injury. I. An experimental model of closed head injury. *Surg Neurol.* 1973;1:34–7.
5. Langfitt TW, Tannanbaum HM, Kassell NF. The etiology of acute brain swelling following experimental head injury. *J Neurosurg.* 1966;24:47–56.
6. Meguro K, Kobayashi E, Maki Y. Acute brain swelling during evacuation of subdural hematoma caused by delayed contralateral extradural hematoma: report of two cases. *Neurosurgery.* 1987;20:326–8.
7. Zakaraia AM, Adnan JS, Haspani MS, et al. Outcome of 2 different types of operative techniques practiced for chronic subdural hematoma in Malaysia: an analysis. *Surg Neurol.* 2008;69:608–15 [discussion 16].
8. Erol FS, Topsakal C, Faik Ozveren M, et al. Irrigation vs. closed drainage in the treatment of chronic subdural hematoma. *J Clin Neurosci.* 2005;12:261–3.
9. Dubey PK, Singh AK. Venous oxygen embolism due to hydrogen peroxide irrigation during posterior fossa surgery. *J Neurosurg Anesthesiol.* 2000;12:54–6.
10. Spiriev T, Prabhakar H, Sandu N, et al. Use of hydrogen peroxide in neurosurgery: case series of cardiovascular complications. *JRSM Short Rep.* 2012;3:6.
11. Reasoner DK, Todd MM, Scamman FL, et al. The incidence of pneumocephalus after supratentorial craniotomy. Observations on the disappearance of intracranial air. *Anesthesiology.* 1994;80:1008–12.
12. Shaikh N, Masood I, Hanssens Y, et al. Tension pneumocephalus as complication of burr-hole drainage of chronic subdural hematoma: a case report. *Surg Neurol Int.* 2010:1.
13. Redhu R, Shah A, Jadhav M, et al. Spontaneous tension pneumocephalus in a patient with subdural empyema. *J Clin Neurosci.* 2011;18:1123–4.
14. Thiagarajah S, Frost EA, Singh T, et al. Cardiac arrest associated with tension pneumocephalus. *Anesthesiology.* 1982;56:73–5.
15. Ahmadian A, Baa JA, Garcia M, et al. Decompressive craniectomy with massive intractable intraoperative cerebral edema: utilization of silicone sheet for temporary scalp closure. *J Neurosurg Pediatr.* 2012;10:195–9.