



REVISTA BRASILEIRA DE ANESTESIOLOGIA

Publicação Oficial da Sociedade Brasileira de Anestesiologia
www.sba.com.br



CLINICAL INFORMATION

Neuraxial anesthesia after local anesthesia for management of percutaneous vertebroplasty complication during vertebroplasty



Hüseyin Balkarlı^a, Mesut Kılıç^b, İbrahim Öztürk^{c,*}

^a Akdeniz University Faculty of Medicine, Orthopaedics and Traumatology, Antalya, Turkey

^b Ondokuzmayıs University Faculty of Medicine, Orthopaedics and Traumatology, Samsun, Turkey

^c Dışkapı Yıldırım Beyazıt Education and Research Hospital, Anesthesiology and Reanimation, Ankara, Turkey

Received 9 June 2014; accepted 16 July 2014

Available online 27 October 2014

KEYWORDS

Neuraxial anesthesia;
Percutaneous
vertebroplasty;
Vertebra;
Fracture

Abstract Percutaneous vertebroplasty is a relatively safe, simple and commonly performed interventional procedure for the management of vertebral compression fractures. However, serious complications are rarely reported in the procedure. Those are pulmonary embolism, severe infection, paraplegia and an occurrence of a new fracture in an adjacent vertebra after vertebroplasty. Acute complications are generally associated with the procedure. We present the case of neuraxial anesthesia, developed after local anesthesia with 8 mL of 2% prilocaine, in a 68-year-old woman who underwent percutaneous vertebroplasty after an osteoporotic collapsed fracture in the L₁ vertebra due to trauma. To our knowledge, this is the first case in the literature.

© 2014 Sociedade Brasileira de Anestesiologia. Published by Elsevier Editora Ltda. This is an open access article under the CC BY-NC-ND license (<http://creativecommons.org/licenses/by-nc-nd/4.0/>).

PALAVRAS-CHAVE

Bloqueio neuraxial;
Vertebroplastia
percutânea;
Vértebra;
Fratura

Bloqueio neuroaxial após anestesia local para manejo de complicação de vertebroplastia percutânea durante vertebroplastia

Resumo Vertebroplastia percutânea é um procedimento intervencionista relativamente seguro, simples e comumente realizado para tratar fraturas por compressão vertebral. No entanto, as complicações graves relacionadas ao procedimento são raramente relatadas, incluindo embolia pulmonar, infecção grave, paraplegia e a ocorrência de uma nova fratura em vértebra adjacente após a vertebroplastia. Complicações agudas são geralmente associadas ao procedimento. Apresentamos o caso de bloqueio neuroaxial, realizado após anestesia local

* Corresponding author.

E-mail: drozturk28@gmail.com (İ. Öztürk).

com 8 mL de prilocaína a 2%, em uma mulher de 68 anos de idade, submetida à vertebroplastia percutânea após fratura osteoporótica na vértebra L₁ devido a trauma. De acordo com nossa pesquisa, este é o primeiro caso na literatura.

© 2014 Sociedade Brasileira de Anestesiologia. Publicado por Elsevier Editora Ltda. Este é um artigo Open Access sob uma licença CC BY-NC-ND (<http://creativecommons.org/licenses/by-nc-nd/4.0/>).

Introduction

Percutaneous vertebroplasty (PV) is a relatively safe, simple, and commonly performed procedure for the management of vertebral compression fractures, but serious complications have been reported, including pulmonary embolism,¹ severe infection,² paraplegia³ and an occurrence of a new fracture in an adjacent vertebra after vertebroplasty.⁴ Acute complications are mostly related to surgical procedures, which include leakage of bone cement, infection, and fracture along the path of the vertebroplasty cannula.^{5,6}

We present a rare case of neuraxial anesthesia correlated with local anesthesia during a surgical PV using the transpedicular approach.

Case report

A 68-year-old and 75 kg weighing female patient was admitted to the Emergency Department of Tavas Community Hospital with back pain due to trauma following falling down at home. The patient had an osteoporotic collapsed fracture in the L₁ vertebra, which was treated conservatively with bedrest, corset and analgesic medications. At the 3rd week follow-up examination, pain had not reduced and on the direct radiograph more than 50% of the fractured L₁ vertebra was observed to have collapsed compared to the upper adjacent vertebra (Fig. 1). PV was recommended for the patient.

At the preoperative evaluation of patient, laboratory tests, electrocardiogram and X-ray of lung were normal. There was no chronic systemic disease. And her physical status was evaluated as level 1 according to American Society of Anesthesiologist's scale. The preoperative visual analogue pain scale score (VAS) was 8. After obtaining informed consent, patient's fracture line was located with fluoroscopy in prone position and then under fluoroscopic control, local anesthesia of 8 mL of 2% prilocaína was applied from the pedicle entrance as far as the subcutaneous tissue. No neurological deficit was determined following local anesthesia. After location of the pedicle entrance of the fractured vertebra under fluoroscopy, an 11G needle was entered from the pedicle. When the needle reached 2/3 anterior of the vertebral corpus on the lateral view, the anterior-posterior view was regarded and that the tip of the needle was at the same level as the spinous process. The needle position was checked by fluoroscopy. At this stage, the neurological examination of the patient was normal. After confirmation

of the needle tip location, 8 mL of cement was injected into the fracture line (Fig. 2).

During and following the cementing, the neurological examination of the patient was normal. After setting of the cement, the patient was placed in a supine position. Immediately after the patient was positioned supine, a bilateral lower extremity loss of strength (2/5) and sensation deficit occurred. It was noticed by the operator during neurological examination. Blood pressure was measured as 90/50 mmHg and 500 mL of 0.9% NaCl was administered. As the sensation loss, at T₁₀ level at first examination, reached up to T₅. The patient was moved into the beach-chair position to prevent further development of neuraxial block.

The patient was again evaluated neurologically, and bilateral loss of strength (0/5) in the lower extremities and anesthesia were observed. 6 mg betamethasone was administered intramuscularly. The patient was evaluated with direct radiographs at operating theater and cement was not observed in canal (Fig. 3). 30 min after the onset of the sensation deficit, blood pressure was measured as 110/90 mmHg and the deficit had returned to the level of the umbilicus.

On evaluation of patient by computer tomography, no cement was observed in canal (Fig. 4). At the 4th hour of follow-up sensation and motor deficit was completely resolved. The patient was mobilized. We did not observe hypotension or bradycardia and no inotropic drug was needed.

Discussion

Vertebroplasty has been widely used to treat vertebral body compression fractures (VCFs) caused by varied pathologies including hemangioma, multiple myeloma, osteolytic metastases, and primary or secondary osteoporosis.⁷ VCFs are the most common type of osteoporotic fractures, resulting in severe back pain, spinal deformity, muscle atrophy, prolonged hospitalization, and potential risk of increased mortality.⁸

In meta-analysis of PV, low complication rate of 0.4–3.8% has been reported.⁹ Overall complication rates due to PV are reported to be very low. However, the procedure is not free of risk. Rare, but serious complications have been observed during PV application such as pulmonary embolism, cardiac perforation, epidural cement extravasion paraspinal, intradisc or venous system cement leakage, infection or fractures of adjacent vertebra.

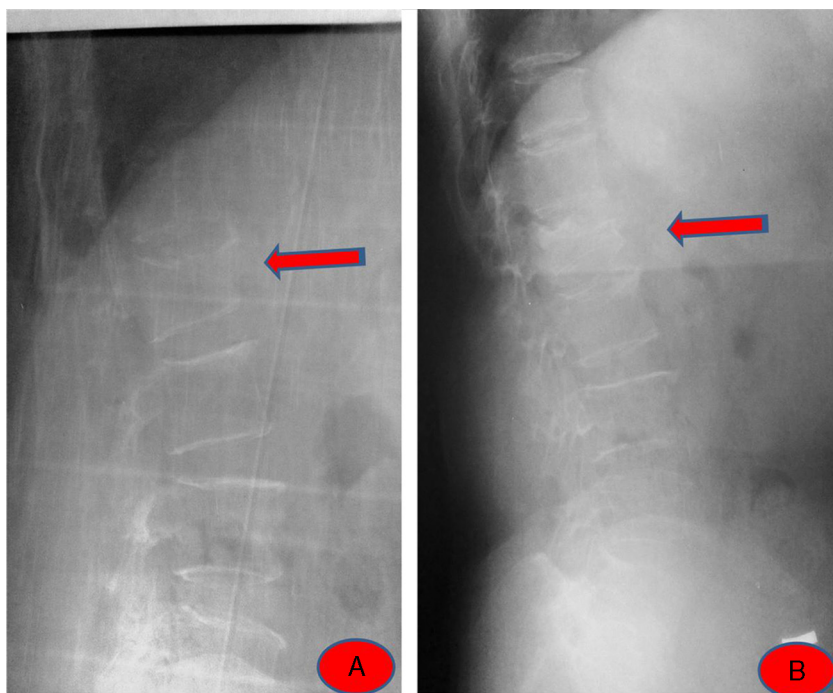


Figure 1 (A) Acute L₁ fracture. (B) After 3 weeks conservative treatment.

In literature, no patient has been reported with neuraxial anesthesia development associated with local anesthesia during PV. The significance of this is that a neurological injury associated with the guide used during the procedure may be confused with neurological injury which may occur after leakage of the cement into the canal and a second operation such as open surgery is required. Differential diagnosis should certainly be made for these above-mentioned

complications which may arise following PV and other neurological injuries which occur during PV. If there are neurological deficits which occur during PV and this event is considered to be associated with local anesthetic, the level of neuraxial anesthesia may be increased and complications associated with the increased level should be kept in mind, the patient should be closely monitored, and anesthesia specialist must certainly consult the patient.

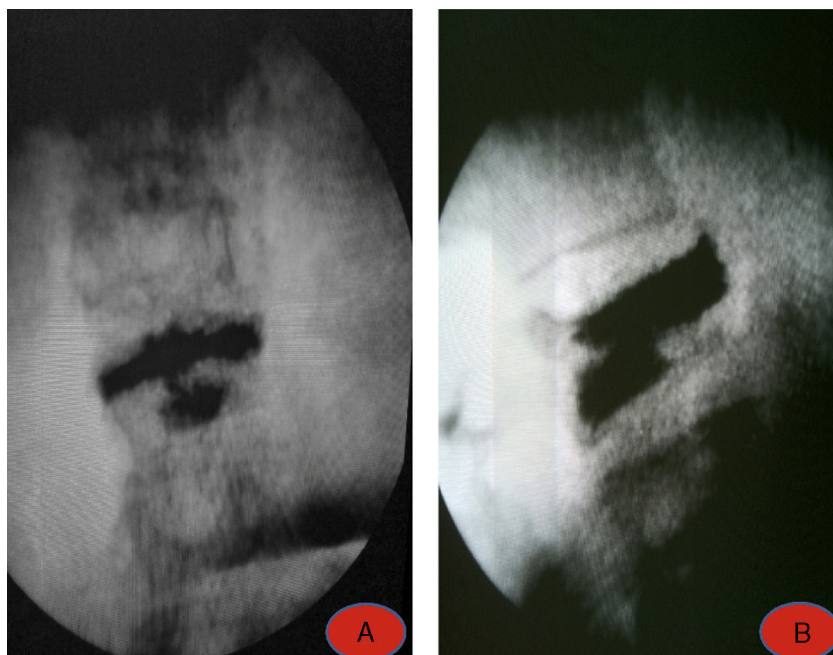


Figure 2 (A) Intraoperative fluoroscopy view (AP). (B) Intraoperative fluoroscopy view (lateral).

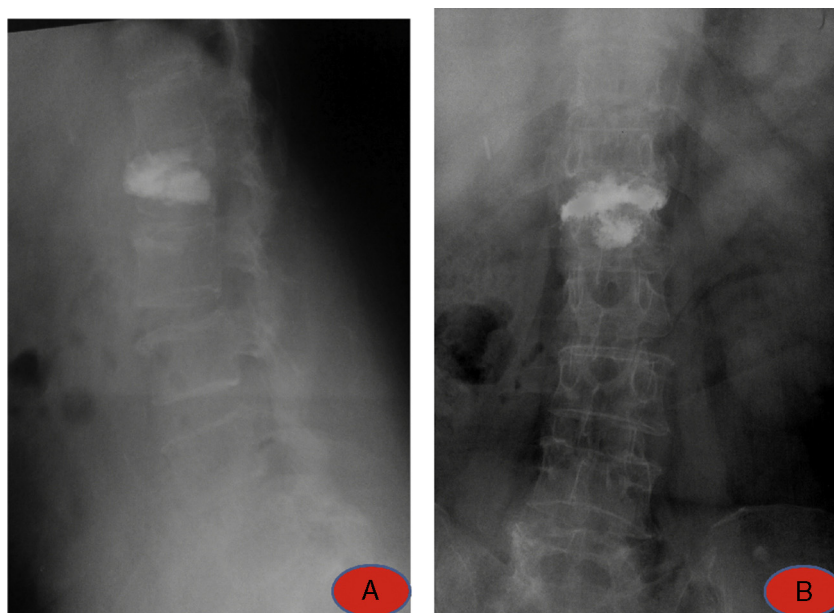


Figure 3 (A) Postoperative X-ray (AP). (B) Postoperative X-ray (lateral).

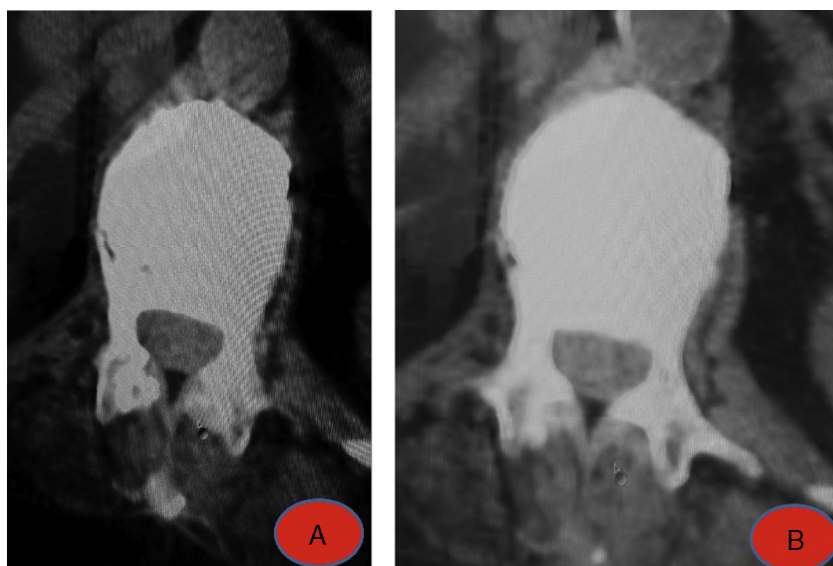


Figure 4 (A and B) Postoperative CT.

Conclusion

In our knowledge, this is the first neuraxial anesthesia case due to local anesthesia after PV in the literature. If there is no cement into the canal, neuraxial anesthesia should be kept in mind. At this point, radiopaque agent may be useful before injection of local anesthetic drug for confirming the place of needle's tip, to prevent an inadvertent neuraxial anesthesia.

Conflicts of interest

The authors declare no conflicts of interest.

References

1. Chen HL, Wong CS, Ho ST, et al. A lethal pulmonary embolism during percutaneous vertebroplasty. *Anesth Analg.* 2002;95: 1060–2.
2. Lin WC, Lee CH, Chen SH, et al. Unusual presentation of infected vertebroplasty with delayed cement dislodgment in an immunocompromised patient: case report and review of literature. *Cardiovasc Intervent Radiol.* 2008;31 (Suppl. 2): 231–5.
3. Lee BJ, Lee SR, Yoo TY. Paraplegia as a complication of percutaneous vertebroplasty with polymethylmethacrylate: a case report. *Spine (Phila Pa 1976).* 2002;27:E419–22.
4. Aquarius R, Homminga J, Verdonchot N, et al. The fracture risk of adjacent vertebrae is increased by the changed

- loading direction after a wedge fracture. *Spine (Phila Pa 1976)*. 2011;36:E408–12.
5. McArthur N, Kasperk C, Baier M, et al. 1150 kyphoplasties over 7 years: indications, techniques, and intraoperative complications. *Orthopedics*. 2009;32:90.
 6. Tanigawa N, Kariya S, Komemushi A, et al. Cement leakage in percutaneous vertebroplasty for osteoporotic compression fractures with or without intravertebral clefts. *AJR Am J Roentgenol*. 2009;193:W442–5.
 7. Afzal S, Dhar S, Vasavada NB, et al. Percutaneous vertebroplasty for osteoporotic fractures. *Pain Physician*. 2007;10:559–63.
 8. Shi MM, Cai XZ, Lin T, et al. Is there really no benefit of vertebroplasty for osteoporotic vertebral fractures? A meta-analysis. *Clin Orthop Relat Res*. 2012;470:2785–99.
 9. Lee MJ, Dumonski M, Cahill P, et al. Percutaneous treatment of vertebral compression fractures: a meta-analysis of complications. *Spine (Phila Pa 1976)*. 2009;34:1228–32.