



REVISTA BRASILEIRA DE ANESTESIOLOGIA

Official Publication of the Brazilian Society of Anesthesiology
www.sba.com.br



MISCELLANEOUS

Correlation of bispectral index (BIS) monitoring and end-tidal sevoflurane concentration in a patient with lobar holoprosencephaly



Dario Galante^{a,*}, Donatella Fortarezza^a, Maria Caggiano^a, Giovanni de Francisci^b,
Dino Pedrotti^c, Marco Caruselli^d

^a University Department of Anesthesia and Intensive Care, University Hospital Ospedali Riuniti of Foggia, Italy

^b Department of Anesthesia and Intensive Care, Agostino Gemelli Hospital, Catholic University of the Sacred Heart, Rome, Italy

^c Department of Anesthesia and Intensive Care, S. Chiara Hospital, Trento, Italy

^d Department of Anesthesia and Intensive Care, La Timone Children's Hospital, Marseille, France

Received 27 March 2014; accepted 3 July 2014

Available online 25 October 2014

KEYWORDS

Holoprosencephaly;
Bispectral index;
Sevoflurane;
Seizures

Abstract

Objective: The bispectral index (BIS) is a parameter derived by electroencephalography (EEG) which provides a direct measurement of the effects of sedatives and anesthetics on the brain and offers guidance on the adequacy of anesthesia. The literature lacks studies on BIS monitoring in pediatric patients with congenital brain disease undergoing general anesthesia.

Clinical features: A 13-year-old child weighing 32 kg, suffering from lobar holoprosencephaly, underwent surgery in which the bispectral index (BIS) monitoring the depth of anesthesia showed an abnormal response. Detailed analysis of the trends of BIS values in the different observation times demonstrated sudden falls and repetitive values of BIS likely related to repetitive epileptiform electrical activity caused by sevoflurane.

Conclusion: The BIS is a very useful monitoring tool for assessing the degree of depth of anesthesia and to analyze the electroencephalographic variations of anesthetics. Particular attention should be given to patients with congenital disorders of the central nervous system in which the BIS may give abnormal responses that do not reflect an accurate assessment of the depth of anesthesia.

© 2014 Sociedade Brasileira de Anestesiologia. Published by Elsevier Editora Ltda. All rights reserved.

* Corresponding author.

E-mail: dario.galante@tin.it (D. Galante).

PALAVRAS-CHAVE

Holoprosencefalia;
Índice bispectral;
Sevoflurano;
Convulsões

Correlação entre monitoração do índice bispectral (BIS) e concentração expirada de sevoflurano em paciente com holoprosencefalia lobar**Resumo**

Objetivo: O índice bispectral (BIS) é um parâmetro derivado por eletroencefalografia (EEG) que fornece uma medida direta dos efeitos de sedativos e anestésicos no cérebro e orientação sobre a adequação da anestesia. A literatura carece de estudos sobre a monitoração do BIS em pacientes pediátricos com doença cerebral congênita submetidos à anestesia geral.

Características clínicas: Criança de 13 anos de idade, pesando 32 kg, com holoprosencefalia lobar, foi submetida à cirurgia em que a monitoração da profundidade da anestesia com o uso do BIS mostrou uma resposta anormal. A análise detalhada das tendências dos valores do BIS nos diferentes tempos de observação mostrou quedas súbitas e valores repetitivos do BIS, provavelmente relacionados à atividade elétrica epileptiforme repetitiva causada por sevoflurano.

Conclusão: O BIS é uma ferramenta de monitoração muito útil para avaliar o grau de profundidade da anestesia e as variações eletroencefalográficas dos anestésicos. Atenção especial deve ser dedicada aos pacientes com doenças congênitas do sistema nervoso central nos quais o BIS pode apresentar respostas anormais que não refletem a avaliação precisa da profundidade da anestesia.

© 2014 Sociedade Brasileira de Anestesiologia. Publicado por Elsevier Editora Ltda. Todos os direitos reservados.

Introduction**Holoprosencephaly**

Holoprosencephaly (HPE) is a complex brain malformation in which there is an incomplete separation of the forebrain between the 18th and 28th day of intrauterine life, affecting both the forebrain and the face, causing neurological and facial defects of varying severity.¹

It has a prevalence of 1 in 250 during early embryo development, and 1 in 10,000 to 1 in 20,000 at term.

Three classic forms of progressive severity have been described, classified according to their anatomical features: HPE lobar, semi-lobar, and alobar. A milder subtype, known as middle interhemispheric variant (MIH), was also identified. The HPE phenotype also includes aprosencefalia/atelencefalia (the most severe sign), schizencephaly and septo-preoptic HPE. The less severe forms are defined microforms, characterized by defects in the midline, in the absence of brain malformation typical of HPE. However, the disease is characterized by a continuous spectrum of abnormal separation of the cerebral hemispheres rather than a distinct subdivision of these forms which present, however, significant in clinical inter- and intra-familial variability. In many cases, there is a correlation between the severity of facial abnormalities and brain anomaly (with the exception of mutation cases in the *ZIC2* gene). In descending order of severity the main facial features are cyclopia, a proboscis, premaxillary agenesis, a cleft lip, coloboma, retinal dysplasia, choanal stenosis, stenosis of the pyriform sinus, hypotelorism, a single median maxillary incisor, and even a normal face. Severe forms (especially in the presence of a chromosomal abnormality) are often fatal and mortality is associated with the severity of the brain malformation and associated defects. In children who survive, a broad

spectrum of related signs has been described: developmental delay, hydrocephalus, motor deficits, eating problems, motor dysfunction, epilepsy, and hypothalamic dysfunction. Endocrine disorders from pituitary abnormalities, such as central diabetes, are common.

Lobar holoprosencephaly is the milder classic form of holoprosencephaly. It is characterized by the separation between the left and right cerebral hemispheres and lateral ventricles with a junction along the frontal neocortex, particularly rostrally and ventrally. Approximately 19% of patients with lobar HPE have the shape.

The bispectral index

Bispectral index (BIS) monitoring allows for an early assessment, in real time, of the effects of anesthetic agents during monitored patient care.² The clinical impact of BIS monitoring has been demonstrated in several randomized controlled studies that reveal how this tool also allows for greater patient safety. In particular, this equipment can reduce the risk of a potential awareness and/or intraoperative awareness measured on a continuous, non-invasive level of sedation of the patient by means of special adhesive sensors. The bispectral index is a parameter derived by electroencephalography (EEG) which provides a direct measurement of the effects of sedatives and anesthetics on the brain and offers guidance on the adequacy of anesthesia.^{3,4} Research shows that under general anesthesia approximately 2 out of 1000 patients experience an intraoperative awareness. The BIS is currently the only technology for monitoring the state of consciousness that can reduce the incidence of intraoperative risk in adults by about 80%. The BIS is represented by a numerical value between 0 and 100, two numbers which indicate the absence of brain activity and wakefulness. The anesthesiologist, thanks to this index, is able to administer

the optimal quantity of drugs for each patient so as to maintain the BIS value within a range that guarantees a non-verbal response to stimuli and the low probability of explicit memory. Prospective studies have shown that a BIS maintained between 40 and 60 ensures an adequate hypnotic state during anesthesia.

The reliability and accuracy of BIS monitoring for pediatric patients is still being studied, especially in very young children, neonates, and infants. In addition, there are no studies on the use of the BIS in pediatric subjects suffering from rare congenital diseases of the central nervous system. A wide variability in the BIS values has been observed in many children with respect to the dosages of anesthetics used.

Case report

One 13-year-old child weighing 32 kg, suffering from lobar holoprosencephaly, was brought to our attention for orchidopexy surgery. The child was in drug treatment with sodium valproate, clorazepam, levothyroxine sodium, somatropin, and desmopressin. The induction was made via inhalation, without premedication, through a mixture of air, oxygen, and sevoflurane at a concentration of 6% and FiO_2 of 0.4, immediately after a peripheral vein was cannulated, followed by the administration of $2 \mu\text{g}/\text{kg}$ of fentanyl and cisatracurium $0.15 \text{ mg}/\text{kg}$. Then a ProSeal laryngeal mask airway (PLMA) size 2.5 was inserted. The child was then connected to mechanical ventilation with a mixture of air, oxygen and end-tidal concentration of sevoflurane 3% with FiO_2 of 0.4 and subsequently reduced to 2%, as a result of the evaluation with bispectral index, allowing perfect adaptation to artificial ventilation. All routine hemodynamic and respiratory monitoring systems were applied: blood pressure, ECG, ETCO_2 and SpO_2 . From the moment of induction adhesive front sensors were applied for the detection of the bispectral index (BIS Vista Monitoring System™, Aspect Medical System, USA), recording the trends for the duration of the surgery until the awakening of the child. The BIS values were recorded at the following times: T_i (induction), T_{sis} (surgical incision of the skin), T_5 (5 min after incision of the skin), $T_{\text{sevo}2}$ (after reduction of the concentration of end-tidal sevoflurane 2%), and T_{recovery} (the cessation of the administration of sevoflurane and upon waking).

During the induction phase with sevoflurane at 6% (T_i) the BIS recorded a median value of 27.5 ± 3.5 DS (Fig. 1). At the time of the surgical incision of the skin, with a concentration of end-tidal sevoflurane at 3% (T_{sis}) a median of 41.5 ± 4.3 DS (Fig. 1), and 5 min after the skin incision (T_5) a median of 26.0 ± 4.2 DS (Fig. 2). Having considered the above BIS values too low compared to the 40–60 standard relative to an appropriate anesthesia plan, it was decided to reduce the end-tidal concentration of sevoflurane to 2% ($T_{\text{sevo}2}$). During this time we recorded BIS values of 26.5 ± 5.3 SD (Fig. 3). At the end of the surgery, about 75 min after induction, we stopped the administration of sevoflurane (T_{recovery}) until the child woke up. The median BIS values recorded were 29.5 ± 8.1 DS with a maximum of 47 and a minimum of 17 (Fig. 4). The total BIS values recorded related to the whole duration of the operation showed an excessive depth of anesthesia with median values of 27 ± 6.3 SD (Fig. 5).

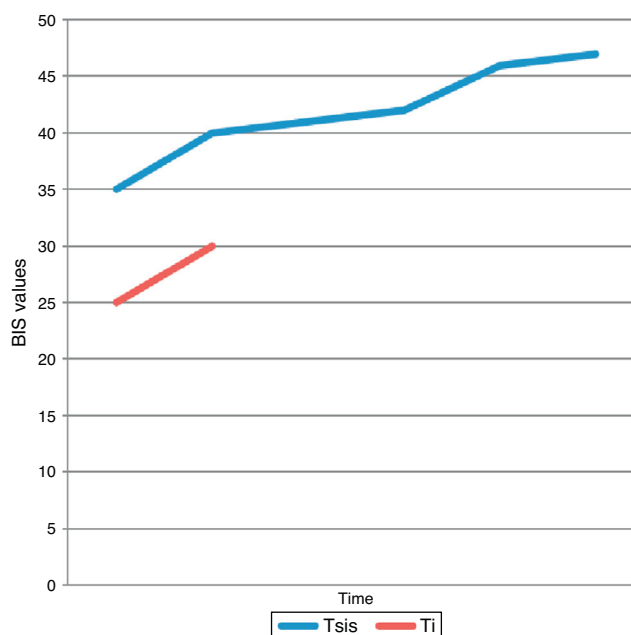


Figure 1 BIS values at the time of induction (T_i , 27.5 ± 3.5 DS) and surgical incision of the skin (T_{sis} , 41.5 ± 4.3 DS).

The awakening took place without complications and in the absence of agitation or seizures. Throughout the duration of the surgery respiratory and hemodynamic parameters were all within the normal range: heart rate 81.3 ± 3.3 SD, systolic blood pressure 101.3 ± 2.0 SD, diastolic blood pressure 52.0 ± 2.3 SD, mean arterial pressure 68.5 ± 1.8 SD (Fig. 6). During the time ($T_{\text{sevo}2}$), an electroencephalography was recorded (EEG) that demonstrated an epileptiform EEG activity with spikes (Fig. 7).

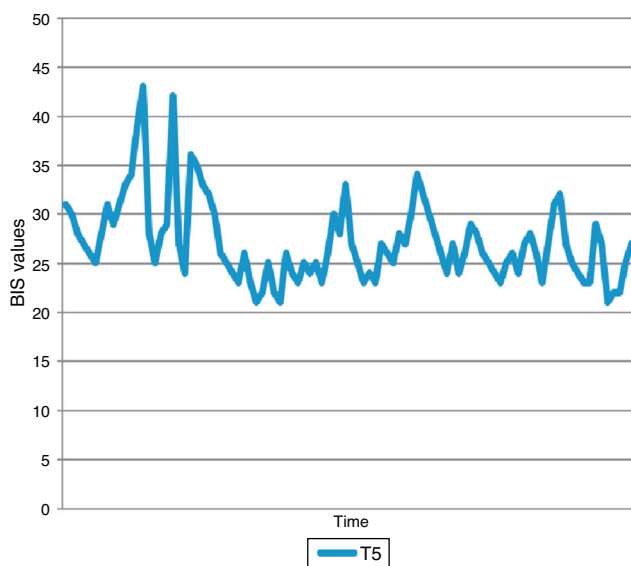


Figure 2 BIS values 5 min after the incision of the skin (T_5 , 26.0 ± 4.2 DS).

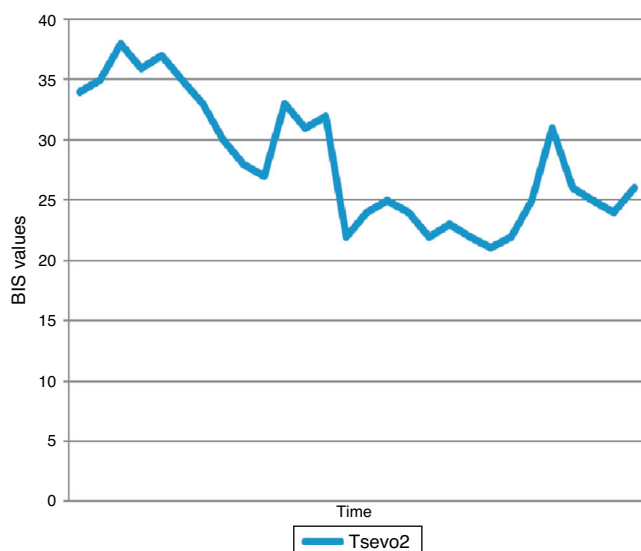


Figure 3 BIS values with 2% end-tidal sevoflurane (T_{sevo2} , 26.5 ± 5.3 SD).

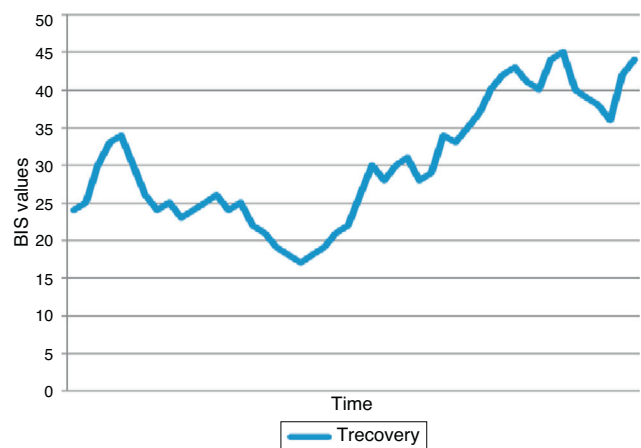


Figure 4 BIS values during the recovery of the patient ($T_{recovery}$, 29.5 ± 8.1 DS).

Discussion

The literature lacks studies on BIS monitoring in pediatric patients with congenital brain disease undergoing general anesthesia for surgery. Consequently it is very difficult to interpret the mechanisms by which such monitoring may be subject to change or alteration under anesthesia.⁵ The BIS expresses the depth of anesthesia with a numeric value ranging from 0 (deep anesthesia) to 100 (awake patient), while values between 40 and 60 are considered ideal for an adequate surgical anesthesia. In principle, the BIS values recorded in the pediatric age are inversely proportional to the concentration of end-tidal sevoflurane and correlate

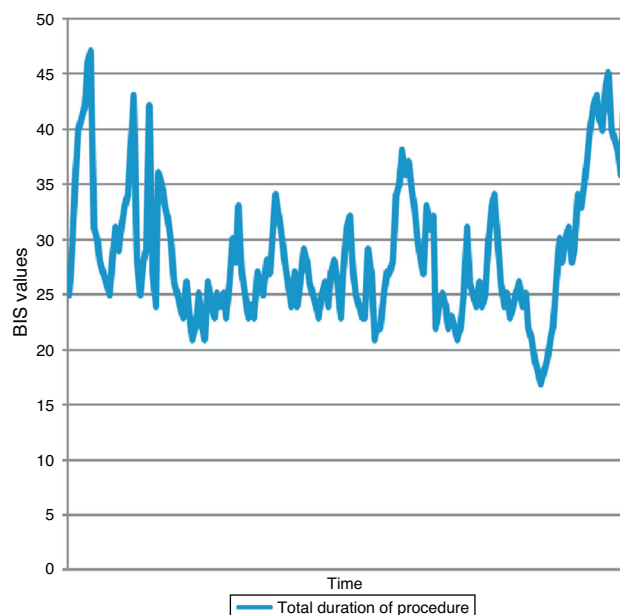


Figure 5 BIS values during all the time of surgical procedure (27 ± 6.3 SD).

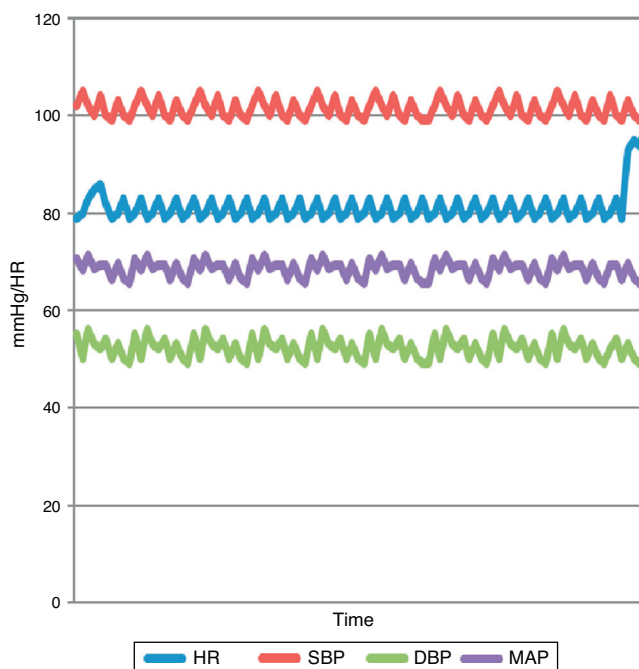


Figure 6 Hemodynamic parameters recorded during all the time of surgical procedure (HR, heart rate; SAP, systolic arterial pressure; DAP, diastolic arterial pressure; MAP, middle arterial pressure). HR 81.3 ± 3.3 SD, SBP 101.3 ± 2.0 SD, DBP 52.0 ± 2.3 SD, MAP 68.5 ± 1.8 SD.

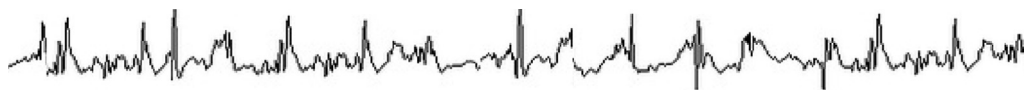

Figure 7 Epileptiform discharges observed during the time T_{sevo2} .

much better with changes in blood pressure and heart rate. In addition, the end-tidal concentration of sevoflurane which corresponds to a BIS of 50 (95%) is higher in children under two years compared to those who are older (1:55 versus 1:25%). In the recovery phase changes in the BIS are more progressive in older children compared to the smaller ones which show instead an on-off profile.⁶

In our case, despite having used higher end-tidal sevoflurane concentrations compared to those indicated above, from the time of induction to the awakening stage, the total BIS values recorded related to the duration of the operation showed an excessive depth of anesthesia with median values of 27 ± 6.3 SD. This data can be understandable during the early stages of anesthesia, induction in particular (T_i 27.5 ± 3.5 DS), when the concentrations of sevoflurane need to be higher. In subsequent stages, especially at T_{sevo2} time, we would have expected an increase in the BIS values after reducing the end-tidal concentration of sevoflurane. In contrast, the BIS recorded median values paradoxically lower (T_{sevo2} 26.5 ± 5.3 DS). Similarly, during the awakening, BIS values were rather low ($T_{recovery}$ 29.5 ± 8.1 DS) instead of nearing 60 which normally indicates the resumption of patient consciousness. The relatively higher BIS value, and thus closer to the range of 40–60, was found only at the moment of the incision of the skin (T_{sis} 41.5 ± 4.3 DS) although the BIS has no specificity in the prediction of response to nociceptive stimuli as it is a value more or less insensitive to narcotics while reflecting the hypnotic state.

The mechanism and the possible causes of this abnormal response can be demonstrated, in our opinion, in a detailed analysis of the trends of BIS values in the different observation times. In particular, in T_5 , T_{sevo2} , and $T_{recovery}$ (Figs. 2–4) we experienced rapid variability with sudden falls and repetitive values of BIS. There was not artifacts, and the patient was otherwise well curarized: signal quality index (SQI), electromyograph (EMG), suppression ratio value (SRV) showed a good quality of signal.

This fact brings us to another published case report, although on an adult patient, in which sevoflurane determined repetitive epileptiform electrical activity with sudden and rapid fall of the BIS values, which were resolved by administering antiepileptic drugs during surgery.⁷

It is well-documented that sevoflurane can stimulate epileptogenic activity^{8–10} and the electroencephalography recorded during the time T_{sevo2} demonstrated us an epileptiform EEG activity with spikes; in our case lobar holoprosencephaly is a disease that is accompanied by epilepsy. Although the child was already being treated with medications for an underlying disease, we must assume that they were not able to limit the rapid changes observed with the BIS and sevoflurane has played an important role. We have not used anti-epileptic drugs that would be useful as ex adjuvantibus criterion to demonstrate the nature of the changes in BIS values. In reality, from a clinical standpoint no convulsions were observed during the operation or during the awakening phase. It is likely that the epileptic activity was

a neuroelectric manifestation detected by the BIS. Finally, the good hemodynamic stability throughout the operation confirms that the concentrations of sevoflurane are better related to the BIS than the variations of blood pressure and heart rate in the pediatric patient.

Conclusions

The BIS is a very useful monitoring tool for assessing the degree of depth of anesthesia and to analyze the electroencephalographic variations of anesthetics. Particular attention should be given to patients with congenital disorders of the central nervous system in which the BIS may give abnormal responses that do not reflect an accurate assessment of the depth of anesthesia. This is particularly important in the case of high concentrations of sevoflurane that may result in epileptogenic action. In these cases the choice of a different anesthetic technique should be taken into serious consideration.

Conflicts of interest

The author declares no conflicts of interest.

References

- Bellone S, De Rienzo F, Prodam F, et al. Etiopathogenetic advances and management of holoprosencephaly: from bench to bedside. *Panminerva Med.* 2010;52:345–54.
- Sury M. Brain monitoring in children. *Anesthesiol Clin.* 2014;32:115–32.
- Kim JK, Kim DK, Lee MJ. Relationship of bispectral index to minimum alveolar concentration during isoflurane, sevoflurane or desflurane anaesthesia. *J Int Med Res.* 2014;42:130–7.
- Nishiyama T. Composite-, plain-auditory evoked potentials index and bispectral index to measure the effects of sevoflurane. *J Clin Monit Comput.* 2013;27:335–9.
- Rodriguez RA, Hall LE, Duggan S, et al. The bispectral index does not correlate with clinical signs of inhalational anesthesia during sevoflurane induction and arousal in children. *Can J Anaesth.* 2004;51:472–80.
- Denman WT, Swanson EL, Rosow D, et al. Pediatric evaluation of the bispectral index (BIS) monitor and correlation of BIS with end-tidal sevoflurane concentration in infants and children. *Anesth Analg.* 2000;90:872–7.
- Chinzei M, Sawamura S, Hayashida M, et al. Change in bispectral index during epileptiform electrical activity under sevoflurane anesthesia in a patient with epilepsy. *Anesth Analg.* 2004;98:1734–6.
- Constant I, Seeman R, Murat I. Sevoflurane and epileptiform EEG changes. *Paediatr Anaesth.* 2005;15:266–74.
- Särkelä MO, Ermes MJ, van Gils MJ, et al. Quantification of epileptiform electroencephalographic activity during sevoflurane mask induction. *Anesthesiology.* 2007;107:928–38.
- Schultz A, Schultz B, Grouven U, et al. Epileptiform activity in the EEGs of two nonepileptic children under sevoflurane anaesthesia. *Anaesth Intensive Care.* 2000;28:205–7.