



# REVISTA BRASILEIRA DE ANESTESIOLOGIA

Official Publication of the Brazilian Society of Anesthesiology  
[www.sba.com.br](http://www.sba.com.br)



## SCIENTIFIC ARTICLE

# Evaluation of brachial plexus fascicles involvement on infraclavicular block: unfixed cadaver study



Luiz Carlos Buarque de Gusmão<sup>a,b</sup>, Jacqueline Silva Brito Lima<sup>a</sup>,  
Jeane da Rosa Oiticica Ramalho<sup>a</sup>, Amanda Lira dos Santos Leite<sup>a,\*</sup>,  
Alberston Maylson Ramos da Silva<sup>a</sup>

<sup>a</sup> Universidade Federal de Alagoas (UFAL), Maceió, AL, Brazil

<sup>b</sup> Colégio Brasileiro de Cirurgiões, Maceió, AL, Brazil

Received 24 March 2014; accepted 2 June 2014

Available online 17 February 2015

### KEYWORDS

Regional anesthesia;  
Brachial plexus;  
Block infraclavicular

### Abstract

**Background and objectives:** This study shows how the diffusion of the anesthetic into the sheath occurs through the axillary infraclavicular space and hence proves the efficacy of the anesthetic block of the brachial plexus, and may thereby allow a consolidation of this pathway, with fewer complications, previously attached to the anesthesia.

**Materials and methods:** 33 armpits of adult cadavers were analyzed and unfixed. We injected a solution of neoprene with latex dye in the infraclavicular space, based on the technique advocated by Gusmão et al., and put the corpses in refrigerators for three weeks. Subsequently, the specimens were thawed and dissected, exposing the axillary sheath along its entire length.

**Results and discussion:** Was demonstrated involvement of all fasciculus of the plexus in 51.46%. In partial involvement was 30.30%, 18.24% of cases the acrylic was located outside the auxiliary sheath involving no issue.

**Conclusions:** The results allow us to establish the infraclavicular as an effective and easy way to access plexus brachial, because the solution involved the fascicles in 81.76% partially or totally, when it was injected inside the axillary sheath. We believe that only the use of this pathway access in practice it may demonstrate the efficiency.

© 2014 Sociedade Brasileira de Anestesiologia. Published by Elsevier Editora Ltda. All rights reserved.

\* Corresponding author.

E-mail: [amandaleite23@gmail.com](mailto:amandaleite23@gmail.com) (A.L.d.S. Leite).

**PALAVRAS-CHAVE**

Anestesia regional;  
Plexo braquial;  
Bloqueio  
infraclavicular

## Avaliação do envolvimento dos fascículos do plexo braquial no bloqueio por via infraclavicular: estudo em cadáveres não fixados

**Resumo**

*Justificativa e objetivos:* Procuramos demonstrar como ocorre a difusão do anestésico no interior da bainha axilar, quando se utiliza o bloqueio por via infraclavicular, através da fossa infraclavicular e, conseqüentemente, provar a eficácia dessa via, podendo, com isso, permitir uma consolidação da utilização desse acesso, com redução das complicações.

*Materias e método:* Foram utilizadas 33 axilas de cadáveres adultos não fixados. Injetamos uma solução de neoprene látex com corante na fossa infraclavicular, baseando-se na técnica preconizada por Gusmão e col, e colocamos os cadáveres em geladeiras por três semanas. Posteriormente, as peças foram descongeladas e dissecadas, expondo a bainha axilar em toda sua extensão.

*Resultados e discussão:* Foi demonstrado envolvimento de todos os fascículos do plexo em 51,46%. Em 30,30% houve envolvimento parcial, e em 18,24% dos casos o acrílico foi localizado fora da bainha axilar, não envolvendo nenhum fascículo.

*Conclusões:* Os dados obtidos permitem estabelecer a via infraclavicular como uma via eficaz e de fácil acesso ao plexo braquial, visto que a solução injetada envolveu os fascículos em 81,76% parcialmente ou totalmente, quando era injetada dentro da bainha axilar. Acreditamos que apenas a utilização desta via de acesso na prática poderá demonstrar a eficiência da mesma.

© 2014 Sociedade Brasileira de Anestesiologia. Publicado por Elsevier Editora Ltda. Todos os direitos reservados.

**Introduction**

Over the years, brachial plexus blockade by supraclavicular and axillary routes has presented a number of complications and failures, bringing back the use of the infraclavicular route.<sup>1</sup>

The infraclavicular brachial plexus block was initially advocated by Hirschel<sup>2</sup> in 1913. In 1917, Bazy<sup>3</sup> introduced a needle below the clavicle, in a "anesthetic line" drawn between the anterior tubercle of the sixth cervical vertebra and the coracoid process. In 1918, Babitsky<sup>4</sup> injected the anesthetic between the angle formed by the 2nd rib and the clavicle.

In 1922, Labat<sup>5</sup>, after injecting the anesthetic at the same point recommended by Bazy, flexed the arm toward the chest and performed another injection of the same solution.

In 1924, Balog<sup>6</sup> modified Bazy's technique, but the needle was introduced toward the rib cage, until it touches the second rib, and he retreated the needle a little and deposited the anesthetic.

In 1973, Raj et al.<sup>7</sup> introduced the needle at a midpoint of the clavicle, turning it to the side to prevent puncturing the chest wall.

Sims<sup>8</sup>, 1977, modified the technique by Raj et al. using a standard 3.8 cm needle which directed downward, outward, and backward reached the brachial plexus 2–3 cm after having passed the skin. He emphasizes that it is a rapid, easy and consistent access route for blockade performance.

Whiffler<sup>9</sup>, 1981, drew a line between the subclavian and axillary arteries, and the puncture was made at the point that this line crossed the coracoid process and reported success in 92.5% of cases and arterial puncture in 50%.

In 1995, Kilka et al.<sup>10</sup> reported that the infraclavicular brachial plexus block have lower risk of pneumothorax and low incidence of phrenic nerve block.

In 2001, Imbelloni et al.<sup>1</sup> determine that the injection should be at a point 1.5 cm below the site of union between the lateral third and the medial two-thirds of the clavicle, succeeding in 94% of cases.

Although there were fewer complications, cases of vascular and chest wall punctures with consequent pneumothorax were still reported.<sup>11</sup>

In 2002, Gusmão et al.<sup>11</sup> used one hundred fixed cadavers and performed infraclavicular fossa dissection, which was present in 96% of cases, determining that brachial plexus block by this route should be performed after finding the angle formed by the junction of the anterior margin of the deltoid muscle and the clavicle, draw a bisector from the angle to the fossa center, measuring about 2.21 cm, and enter the needle perpendicular to the skin at this site with a depth of 3.0–3.5 cm, piercing the axillary sheath and reaching the brachial plexus, which are located at this level, laterally to the axillary vessels.

Verifying that brachial plexus in most cases lies within the infraclavicular fossa and that the blockade by this access route reaches the brachial plexus fasciculi with few failures and without the complications described in the interscalene, supraclavicular, and axillary techniques, it remained to be demonstrate how the anesthetic spread behaves by using the above described route.

**Materials and methods**

Complying with what determines the Federal Law N° 8501, November 30, 1992 (Annex), and after institutional

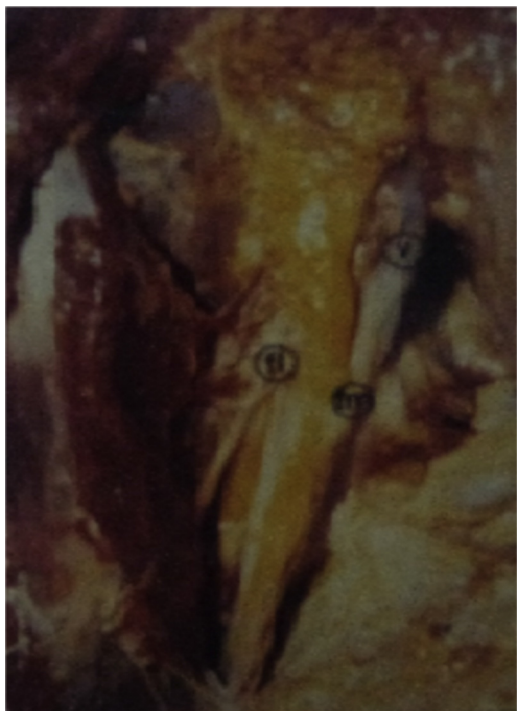approval, 33 axillary regions of unfixed adult cadavers of both sexes donated by the Instituto Médico Legal Estácio de Lima to the Medical School of the Universidade Federal de Alagoas were used in this study.

The infraclavicular route was used, through the infraclavicular fossa, as stated by Gusmão et al.<sup>11</sup> Instead of the anesthetic, we used a dilute solution of neoprene latex with dye (30ML). After injection, the bodies were placed into the refrigerator, where they remained for about three weeks. After the neoprene latex solidification period, the bodies were thawed. Subsequently, a large incision from the neck to the armpit was performed, exposing the full extent of the axillary sheath, as well as its content. Such access has allowed us to observe and analyze the injected solution diffusion along the axillary sheath, as well as the brachial plexus fasciculi involved.

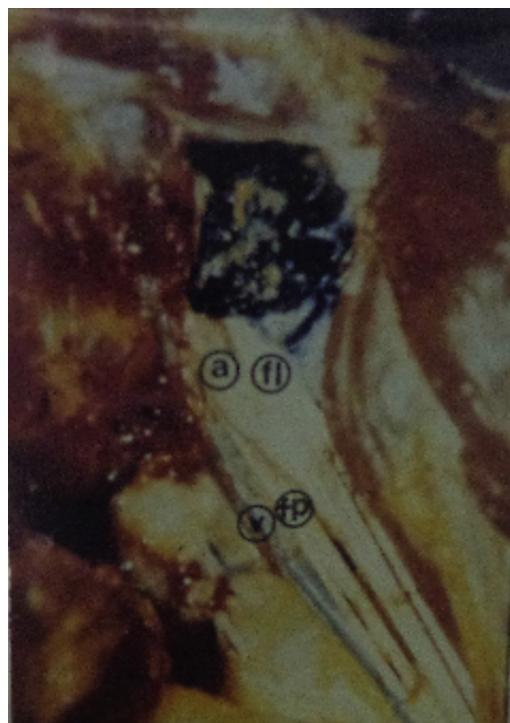
## Results

The findings in the 33 injected axillae were as follows:

- In 51.46% of cases (17 axillae) there was 100% involvement of brachial plexus fasciculi (Figs. 1 and 2).
- In 30.30% of cases (10 axillae), the anesthetic partially involved the brachial plexus fasciculi as follows: in three axillae there was diffusion only of the posterior and medial fasciculi; in three axillae, the solution only circled the lateral fasciculus; in two axillae, only the lateral and posterior fasciculi were involved; in two axillae, only the posterior fasciculus was bathed in solution.



**Figure 1** Total involvement of the brachial plexus (yellow). V, axillary vein; fl, lateral fasciculus; fm, medial fasciculus.



**Figure 2** Total involvement of brachial plexus fasciculi (blue). V, axillary vein; a, axillary artery; fl, lateral fasciculus; fp, posterior fasciculus.

In 18.24% of cases (six axillae), almost all of the solidified solution was located outside the axillary sheath, and when the acrylic was into the sheath, no fasciculus was involved.

## Discussion

Since the 70s, studies have demonstrated the superiority of the infraclavicular brachial plexus block. Raj<sup>7</sup> has been successful in blocking all brachial plexus in most cases (95%), arguing that this approach is quite safe for brachial plexus block, allowing the adequate anesthetic block of the upper limb.

The infraclavicular anesthetic blockade techniques reported in the literature use several points below the clavicle, which sometimes are over the pectoralis major muscle, sometimes beside the coracoid process, or over the infraclavicular fossa.<sup>11</sup> In several recommended access routes the anesthetic injection site was not always within the infraclavicular fossa and there is no information about the fossa site through which the brachial plexus and axillary vessels pass. The access route proposed by Gusmão et al.<sup>11</sup> shows that, in most cases, the brachial plexus fasciculi are located in this fossa and, for security in the implementation of the blockade by the anesthesiologist, it was given the information not only of the depth where the plexus is located, but also its location within the infraclavicular fossa, from the angle formed by the deltoid muscle and the clavicle.

In our study, although we have injected the solution in cadavers, whose diffusion is inferior to that of a patient due to rigor mortis, there was total or partial involvement of brachial plexus fasciculi in 81.76% of cases.

The partial involvement of fasciculi, and cases in which the solution was located outside the sheath, was in part due to the fact that puncture was not performed by a single investigator, and failure may have occurred in the depth of needle insertion.

We argue that the solution located outside the axillary sheath may have resulted from leakage because, although some authors believe that this sheath forms an enclosed space,<sup>12</sup> dissections in laboratory showed that the solution injected into it could be leaked through the holes drilled by vascular and nervous structures transfixing the sheath.

Based on the results and using the access route proposed by Gusmão et al.,<sup>11</sup> we observed that it allows easy access to brachial plexus, as the injected solution involved the fasciculi in 81.76% of cases, with 51.46% totally involved and 30.30% partially involved when it was injected into the axillary sheath.

We believe that the use of this route, performed by anesthesiologists, yields the same results reported by Imbelloni et al.<sup>1</sup>

### Conflicts of interest

The authors declare no conflicts of interest.

### References

1. Imbelloni LE, Beato L, Gouveia MA. Bloqueio do Plexo Braquial por via infraclavicular: Abordagem Antero-Posterior. *Rev Bras Anesthesiol.* 2001;51:235–43.
2. Hirschel G. *Handbook of local anesthesia.* Wiesbaden: JF Bergman; 1913.
3. Bazy YL. *L'anesthesia regionale.* Paris: G Doin; 1917.
4. Babitszky P. A new way of anesthesia the brachial plexus. *Zentralbl F Chir.* 1918;45:215–7.
5. Labat G. *Regional anesthesia.* Philadelphia: WB Saunders; 1922.
6. Balog A. Conduction anesthesia of the infraclavicular portion of the brachial plexus. *Zentralbl Chir.* 1924;51:1563–4.
7. Raj PP, Montgomery SJ, Nettles D, et al. Infraclavicular brachial plexus block – a new approach. *Anesth Analg.* 1973;52:897–904.
8. Sims JK. Modification of landmarks for infraclavicular approach to brachial plexus block. *Anesth Analg.* 1977;56:554–5.
9. Whiffler K. Coracoid block: a safe and easy technique. *Anesth Analg.* 1981;53:845–8.
10. Kilka HG, Geiger P, Mehrkens HH. Infraclavicular vertical brachial plexus blockade. A new method for anesthesia of the upper extremity. An anatomical and clinical study. *Anaesthesist.* 1995;44:339–44.
11. Gusmão LCB, Lima JSB, Prates JC. Bases anatômicas para o bloqueio anestésico do plexo braquial por via infraclavicular. *Rev Bras Anesthesiol.* 2002;52:348–53.
12. Drake RL, Adam WM, Vogl W. *Gray's Anatomia Para Estudantes.* São Paulo: Ed. Elsevier; 2005.