



REVISTA BRASILEIRA DE ANESTESIOLOGIA

Official Publication of the Brazilian Society of Anesthesiology
www.sba.com.br



REVIEW ARTICLE

Digital block with or without the addition of epinephrine in the anesthetic solution



Almiro dos Reis Júnior^{a,b,c,*}, Denise Quinto^{a,b}

^a Serviço Médico de Anestesia (SMA), São Paulo, SP, Brazil

^b Hospital Alemão Oswaldo Cruz, São Paulo, SP, Brazil

^c Sociedade de Anestesiologia do Estado de São Paulo (Saesp), São Paulo, SP, Brazil

Received 27 October 2013; accepted 3 December 2013

Available online 25 November 2015

KEYWORDS

Anesthesia, regional;
Local anesthetics,
cocaine, lidocaine,
bupivacaine,
ropivacaine;
Surgery, fingers;
Ischemia,
epinephrine

PALAVRAS-CHAVE

Anestesia, regional;
Anestésicos locais,
cocaína, lidocaína,
bupivacaína,
ropivacaína;

Abstract

Background and objectives: Review of various techniques for digital blocks with local anesthetic, with or without epinephrine.

Contents: Description of various procedures and comparison of results reported in the literature, mainly on latency and quality of anesthesia, details on vasoconstrictor effect of epinephrine, intraoperative bleeding, necessity of tourniquet use, duration of anesthesia and postoperative analgesia, blood flow and digital SpO₂ behavior, local and systemic complications, and also approaches and drugs to be used in certain situations of ischemia.

Conclusions: The advantages of adding epinephrine to the anesthetic solution are minor when compared to the risks of the procedure, and it seems dangerous to use a vasoconstrictor in the fingers, unless the safety of the technique and the possibility of discarding the tourniquet are definitely proven.

© 2014 Sociedade Brasileira de Anestesiologia. Published by Elsevier Editora Ltda. All rights reserved.

Bloqueios em dedos de mãos com epinefrina incluída ou não nas soluções anestésicas

Resumo

Justificativa e objetivos: Revisão das diversas técnicas para bloqueios em dedos de mãos, com anestésico local associado ou não à epinefrina.

Conteúdo: São descritos os procedimentos usados e comparados os resultados obtidos na literatura, principalmente em relação a: latência e qualidade da anestesia, detalhes sobre o efeito vasoconstritor da epinefrina, sangramento intraoperatório, necessidade ou não do uso de torniquete, duração da anestesia e da analgesia pós-operatórias, comportamento do fluxo arterial e

* Corresponding author.

E-mail: almiroidosreisjr@uol.com.br (A. Reis Júnior).

Cirurgia,
dedos de mãos;
Isquemia,
epinefrina

da SpO₂ digitais, complicações locais e sistêmicas e, ainda, condutas e medicamentos a serem usados em determinadas situações de isquemia.

Conclusões: As vantagens da inclusão de epinefrina na solução anestésica são de pouca importância quando comparadas aos riscos do procedimento e parece perigoso usar o vasoconstritor em dedos de mão, a não ser que fiquem definitivamente comprovadas a inocuidade da técnica e a possibilidade do descarte do torniquete.

© 2014 Sociedade Brasileira de Anestesiologia. Publicado por Elsevier Editora Ltda. Todos os direitos reservados.

Introduction

Blockades are used in fingers for small surgical interventions, with or without the use of digital tourniquets, since the use of general anesthesia for such surgical procedures is of greater risks, unnecessary most of the time and far more expensive. However, due to the possibility of serious consequences, digital anesthetic blocks, particularly those with the use of tourniquet, should be done carefully and with good knowledge of the regional anatomy and its contraindications.

The latest national treaties of anesthesiology assess the subject in an extremely simplified form. So it seems to be the time to update it, as it is of interest not only to orthopedic surgeons, hand surgeons, and dermatologists specialize in nail disease processes, but also for anesthesiologists who should be aware of these subjects as they may be involved in cases of complications for having performed such anesthetic acts or just taken part in the surgery.

Digital anesthetic blocks consist fundamentally of local anesthetic deposition in the vicinity of nerves; to this end, first, major regional anatomical details should be well known (Fig. 1). The dorsal digital nerves derive from the radial and ulnar nerves, pass through the dorsolateral region of the fingers, and innervate almost all regions of fingers to its proximal joints, as the distal regions of the index, middle, and part of the ring fingers are innervated by the median nerve.¹⁻³ The median and ulnar nerves give rise to digital nerves that supply most of the palmar, adjacent side, ends of fingers, and nail bed regions; they are accompanied by blood vessels and pass through the ventrolateral regions of the fingers and the side of the flexor tendon sheaths.

Techniques for digital anesthetic blocks

First, one must know the contraindications for performing these anesthetic blockades. These are as follows: absolute, such as patient's refusal to undergo the procedure, peripheral vascular disease in the region, and infection next to the injection site. Relative, when it is absolutely necessary to test nerve function early in the postoperative period due to blockade establishment of sensory and motor conduction whenever this condition can mask the establishment of a postoperative compartment syndrome. And in a patient already with nerve damage or paresthesia, due to the always present possibility of causing nerve injury.¹⁻⁴ There

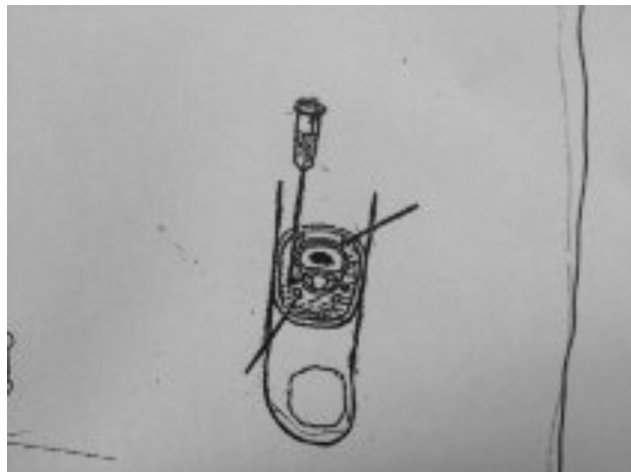

Figure 1 Cross section of the base of proximal phalanx of finger. Note the positioning of dorsal (right arrow) and ventral (left arrow) digital nerves and vessels. Also note the needle for these nerves blockade by dorsolateral route of finger base. Modified from Figures 10–17 (A) by Ref. 1.

are several techniques with minor modifications that vary from author to author.^{1-3,5-9}

The subcutaneous block of palmar and dorsal digital nerves can be done by inserting a 25G and 16 mm needle at a point of the lateral region of the finger dorsal base for infiltration of the entire region (Fig. 2). Then, one of the finger side regions is punctured (Fig. 2), without pain, and advanced toward the palm and moved vertically to the side of the flexor tendon sheath until resistance is felt on palmar dermis or pressure on "protective" finger placed under the patient's finger and directly opposite to the needle path (Fig. 2). After it is withdrawal over 2–3 mm, 1 mL of the anesthetic solution is deposited under the skin on the palm side of the hand to anesthetize the palmar digital nerve and another 1 mL just under the needle entry point to block the dorsal digital nerve.¹ The same procedure must be reproduced on the other side. Some practitioners prefer the palmar region approach to enable the reduction of nerve and digital artery lacerations by the needle bevel; however, this area is much more sensitive and creates more discomfort to the patient and it is technically a bit more difficult to apply because the skin of that hand side is thicker.² Optionally, the injection can be done at the proximal region of the finger crease with the use of needle



Figure 2 Subcutaneous blockade of the dorsal and palmar nerves of right index finger. Illustration: Gladys N. dos Reis.

with the same characteristics mentioned above; 1 mL of anesthetic solution is injected superficially to block the dorsal digital nerve and the needle is advanced to block the palmar digital nerve. This procedure must be repeated on the other side after the needle has been withdrawn to the skin and redirected to the opposite side of the finger back to superficially apply another 1 mL of anesthetic solution.² Care must always be exercised with the anesthetic solution volumes administered in order not to create a compression circumferential ring of neurovascular bundles.

The transmetacarpal technique^{1,3} for digital nerve block is performed with fingers extended, by the dorsal side of the hand, thinner than the palmar, approximately at 1 cm of metacarpophalangeal joints and half-way between the metacarpal bones (Fig. 3). The technique involves the introduction and advancement of the needle until the palmar aponeurosis resistance is perceived, and then 2–3 mL of anesthetic solution without epinephrine should be injected as the needle is slowly withdrawn. The same procedure is done on the other side of the finger. The procedure can be done by the palm side of the hand and, similarly, 2–3 mL anesthetic solution must be injected just behind the metacarpal heads, which fully anesthetizes the common digital nerve that supplies the finger, which, however, it is less comfortable for the patient, due to the skin thickness in this region, as noted above. An interesting detail was proposed to facilitate the transmetacarpal technique induction,³ consisting of holding the patient's hand by the fingers with the non-dominant hand of the operator and marking two points on each side of the metacarpophalangeal joints; the patient's hand is then extended and the two marks indicate the needle entry points (Fig. 4). The main advantages of the latter technique are: the punctures are made with the patient's hand in a position which helps to stabilize it, the points for injections are more accurate and easily determined, the risk of neurovascular lesion is smaller and it's easier for the digital block to be taught.³

The transthecal method was described in 1990 when the quick installation of anesthesia throughout the finger was seen after the application of a steroid and lidocaine mixture to the flexor tendon sheath for trigger finger treatment.⁵

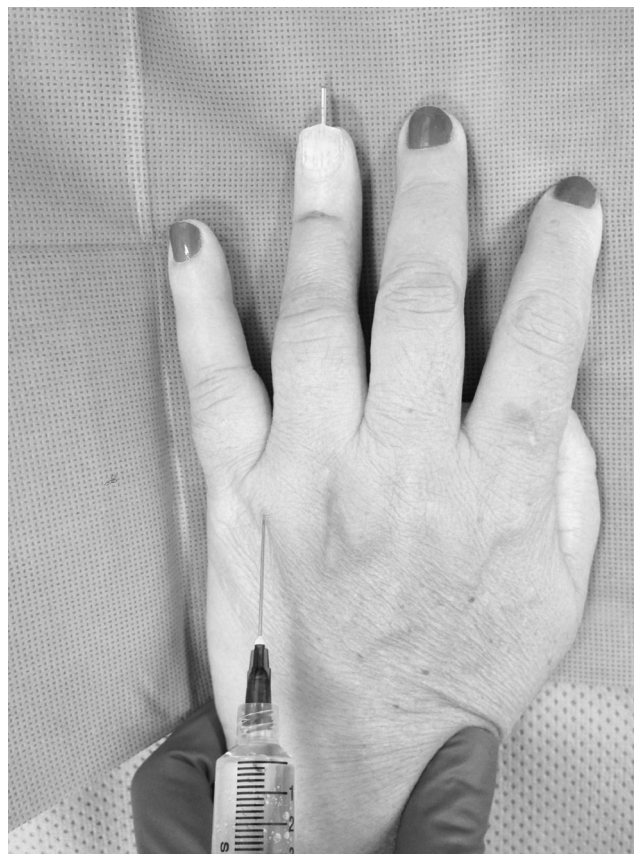

Figure 3 Blockade of ring finger by transmetacarpal route. Needle insertion is through the dorsal side of the hand, about 1 cm from metacarpophalangeal joint and halfway between two metacarpal bones. Details in the text. Photo courtesy of the hand surgeon Dr. Nivea Gitahy Rizzi.

Since then, this tendon sheath is punctured for anesthetic solution administration at the level of the palmar digital crease; the needle should penetrate this tendon sheath up to bone contact is felt^{2,3,5,8,9} (Fig. 5). Then, the needle should be slowly removed until the anesthetic solution (about 2 mL) is easily administered into the space between the periosteum and flexor tendon. As the anesthetic is applied, there is a local turgidity and slight flexion of the finger. This method's advantages include single injection, no risk of direct mechanical trauma of the neurovascular bundle, and rapid deployment of anesthesia. However, the procedure includes risks such as tendon injury and potential infection in a closed space because it violates the flexor synovial sheath^{2,3}; besides, comparison between subcutaneous and transthecal blocks used in 162 volunteers showed that the latter anesthetic method produces more pain during injection, a discomfort that persists for up to 24 h.⁶

Recently, a new finger block technique was proposed using a single injection of 1% lidocaine (3 mL) with epinephrine (1:100,000) to be applied to the subcutaneous space of the midpoint of the interdigital palmar crease (3 mL) (Fig. 6).^{9,10} Research in this regard was held in nine volunteers and simultaneously in middle fingers of the right (without epinephrine) and left hand (with epinephrine); shortly after the injection, a completely white area appeared around the point of the solution

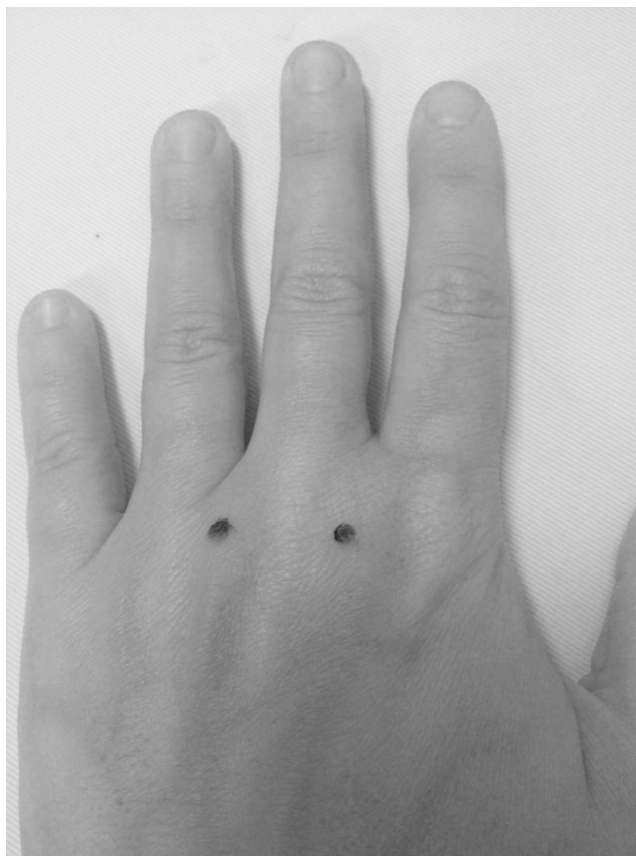

Figure 4 Transmetacarpal blockade with outstretched hand. The reference points were marked to facilitate the anesthetic solution application. Details in the text.

injection with epinephrine. The anesthesia lasted 48 min when epinephrine was not used and 280 min when the vasoconstrictor was used. With the highest concentration and dose of lidocaine (2% 5.4 mL) with epinephrine 1:100,000, anesthesia can last up to twice that time.¹⁰

One option to digital blocks is the use of intravenous regional anesthesia,¹¹ which, when used in a finger, has no truncal but only infiltrative action (Fig. 7). It is induced after puncturing the vein on finger dorsum, almost always easy with 27G needle or butterfly needle of similar gauge, exsanguination by rubbing the finger in the distal-proximal direction with the operator's index finger circularly around it, with delicate elastic band or even just by gravity, rapid application of tourniquet in its root, secure with hemostat clamp, and administration of 2–3 mL, according to the finger size, of any local anesthetic currently in use, always without epinephrine; anesthesia is immediately established. The great advantage of this anesthetic method is to avoid totally the possibility of digital neurovascular bundle injury. The disadvantages of intravenous regional anesthesia for fingers are the short duration of postoperative analgesia and tourniquet pain (required) after prolonged use, which can be avoided by applying a second tourniquet slightly more distal and anesthetic followed by deactivation of the tourniquet previously installed.¹¹ It is worth noting that in the 1980s a comprehensive technology was created for the procedure.¹²

Where several fingers are involved in the surgery, a good option is a blockade at the wrist level.¹

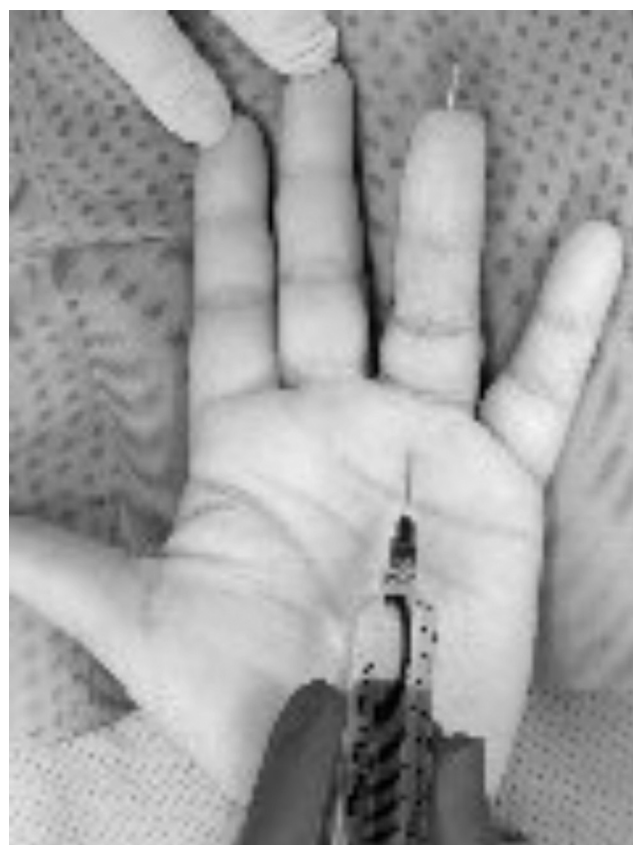

Figure 5 Transthecal blockade. The puncture for anesthetic solution administration is performed in the sheath of the finger flexor tendon (proximal level of the palmar digital crease or a little more distal). Photo courtesy of the hand surgeon Dr. Nivea Gitahy Rizzi.

The most important recommendations for anesthetic blocks of fingers associated with tourniquet ischemia are^{1,2,4,11,12}: (1) basic notions of regional neurovascular anatomy; (2) experience with the procedures of anesthesia and ischemia; (3) comply with the contraindications of anesthesia and ischemia; (4) always use short, thin needles to avoid serious bilateral lesions of vessels and digital nerves; (5) use one of several local anesthetics available without epinephrine, such as 2% lidocaine 0.75% ropivacaine or 0.5% bupivacaine; (6) injecting appropriate volumes of the anesthetic solution; (7) never apply circumferential blocks; (8) never perform it when there is infection at the injection site proximity; (9) perform it preferably at the level of metacarpal heads, which would be better than more distally; (10) always have on hand equipment for cardiopulmonary resuscitation; (11) know the pathophysiology of digital tourniquet ischemia; (12) practice digital tourniquet within the recommended technical standards, seek to keep it for no more than 20–30 min and take action to never forget it in loco; (13) give antibiotic, if necessary, before tourniquet application; (14) do not use constrictor dressings; (15) always check the finger perfusion after tourniquet removal; and (16) keep the limb elevated for a few minutes after the end of the surgery.



Figure 6 Location for hand finger block using only one local anesthetic injection into the subcutaneous space and applied approximately at the level of the midpoint of palmar interdigital crease.

Addition of epinephrine to anesthetic solution

It has always been notorious among us, and still is, the conduct not using epinephrine associated with local anesthetic for surgical procedures on fingers due to the potential risk of irreversible vascular spasm. However, it has been stated that

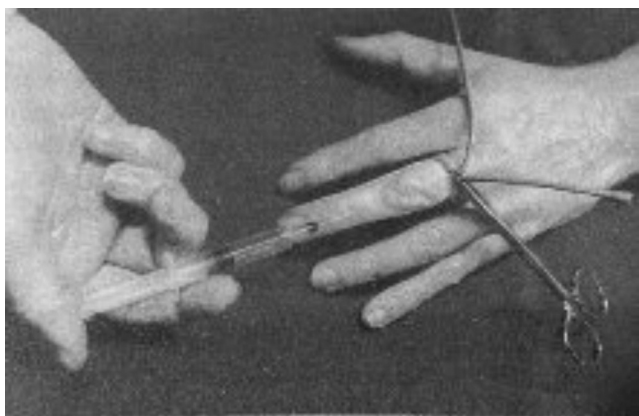


Figure 7 Digital intravenous regional anesthesia. Note the tubular rubber tourniquet kept by hemostat clamp and the anesthetic being administered in dorsal vein of middle finger. Reproduced from Ref. 11. With permission of the publisher.

“many doctors believe it because it was what they learned in medical schools worldwide”.

The main anesthesiology treatises and numerous articles published until recently do not admit the addition of epinephrine to anesthetic solutions for such surgeries; it is also pronounced in dermatology, plastic surgery, and hand surgery texts,^{1,2,11,12} despite, according to some, the lack of valid evidence in the literature about this concept.¹³ It is well known that this association is much more dangerous in patients with conditions that could impair finger perfusion, such as pheochromocytoma, hyperthyroidism, severe hypertension, heart disease or Raynaud’s phenomenon, sclerodactyly, and telangiectasia.^{14–17} It is true that the fingers have great ability to resist ischemic insults because of their structure, which has skin, bones, tendons, and ligaments, but not striated muscles, which are very sensitive to lack of oxygen,^{14,18} and that epinephrine actions are short-lived when used at very diluted solutions.^{18,19}

The review of the history of the use of local anesthetic associated with epinephrine shows that it never lost its dangerous reputation, which began more than a century ago.^{1,18,20} Isolated from the adrenal gland in crystalline form by Abel in 1897, initially named Takamina, epinephrine was patented in 1901 as Adrenaline. In 1903, Braun, creator of the term *conduction anesthesia*, inspired by Corning and Halsted ideas, popularized the addition of epinephrine in small quantities to cocaine solutions, the only local anesthetic available until the introduction of procaine by Einhorn in 1904, and created what he called *chemical tourniquet*, in order to slow the absorption of the local anesthetic and prolong its action. But, as a vasoconstrictor, cocaine produced the first gangrene as a digital block complication, which was followed by several other over the years, apparently exclusively involving epinephrine.^{1,13,18} Braun had already warned that the vasoconstrictor action was very intense and prolonged that could cause this complication, especially when the nutrition in the region is already impaired. About it, some believe that in the past epinephrine was imperfectly diluted in anesthetics, and differently from how they are prepared today¹⁸ or that the procaine was used after the expiration date, acidified and toxic, and thus contributed to the digital necrosis attributed to epinephrine.^{21,22} Thus, the discussion about the use of epinephrine in digital anesthetic block is not new; for example, in 1933 it was used (1:100,000) in more than 1500 patients, a period in which several cases of finger gangrene were described with and without the vasoconstrictor addition to the anesthetic solutions.¹⁸ Other agents, such as phenylephrine and norepinephrine, are ineffective regarding the effects achieved with epinephrine.^{13,23}

It seems worrying the number of authors who lately support and continue advocating the routine use of epinephrine and safety of this procedure, many claiming they had never recorded digital injuries, although some have seen it, as well as systemic effects, such as severe hypertensive crisis.^{14–18,22–30} Some of these authors believe that the risk of complications caused by the use of epinephrine in digital blocks is theoretical, that the myth of the danger of epinephrine application on fingers have died, that the concept reported by hundreds of authors that epinephrine should “never be used on fingers or toes, nose, ear, and penis” is disappearing, and “that future effort is needed to

convince skeptics that the myth is dead".^{13,20} But it is very possible that not all authors who have seen complications arising from the use of epinephrine in digital blocks reported their cases¹⁸; of course, those against the use of the vasoconstrictor published very little compared to what always seemed obvious to them.³

Reviews of the literature on digital anesthetic blocks with the addition of epinephrine performed from 1880 to 2000^{18,20,22} and between 1900 and 2000¹⁷ tried to understand whether the vasoconstrictor prohibition is based or not on well-documented cases. Another big review noted 48 cases of necrosis after digital blocks, particularly with cocaine, which is known to cause complications, most of which occurred decades ago and 21 cases involving epinephrine, many with unknown concentrations^{15,18}; one of such review¹⁵ concluded that no patient had finger infarction lidocaine and low doses of epinephrine, such as 1:100,000.

In recent years, numerous studies sought to compare digital blocks with local anesthetics with and without the addition of epinephrine, including volunteers, in order to obtain favorable or unfavorable information of this technique versus the classical, which does not include epinephrine, such as latency, quality and duration of anesthesia, epinephrine concentrations in anesthetic solutions that can be considered correct, important risk of finger ischemia, intraoperative bleeding, need for tourniquet use, requirement or not of additional anesthesia, postoperative analgesia time, and treatment of complications.^{15,18,24,27,28} Some of these studies are listed below.

In 2010, 1111 anesthetic blocks were performed in patients aged 6 months to 93 years, undergoing finger surgeries, using only the dorsal blockade or the transthecal technique and tourniquet²⁹; 611 subjects who received lidocaine without epinephrine (5.7 mL average) were compared with 500 subjects receiving lidocaine with epinephrine 1:100,000 (4.33 mL average) and none of them suffered finger loss resulting from the use of this type of anesthetic solution; besides, there was no need for drug treatment.

A prospective non-randomized study, for justified reasons, performed between 2002 and 2004, evaluated 3110 surgical procedures in hands (1270) or fingers (1340) with anesthetic blocks administered with lidocaine or bupivacaine and epinephrine, usually 1:100,000, and there was no loss of digital tissue.¹⁵ It has been suggested that if the cases in this study are added to the study cited above it would sum up 4221 patients (actually, 2451, as the rest were not properly on fingers), a large number of results would be obtained enough to deny the traditional dogma against the use of epinephrine in fingers. Medication to reverse vasoconstriction probably was not used on the grounds that if the ischemic events were significant, the authors probably would have used it, but have not registered their conduct.¹⁸

A study carried out in 2005 revealed that the vasoconstrictive effect of epinephrine (1:100,000) disappears in just over 6 h, the finger is occasionally bluish, especially when tourniquet is used, the color of that finger becomes equal to the color of the non-injected fingers of the same hand. Moreover, even when epinephrine was administered near the neurovascular bundles it is sometimes possible to see blood pulsing in the vessels bathed in the anesthetic solution,¹⁵ which supports research in which the digital arterial blood

flow was detectable in approximately 17% of patients who received epinephrine.³¹

The use of lidocaine with or without epinephrine was compared in some respects in 43 patients (50 fingers) in similar clinical conditions undergoing digital anesthetic blocks.²⁴ They were allocated into two groups: A and B. In Group A, lidocaine alone (2%, 1.5 mL) was used in each digital nerve and if necessary an additional 0.5 mL in each nerve. Group B received the same treatment with the addition of epinephrine (1:100,000) in the anesthetic solution. The results were: (1) after 10 min, surgical intervention could be initiated in only 48% of patients in Group A and 84% in Group B; (2) 24% of patients in Group A required one or more reinforcements to complete anesthesia compared with only 4% in Group B; (3) one hour after the anesthetic solution administration, the mean pain scores using a visual analog scale were 4.1 for Group A and 1.4 for Group B; (4) intraoperative bleeding significantly more important in Group A (20%) and it was necessary to use tourniquet or other measures; (5) the duration of postoperative analgesia was 2.4 h for patients in Group A and 4.6 h for Group B; and (6) one patient in each group had hypertensive crisis.

A study of 100 patients (106 digital blocks),¹⁹ aged 15–83 years, who received anesthetic solution of 2% lidocaine (2 mL) with epinephrine (1:80,000) infiltrated around each digital nerve and dorsum of the proximal phalanx (0.5 mL), always with the use of dental syringe and needle 27, reported complete anesthesia and a pale circumferential zone around the base of each finger blocked, certainly due to vasoconstriction. Specifically on finger arterial blood flow after blocking with lidocaine-epinephrine, it was noted in 10 patients that it declined rapidly within the first 5–10 min, increased gradually, and returned to normal within 60 min, that bleeding in surgical wounds were normal and the fingers become clinically well-perfused after every surgical intervention. It was also observed that for the periods immediately preceding the anesthetic block installation the mean systolic blood pressures were little reduced, and the digital extremity temperatures experienced negligible increases when measured after the occurrence of reactive hyperemia.

A study on blood gas parameters measured before and 15 min after digital blocks with lidocaine solutions with or without epinephrine reported that the SpO₂ slightly increased after the anesthetic blocks and, soon after, it had small reductions, but there were no significant differences between the two groups.²⁸

The users of local anesthetic combined with epinephrine state that many circumstances of finger gangrene after digital anesthetic blocks do not support the conclusion that the use of this vasoconstrictor was the cause of the observed lesions.¹⁸ There are case reports of finger necrosis with lidocaine without epinephrine, some of which apparently caused by the use of large volumes of anesthetic solution, vessel occlusion, postoperative burns, infections, and inappropriate application of tourniquets.¹⁴ Actually, it is well known that the origin of these complications may be multifactorial and not always solely due to epinephrine administration, even when it was used within the standards considered correct.¹⁸ Moreover, there are records of patients who received anesthetic solution with epinephrine inadvertently injected into digital arteries, in which case the vasoconstriction is immediately installed; however, the

fingers become red in less time than with the usual extravascular injection. It is possible that the shortest duration of this vasoconstriction may be related to the very low half-life of plasma epinephrine.¹⁵

Indeed, there are often doubts about the true causes of injuries making it difficult to diagnose it among many possibilities, such as the presence of peripheral vascular disease, excessive amounts of anesthetic solution in confined spaces, high mechanical pressure motivated by anesthetic block at the finger base, vascular injury caused by needle, burns, infections, and poorly maintained dressings. All in addition to the high pressure caused by very tight tourniquets of small width or for long time, and non-compliance with the recommendations for anesthetic block in fingers with the addition of epinephrine in the anesthetic solution, although it cannot be said that digital ischemia does not occur with the use of lower doses of epinephrine.^{1,14,15,18,23}

However, as a demonstration of the ischemia severity that can be caused by epinephrine when injected alone and/or accidentally on the finger, there is a considerable number of publications. In the literature (1900–2005), there are records of 59 patients in whom local anesthetics were administered with epinephrine in high concentration (1:1000); of these, 32 received no treatment, and none of them suffered digital necrosis, but had pain for four hours and neuropraxis for 10 weeks.²¹ Many of these complications involved equipment (EpiPen) containing epinephrine in high concentration (1:1000), most commonly used by dermatologists, allergists, and radiologists for treatment of allergic emergencies.^{21,32–40} The injected doses varied widely and the main symptoms were pain (86%), pallor (53%), and, to a lesser percentage, numbness, bruising, ischemia, and decreased capillary refill, which lasted for 2 h on average; no drugs were used in 77% of affected patients, but the remaining patients received glycerin paste, phentolamine, nitroglycerine plus phentolamine or terbutaline.^{30,33} Calcium channel blockers and topic glycerol trinitrate have also been used, but have often proved ineffective.³⁴

The following describes only two of the numerous situations that have occurred with such equipment (EpiPen). An X-ray technician suffered accidental injection of epinephrine in thumb pulp when handling absently the device (EpiPen), resulting in pallor, cold, and numbness in the affected area.³⁵ The clinical situation has not improved with an hour of heating so phentolamine and calcium channel blocker were used to combat the vasospasm effects. Phentolamine (5 mg) diluted in saline solution (9 mL) was administered in the thumb pulp and over the digital artery (total: 4 mL = 3.5 mg) and calcium blocker (90 mg) was used orally; there was immediate heating of the thumb. The patient was observed for two hours, during which the finger remained warm and rosy, and then she was discharged. Another accident, similar to the above, occurred with a nurse who handled incorrectly the same equipment (EpiPen) and injected epinephrine (1:1000) in the thumb of a teammate who was presenting with anaphylactic reaction by ingested food.³⁴ The thumb immediately became pale and without sensitivity and motor function. She was treated with stellate ganglion block and her thumb became well perfused and normal within hours.

As in the above two cases, whenever high doses of epinephrine are used, it is necessary to take immediate

measures to prevent irreversible digital ischemia,^{18,21,32,34} and the administration of phentolamine 1 mg diluted in saline solution 1 mL is recommended.²¹ However, many treat vasoconstriction only with heat and observation, and drug treatment (usually phentolamine) is initiated only if symptoms do not improve in two hours.³⁰ The use of phentolamine began only in 1957 and currently it is the most commonly used drug, with great success in cases of major vasoconstrictions.²¹ It is an alpha-blocker introduced to combat effects caused by catecholamines; it should be administered in the same place where epinephrine was injected and may be used up to 13 h after the incident; digital vasoconstriction is consistently reversed in about 85–90 min.^{14,15,21} It is good to know, however, that phentolamine used at doses ranging from 1.0 to 3.5 mg may trigger side effects, such as cardiac arrhythmia and severe hypotension.

Because it is an undisputed fact that the use of epinephrine has danger, besides the main precautions mentioned above, several additional precautions are carefully and proactively recommended by the supporters of digital blocks with local anesthetics associated with the vasoconstrictor^{13–19,24}: (1) select well the patients who will receive epinephrine; (2) avoid it in young children, people with pheochromocytoma, heart or peripheral vascular disease, in poor clinical condition or in other situations previously mentioned; (3) 1% or 2% lidocaine should be preferred because, as a smooth muscle relaxant and vasoconstrictor, it is supposed to decrease temporarily the vasoconstrictor action of epinephrine and, thus, presumably protect the digital blood flow; (4) use solutions with epinephrine 1:200,000, although 1:100,000 seems safe to be used, but never 1:80,000 or less diluted; (5) use small volumes of anesthetics, as much as possible; (6) if a commercial preparation of lidocaine and epinephrine at low pH (3.5) is used, it should be buffered with sodium bicarbonate (8.4%) at 1:10 ratio to prevent local acidosis; (7) keep patients under observation until the return of normal color to the finger, especially in cases of prolonged ischemia, which may require reversal with nitroglycerin ointment, in minor cases, or with injections of 2.5 mg phentolamine—have it at hand—diluted with saline (4.5 to 9.0 mL); (8) do not use epinephrine without perfect knowledge of how to reverse its possible vasoconstriction, which would be similar to using morphine without understanding the mechanism of action of naloxone; and (9) disclose in detail when facing any digital block complication.

With the observance of all care described above, the combination of lidocaine-epinephrine would have some advantages^{13–19,23,24,29}: (1) shorter latency of anesthesia, which is discussed; (2) use of lower doses of local anesthetics, thus reducing its systemic toxicity; (3) temporary reduction of local blood flow and, thus, of bleeding in the surgical area; (4) prolongation of anesthesia and analgesia postoperatively; and (5) great possibility of waiving the tourniquet, which lowers the race against the clock and the risks from digital tourniquet.

Final considerations

Regarding the various techniques for digital blocks, considering the advantages, disadvantages, indications, and

contraindications of each method, we concluded that the use of each technique will depend on the clinical case, duration of the scheduled surgery, the choice of local anesthetic or the use or not of a tourniquet, and the preference and personal experience of each doctor.

Regarding epinephrine, there are many studies, but only few randomized ones, in order that its routine clinical use may be approved for digital anesthetic blocks. Some of the advantages mentioned above may be true, but do not seem to be as important to risk the use of epinephrine for these purposes, because to date there is little evidence that digital blocks with this vasoconstrictor added to the anesthetic solution are indispensable to significantly improve these procedures outcomes. In fact, many details exposed in the universal literature about epinephrine indication and application advantages and numerous care should be analyzed: (1) anesthetic solution with epinephrine should not be administered in pediatric patients; (2) the difference in the latency duration of anesthesia when epinephrine is used or not is of little importance; (3) the concept of using the lowest possible dose of local anesthetic is valid for solutions both with and without epinephrine; (4) the reduction of systemic local anesthetic toxicity is negligible because the doses commonly used are extremely low and offer virtually no risk of complications, except for the presence of epinephrine in the solutions; (5) administration of additional doses of local anesthetics without epinephrine is also rarely necessary; (6) bupivacaine and ropivacaine, the latter with small vasoconstriction, have longer effects than lidocaine and sufficient for almost all digital surgical procedures; (7) as commercial preparations of lidocaine with epinephrine are almost always used, more laborious precautions are often necessary to prevent local acidosis; (8) the duration of anesthesia with epinephrine, which is longer than without epinephrine, is only important in very long surgical procedures; (9) it is necessary to monitor the patient for a longer time when epinephrine is added to the anesthetic solution because its vasoconstriction may require the use of drugs, particularly phentolamine; and (10) the tourniquet undoubtedly provides a much drier surgical field, avoids waiting until epinephrine reaches its full vasoconstrictor action, it's always well tolerated as long as the skin in the area of its application is anesthetized, and helps to keep the finger insensitive, although it can truly cause complications when misapplied.

Thus, considering all of the above, while there is absolutely no concrete and definitive evidence of the absence of danger with the addition of epinephrine to the anesthetic solution and significant advantages of this approach to digital blocks, its use does not seem prudent or decisively fruitful in such anesthetic procedures.

Conflicts of interest

The authors declare no conflicts of interest.

References

- Bridenbaugh LD. The upper extremity: somatic blockade. In: Cousins MJ, Bridenbaugh PO, editors. *Neural blockade in clinical anesthesia and management of pain*. 2nd ed. Philadelphia: J.B. Lippincott Co; 1988. p. 412–5.
- Fisher L, Gordon M. Anesthesia for hand surgery. In: Wolfe SW, Hotchkiss RN, Pederson WC, Kozin SH, editors. *Green's operative hand surgery*, vol. 2, 6th ed. Philadelphia: Elsevier/Churchill Livingstone; 2011. p. 32–4.
- Scarff CE, Scarff CW. Digital nerve blocks: more gain with less pain. *Australas J Dermatol*. 2007;48:60–1.
- Reis A Jr. *Dessangramento e garroteamento de membros com finalidade cirúrgica*. 1st ed. Rio de Janeiro: Editora Atheneu; 1998. p. 11–4, 53–7.
- Chiu DTW. Transthecal digital block: flexor tendon sheath used for anesthetic infusion. *J Hand Surg*. 1990;15:471–3.
- Hill RG Jr, Patterson JW, Parker JC, et al. Comparison of transthecal digital block and traditional digital block for anesthesia of the finger. *Ann Emerg Med*. 1995;25:604–7.
- Williams JG, Lalonde DH. Randomized comparison of the single-injection volar subcutaneous block and the two-injection dorsal block for digital anesthesia. *Plast Reconstr Surg*. 2000;118:1195–200.
- Cummings AJ, Tisol W, Meyer LE. Modified transthecal digital block versus traditional digital block for anesthesia of the finger. *J Hand Surg*. 2004;29:44–8.
- Sonohata A, Asami K, Ogawa S, et al. Single injection digital block: is a transthecal injection necessary? *J Hand Surg*. 2009;34:94–8.
- Sonohata M, Nagamine S, Maeda K, et al. Subcutaneous single injection digital block with epinephrine. *Anesthesiology Research Practice*. 2012;4, <http://dx.doi.org/10.1155/2012/487650>. AN 487650.
- Reis A Jr. *Anestesia regional intravenosa*. 1st ed. Rio de Janeiro: Editora Atheneu; 1996. p. 203–7.
- Reis JA. Carta ao editor: Anestesia regional intravenosa digital. *Rev Bras Anesthesiol*. 1990;40:77.
- Wilhelmi BJ, Blackwell SJ, Miller JH, et al. Do not use epinephrine in digital blocks: myth or truth? *Plast Reconstr Surg*. 2001;107:393–7.
- Krunic AL, Wang LC, Soltani K, et al. Digital anesthesia with epinephrine: an old myth revisited. *J Am Acad Dermatol*. 2004;51:755–9.
- Lalonde DH, Bell M, Benoit P, et al. A multicenter prospective study of 3,110 consecutive cases of elective epinephrine use in the fingers and hand: the Dalhousie project clinical phase. *J Hand Surg (Am)*. 2005;30:1061–7.
- Chowdhry S, Seidenstricker L, Cooney DS, et al. Do not use epinephrine in digital blocks: myth or truth. A retrospective review of 1,111 cases. *Plast Reconstr Surg*. 2010;126:2031–4.
- Mann T, Hammert WC. Epinephrine and hand surgery. *J Hand Surg*. 2012;37:1254–6.
- Denkler K. A comprehensive review of epinephrine in the finger: to do or not to do. *Plast Reconstr Surg*. 2001;108:114–24.
- Sylaidis P, Logan A. Digital blocks with adrenaline. An old dogma refuted. *J Hand Surg*. 1998;23:17–9.
- Denkler KA. Epinephrine in the digits. *Plast Reconstr Surg*. 2011;128:598.
- Fizcharles-Bowe C, Denkler KA, Lalonde DH. *Hand*. 2007;2:5–11.
- Thomson CJ, Lalonde DH, Denkler KA, et al. A critical look at the evidence for and against elective epinephrine use in the finger. *Plast Reconstr Surg*. 2007;119:260–6.
- Wilhelmi BJ, Blackwell SJ, Miller JH, et al. Epinephrine in digital blocks: revisited. *Ann Plast Surg*. 1998;41:410–4.
- Andrades PR, Olguin FA. Digital blocks with or without epinephrine. *Plast Reconstr Surg*. 2003;111:1769–70.
- Nodwell T, Lalonde DH. How long does it take phentolamine to reserve adrenaline-induced vasoconstriction in the finger and hand? A prospective randomized blinded study: the Dalhousie project experimental phase. *Can J Plast Surg*. 2003;11:187–90.

26. Denkler K. Dupuytren's faciectomies in 60 consecutive digits using lidocaine with epinephrine and no tourniquete. *Plast Reconstr Surg.* 2005;115:802–10.
27. Waterbrook AL, German CA, Southall JC. Is epinephrine harmful when used with anesthetics for digital nerve blockers? *Ann Emerg Med.* 2007;50:472–5.
28. Sónmez A, Yaman M, Esroy B, et al. Digital blocks with and without adrenaline: a randomized-controlled study of capillary blood parameters. *J Hand Surg.* 2008;33:515–8.
29. Lalonde DH, Lalond JF. Discussion: do not use epinephrine in digital blocks: myth or truth? Par II. A retrospective review of 1111 cases. *Plast Reconstr Surg.* 2010;126:2035–6.
30. Muck AE, Bebartá VS, Borys DJ, et al. Six years of epinephrine digital injections: absence of significant local or systemic effects. *Ann Emerg Med.* 2010;56:270–5.
31. Altinyazar HC, Ozdemir H, Koca R, et al. Epinephrine in digital block: color Doppler flow imaging. *Dermatol Surg.* 2004;30:508–11.
32. McGovern SJ. Treatment of accidental injection of adrenaline from an auto-injector-device. *J Accid Emerg Med.* 1997;14:379–80.
33. Lee G, Thomas PC. Accidental digital injection of adrenaline from an autoinjector device. *J Accid Emerg Med.* 1998;15:287.
34. Barkhordarian AR, Wakelin SH, Paes TRF. Accidental digital injection of adrenaline from an autoinjector device. *Br J Dermatol.* 2000;43:359.
35. Kairalla E. Epinephrine-induced digital ischemia relieved by phentolamine. *Plast Reconstr Surg.* 2001;108:1831–2.
36. Velissariou I, Cotrell S, Berry K, et al. Management of adrenaline (epinephrine) induced digital ischemia in children after accidental injection from an EpiPen. *Emerg Med J.* 2004;21:387–8.
37. Schintler MV, Arbab E, Aberer W, et al. Accidental perforating bone injury using the EpiPen autoinjection device. *Allergy.* 2005;60:259–60.
38. Sicherer SH, Simons FE. Self-injectable epinephrine for first-aid management of anaphylaxis. *Pediatrics.* 2007;119:638–46.
39. Mathez C, Favrat B, Staeger P. Management options for accidental injection of epinephrine from an autoinjector: a case report. *J Med Case Reports.* 2009;3:7268.
40. Greenberg MI, Riviello RJ. Local effects after inadvertent digital injection with an epinephrine auto-injector. *Clin Toxicol (Phila).* 2010;48:1179–80.