



REVISTA BRASILEIRA DE ANESTESIOLOGIA

Official Publication of the Brazilian Society of Anesthesiology
www.sba.com.br



CLINICAL INFORMATION

Neurogenic pulmonary edema due to ventriculo-atrial shunt dysfunction: a case report

Ana Sofia Cruz^{a,*}, Sónia Menezes^b, Maria Silva^a

^a Anesthesiology Department, Centro Hospital São João, Porto, Portugal

^b Anesthesiology Department, Hospital Distrital de Santarém, Santarém, Portugal

Received 2 September 2013; accepted 31 October 2013

Available online 12 December 2013

KEYWORDS

Neurogenic
pulmonary edema;
Hydrocephalus;
Neuroanesthesia

Abstract

Background and objectives: Pulmonary edema is caused by the accumulation of fluid within the air spaces and the interstitium of the lung. Neurogenic pulmonary edema is a clinical syndrome characterized by the acute onset of pulmonary edema following a significant central nervous system insult. It may be a less-recognized consequence of raised intracranial pressure due to obstructive hydrocephalus by blocked ventricular shunts. It usually appears within minutes to hours after the injury and has a high mortality rate if not recognized and treated appropriately. **Case report:** We report a patient with acute obstructive hydrocephalus due to ventriculo-atrial shunt dysfunction, proposed to urgent surgery for placement of external ventricular drainage, who presented with neurogenic pulmonary edema preoperatively. She was anesthetized and supportive treatment was instituted. At the end of the procedure the patient showed no clinical signs of respiratory distress, as prompt reduction in intracranial pressure facilitated the regression of the pulmonary edema.

Conclusions: This report addresses the importance of recognition of neurogenic pulmonary edema as a possible perioperative complication resulting from an increase in intracranial pressure. If not recognized and treated appropriately, neurogenic pulmonary edema can lead to acute cardiopulmonary failure with global hypoperfusion and hypoxia. Therefore, awareness of and knowledge about the occurrence, clinical presentation and treatment are essential.

© 2013 Sociedade Brasileira de Anestesiologia. Published by Elsevier Editora Ltda. All rights reserved.

PALAVRAS-CHAVE

Edema pulmonar
neurogênico;
Hidrocefalia;
Neuroanestesia

Edema pulmonar neurogênico devido à disfunção da derivação ventrículo-atrial: relato de caso

Resumo

Justificativa e objetivos: O edema pulmonar é causado pelo acúmulo de líquido nos alvéolos e no interstício pulmonar. Edema pulmonar neurogênico é uma síndrome clínica caracterizada

* Corresponding author.

E-mail: fyzzita@gmail.com (A.S. Cruz).

por edema pulmonar de início agudo após um acometimento súbito do sistema nervoso central. Pode ser uma consequência menos reconhecida de pressão intracraniana aumentada por causa da hidrocefalia obstrutiva por derivações ventriculares bloqueadas. Geralmente aparece em minutos ou horas após o insulto e tem uma alta taxa de mortalidade, caso não seja identificado e tratado adequadamente.

Relato de caso: Relatamos o caso de paciente com hidrocefalia obstrutiva aguda por causa da disfunção da derivação ventrículo-atrial, programado para cirurgia em caráter de urgência para a colocação de derivação ventricular externa, que apresentou edema pulmonar neurogênico no pré-operatório. A paciente foi anestesiada e o tratamento de manutenção instituído. No fim do procedimento, a paciente não apresentou quaisquer sinais de distúrbio respiratório, pois a redução rápida da pressão intracraniana facilitou a regressão do edema pulmonar.

Conclusões: Este relato aborda a importância da identificação de um edema pulmonar neurogênico como uma possível complicação no período perioperatório resultante de um aumento da pressão intracraniana. Quando não identificado e tratado adequadamente, o edema pulmonar neurogênico pode levar à insuficiência cardiorrespiratória aguda, com hipoperfusão global e hipóxia. Portanto, a conscientização e o conhecimento de sua ocorrência, apresentação clínica e seu tratamento são essenciais.

© 2013 Sociedade Brasileira de Anestesiologia. Publicado por Elsevier Editora Ltda. Todos os direitos reservados.

Introduction

Pulmonary edema is caused by the accumulation of fluid within the air spaces and the interstitium of the lung. It may form due to intrinsic lung pathology or systemic dysfunction,¹ leading to impaired gas exchange and respiratory failure.

Neurogenic pulmonary edema (NPE) is a clinical syndrome characterized by the acute onset of pulmonary edema following a significant central nervous system (CNS) insult.² It usually appears within minutes to hours after the injury and has a high mortality rate if not recognized and treated appropriately.³ A high index of suspicion is required for its diagnosis, which is based on the occurrence of the edema after a neurologic insult and the exclusion of other possible causes.⁴

The most common causes of NPE are subarachnoid hemorrhages, followed by head trauma, seizures, embolic stroke, neurologic endovascular procedures and increased intracranial pressure (ICP) of any etiology.^{1,5} NPE may be a less-recognized consequence of raised ICP due to obstructive hydrocephalus by blocked ventricular shunts.⁶ In this setting, a mechanical shunt malfunction should be treated urgently to prevent the neurologic sequels of ICP,⁷ but the presence of preoperative NPE presents a dilemma to the neuroanesthetist due to the divergent goals of management of a raised intracranial pressure and pulmonary edema.⁶

We report a patient with acute obstructive hydrocephalus due to ventriculo-atrial shunt dysfunction who presented with NPE.

Case report

A 15-year-old female patient, with history of obesity, asthma, epilepsy, myelomeningocele sequelae and ventriculo-atrial shunt, was proposed to urgent surgery for placement of external ventricular drainage (EVD) to treat obstructive hydrocephalus due to shunt obstruction.

On admission, in the emergency department, she presented with vomit, headache and somnolence (Glasgow Coma Scale (GCS) of 14) and her CT scan showed a triventricular hydrocephalus (Fig. 1).

She was admitted to the emergency operating room (EOR) prostrate, showing progressive signs of respiratory distress (while with oxygen support by facemask with a FiO₂ of 80%) and with bilateral thick scattered crackles on pulmonary auscultation. She had a heart rate of 100 beats per minute, arterial pressure of 140/85 mm Hg, respiratory rate of 25 ventilations per minute and SatO₂ of 96%. Her chest X-ray showed bilateral haziness suggesting pulmonary edema (Fig. 2). The arterial blood gas parameters (ABG) were the following: pH 7.44; pCO₂ 29 mm Hg; pO₂ 86 mm Hg; Oxygen Saturation 97%; Lactates: 2.68 mmol L⁻¹. All other clinical and biochemical investigations were normal.

During pre-oxygenation, and with the supine position, the presence of pink foamy secretions was noticed.

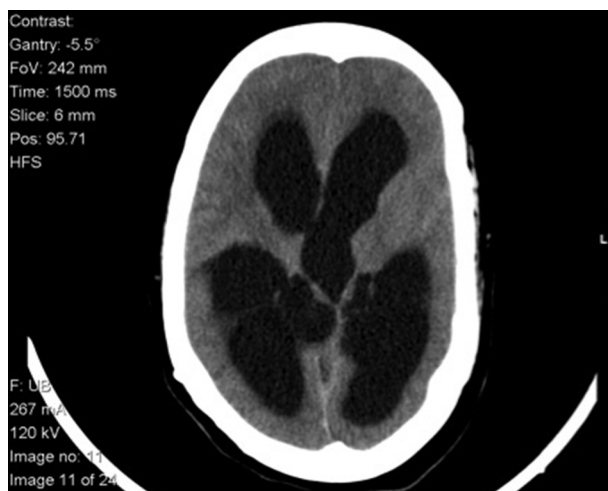

Figure 1 Admission CT scan showing triventricular hydrocephalus.

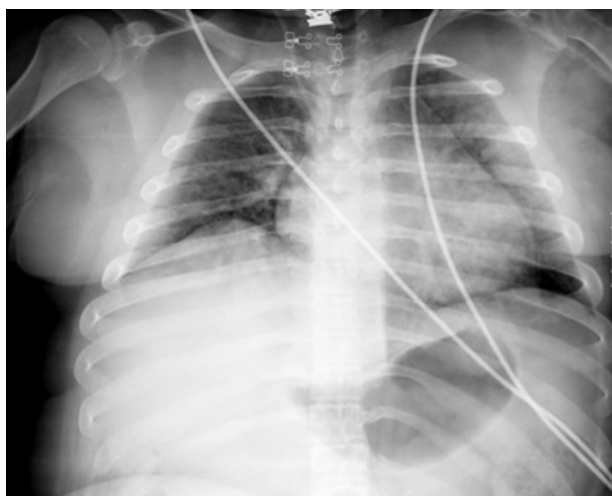


Figure 2 Admission X-ray showing bilateral haziness.

As there was no other cause for the respiratory dysfunction or previous respiratory illness, a diagnosis of NPE was considered. Furosemide was immediately administered and repeated later (in a total of 160 mg), and a rapid sequence induction of anesthesia was performed with propofol 2 mg/kg and succinylcholine 1 mg/kg. The patient was intubated and mechanically ventilated. An arterial line for invasive arterial pressure monitoring and blood sample collection was put in place. Salbutamol and Ipratropium bromide were administered through the tracheal tube. Anesthesia was maintained with a mixture of air and oxygen, adjusting the FiO_2 to maintain an arterial oxygen saturation $>90\%$, and 2.2% of sevoflurane along with rocuronium (0.6 mg/kg) and fentanyl (0.002 mg/kg). Low physiologic PEEP was applied. During surgery, and after the cerebral spinal fluid (CSF) drainage, it was possible to progressively reduce FiO_2 to 40%.

The patient remained hemodynamically stable during the entire procedure. In the end of the surgery, the ABG showed: pH 7.44; pCO_2 29 mm Hg; pO_2 86 mm Hg; Oxygen Saturation 97%; Lactates 2.6 mmol L^{-1} . At the end of the procedure the neuromuscular blockade was reversed, sevoflurane was suspended, and the patient was awake, responding to verbal command, breathing spontaneously and with no evidence of respiratory failure. The patient was deemed stable for extubation, and was transported to the Post Anesthesia Care Unit (PACU) on a 100% non-rebreather mask.

In the postoperative period the patient had two new NPE episodes due to EVD obstruction. The last one needed tracheal intubation to manage hypoxia. On the tenth day after admission she was successfully submitted to her ventricle shunt revision and extubated a few hours after surgery. She was discharged on the 14th day after admission, with SpO_2 100% in air, no clinical signs of respiratory distress and regression of the hydrocephalus, visible in the control CT scan.

Discussion

The exact cascade leading to the development of NPE remains unclear. There are thought to be two interacting processes: a centrally mediated excessive sympathetic

discharge, leading to loss of vasomotor homeostasis and intense pulmonary vasoconstriction; and an inflammatory mediator-related increase in vascular permeability.¹

The CNS discharge increases sympathetic nervous system tone and circulating catecholamine release. This results in a dramatic increase in pulmonary and systemic vascular resistance, cardiac contractility and tachycardia. The increased pulmonary vascular pressure alters the Starling's forces and shifts the balance toward extravasation of fluid into the lung interstitium.¹ There is concomitant mechanical stress injury to the pulmonary capillary basement membrane which occurs at pressures as low as 24 mm Hg.⁸ This exacerbates the flow of fluid out of the capillary as the endothelium is progressively damaged. Fluid is followed by plasma proteins, red blood cells and inflammatory cells.¹ The acute onset of cerebral hypertension and chemical irritation may be important underlying factors. Also, the velocity of increase in intracranial hypertension alone seems to be responsible for NPE.⁹ This fact may explain the appearance of NPE after hydrocephalus that was observed in this case.

The second proposed component in the development of NPE is increased vascular permeability mediated by inflammatory cytokines. The injury to the brain results in the expression and release of pro-inflammatory molecules within the brain. These move to the systemic circulation by disruption of the blood-brain barrier and initiate physiological changes in lung endothelial cells which drives the recruitment and extravasation of inflammatory cells and permits the translocation of fluid. The lung increases the expression and release of cytokines in response to the mechanical insult caused by increased pulmonary capillary pressure which is exacerbated by the barotrauma of mechanical ventilation.¹

NPE shows a broad clinical spectrum, ranging from the asymptomatic patient to the rapid development of respiratory failure. It typically presents within minutes to hours from a severe CNS insult. The clinical symptoms for NPE are nonspecific and often include dyspnea, tachypnea, tachycardia, cyanosis, pink frothy sputum, crackles and rales on clinical examination. The chest radiograph usually shows bilateral infiltrates, increased vascular shadowing and normal cardiac index.^{1,3,10}

In many cases, NPE is a retrospective diagnosis, largely based upon the occurrence of pulmonary edema in the appropriate setting and in the absence of another obvious cause.⁹

The main differential diagnoses include aspiration pneumonia, community acquired pneumonia, negative pressure edema, left ventricular failure and pulmonary contusions.¹

In our case the patient's physical examination and chest X-ray were consistent with diffuse pulmonary edema as the cause of hypoxemia. The absence of clinical or laboratory data suggestive of cardiac or pulmonary disease leaves left ventricular heart failure or intrinsic pulmonary disease as much less likely possibilities. The patency of the airway during all the procedure excludes the diagnosis of negative pressure pulmonary edema, and there were no history of trauma to support the hypothesis of pulmonary contusions. The rapid improvement with supportive respiratory care and normalization of intracranial pressure turns infectious pneumonia an unlikely situation.

Due to the concomitant development of an acute hydrocephalus and ICP, a direct and causal relation between these two conditions was hypothesized. The reappearance of the respiratory dysfunction with the further obstruction of the EDV further corroborated this causal relation, settling the diagnosis of NPE. Aspiration pneumonia differs from NPE by the presence of clinical clues (vomiting, gastric contents in the oropharynx, witnessed aspiration) and the distribution of alveolar disease in dependent portions of the lungs. In contrast, NPE is characterized by frothy, often blood-tinged sputum and more centrally distributed alveolar disease on chest X-ray.

The initial step in management of NPE is identification and definitive treatment of the precipitating cause. The strategy for treatment is the rapid control of the triggering central neurologic insult (and prompt reduction in intracranial pressure), while supporting organ function.^{1,3} The early surgical treatment of the primary injury is strongly recommended because it facilitates the regression of the pulmonary edema.¹¹

The main concerns in handling anesthesia in these situations are prevention of hypoxia and maintenance of cerebral perfusion pressure in a patient with concomitant ICP and impaired gas exchange at the alveolar-capillary membrane. The risks of decreased cerebral perfusion must be weighed against the benefits of decreased systolic blood pressure and pulmonary edema.⁵

The patient's neurological status should be the primary determinant of whether tracheal intubation is required. If intubation and mechanical ventilation is needed, it should be performed using a technique which will avoid increase of either ICP or systemic arterial pressure yet maintain cerebral perfusion.¹

Ventilation with supplemental oxygen should prevent hypoxemia and avoid iatrogenic lung injury. Initial tidal volumes should be 6–7 mL/kg utilizing PEEP to aid clearance of the edema and maintain alveolar recruitment.¹

Mechanical ventilation with PEEP should be used with caution because it reduces cardiac output and impairs venous return, increasing ICP.¹² PEEP values lower than 15 cm H₂O have been shown not to impede the cerebral perfusion pressure.¹³

Any patient with raised ICP should be ventilated according to neuroprotective parameters which may be in conflict with optimal ventilation for NPE. Permissive hypercapnia or ventilation in prone position should not be used in the presence of raised ICP unless ICP monitoring is in place.¹ A reduction in ICP may be successfully achieved by hyperventilation, osmotic and loop diuretics, raised headboard and anticonvulsant therapy.³

Patients should be assessed for volume status and fluid responsiveness, and intravenous fluids should be used judiciously.

Dobutamine, which may increase cardiac output, decrease pulmonary artery balloon pressure and promote diuresis, is a first line drug in NPE treatment. Additional agents that have been advocated in the treatment of

NPE include fosfodiesterase inhibitors, beta1-antagonists alone or in combination with a vasodilator, and alpha-antagonists.^{1,14}

The pure form of NPE may resolve within 48–72 h with adequate treatment.^{1,3,5} The patients prognosis generally depends on the neurologic condition.⁵ Overall mortality in NPE is estimated in 7–10% range.¹⁵

This report addresses the importance of recognition of NPE as a possible perioperative complication resulting from an increase in intracranial pressure. If not recognized and treated appropriately, NPE can lead to acute cardiopulmonary failure with global hypoperfusion and hypoxia.

Conflicts of interest

The authors declare no conflicts of interest.

References

- O'Leary R, McKinlay J. Neurogenic pulmonary oedema. *Contin Educ Anesth Crit Care*. 2011;V1:87–92.
- Davidson D, Terek M, Chawla L. Neurogenic pulmonary edema. *Crit Care*. 2012;16:212.
- Baumann A, Audibert G, McDonnell J, et al. Neurogenic pulmonary edema. *Acta Anaesthesiol Scand*. 2007;51:447–55.
- Tan C, Lai C. Neurogenic pulmonary edema. *Can Med Assoc J*. 2007;177:250.
- Venkatesan AM, Karpaliotis D, Silverman ES. Neurogenic pulmonary edema following catastrophic subarachnoid hemorrhage: a case report and pathophysiologic review. *J Intensive Care Med*. 2001;16:236–42.
- Lakkireddigari S, Durga P, Nayak M, et al. Preoperative neurogenic pulmonary edema: a dilemma for decision making. *J Anaesthesiol Clin Pharmacol*. 2012;28:232–4.
- Davidyuk G, Soriano S, Goumnerova L. Acute intraoperative neurogenic pulmonary edema during endoscopic ventriculoperitoneal shunt revision. *Int Anesth Res Soc*. 2010;110:594–5.
- West JB. Cellular responses to mechanical stress invited review: pulmonary capillary stress failure. *J Appl Physiol*. 2000;89:2483–9.
- Figueiredo E, Oliveira A, Almeida C, et al. Subarachnoid hemorrhage and hydrocephalus causing neurogenic pulmonary edema. *Arq Neuropsiquiatr*. 2010;68:461–2.
- Ahrens J, Capelle H, Przemeczek M. Neurogenic pulmonary edema in a fatal case of subarachnoid hemorrhage. *J Clin Anesth*. 2008;20:129–32.
- Yabumoto M, Kuriyama T, Iwamoto M. Neurogenic pulmonary edema associated with ruptured intracranial aneurism: case report. *Neurosurgery*. 1986;19:300–4.
- Brito J, Diniz M, Rosas R, et al. Edema pulmonar agudo neurogênico: relato de caso. *Arq Neuro-psiquiatr*. 1995;53:288–93.
- McGuire G, Crossley D, Richards J, et al. Effects of varying levels of positive end-expiratory pressure on intracranial pressure and cerebral perfusion pressure. *Crit Care Med*. 1997;25:1059–62.
- Dehan P. Haemodynamic changes in neurogenic pulmonary edema: effect of dobutamine. *Intensive Care Med*. 1996;22:672–7.
- Sedý J, Zicha J, Kunes J, et al. Mechanisms of neurogenic pulmonary edema development. *Physiol Res*. 2008;57:499–506.