



REVISTA BRASILEIRA DE ANESTESIOLOGIA

Official Publication of the Brazilian Society of Anesthesiology
www.sba.com.br



CLINICAL INFORMATION

Accidental catheterization of epidural venous plexus: tomographic analysis[☆]

Mariano Paiva Souza^{a,*}, Edno Magalhães^{b,c}, Elialba de Farias Cascudo^a,
Marco Antonio Dias Jogaib^a, Marcelo Carneiro da Silva^a

^a Hospital Regional do Gama (HRG), Brasília, DF, Brazil

^b Universidade de Brasília (UnB), Brasília, DF, Brazil

^c Scientific Department, Sociedade Brasileira de Anestesiologia, Brasília, DF, Brazil

Received 12 June 2012; accepted 20 March 2013

Available online 31 March 2014

KEYWORDS

Complications:
venous
catheterization;
Anesthesia: epidural
anesthesia;
Epidural catheter;
Tomography: venous
plexus;
Intervertebral vein;
Azygos vein

Abstract

Background and objectives: Inadvertent venous catheterizations occur in approximately 9% of lumbar epidural anesthetic procedures with catheter placement and, if not promptly recognized, can result in fatal consequences. The objective of this report is to describe a case of accidental catheterization of epidural venous plexus and its recording by computed tomography with contrast injection through the catheter.

Case report: A female patient in her sixties, physical status II (ASA), underwent conventional cholecystectomy under balanced general anesthesia and an epidural with catheter for postoperative analgesia. During surgery, there was clinical suspicion of accidental catheterization of epidural venous plexus because of blood backflow through the catheter, confirmed by the administration of a test dose through the catheter. After the surgery, a CT scan was obtained after contrast injection through the catheter. Contrast was observed all the way from the skin to the azygos vein, passing through anterior and posterior epidural venous plexuses and intervertebral vein.

Conclusion: It is possible to identify the actual placement of the epidural catheter, as well as to register an accidental catheterization of the epidural venous plexus, using computed tomography with contrast injection through the epidural catheter.

© 2014 Sociedade Brasileira de Anestesiologia. Published by Elsevier Editora Ltda. All rights reserved.

[☆] Study conducted at the Hospital Regional do Gama (HRG), Brasília, DF, Brazil.

* Corresponding author.

E-mails: dr-marianosouza@gmail.com, dr-marianosouza@hotmail.com (M.P. Souza).

PALAVRAS-CHAVE

Complicações:
 cateterização venosa;
 Anestesia: peridural;
 Cateter peridural;
 Tomografia: plexo
 venoso;
 Veia intervertebral;
 Veia ázigo

Cateterização acidental do plexo venoso peridural: análise tomográfica**Resumo**

Justificativa e objetivos: A cateterização venosa inadvertida ocorre em aproximadamente 9% das anestésias peridurais lombares com introdução de cateter e caso não seja prontamente reconhecida pode trazer consequências fatais. O objetivo deste relato é descrever um caso de cateterização acidental do plexo venoso peridural e o seu registro por tomografia computadorizada com injeção de contraste pelo cateter.

Relato de caso: Paciente feminina, sexagenária, estado físico II (ASA), submetida à colecistectomia convencional sob anestesia geral balanceada e peridural com cateter para analgesia pós-operatória. Durante cirurgia houve suspeição clínica de cateterização acidental do plexo venoso peridural, por refluxo de sangue pelo cateter, fato confirmado pela administração de dose-teste pelo cateter. Feita tomografia computadorizada com injeção de contraste pelo cateter, após o término da cirurgia. Observado todo o trajeto do contraste desde a pele até a veia ázigo, passando pelo plexo venoso peridural anterior, posterior e veia intervertebral.

Conclusão: É possível a identificação do real posicionamento do cateter peridural, bem como o registro da cateterização acidental do plexo venoso peridural, por meio de tomografia computadorizada com injeção de contraste pelo cateter peridural.

© 2014 Sociedade Brasileira de Anestesiologia. Publicado por Elsevier Editora Ltda. Todos os direitos reservados.

Introduction

Inadvertent venous catheterization occurs in approximately 9% of lumbar epidural anesthetic procedures with catheter placement¹ and if not promptly recognized, can result in fatal consequences, such as convulsions, cardiotoxicity and cardiovascular collapse.^{1,2}

The objective of this report is to describe a case of accidental catheterization of the posterior epidural venous plexus and its documentation by computed tomography with injection of iodinated non-ionic contrast through the epidural catheter.

Case report

A female patient, 63 years old, physical status II (ASA); underwent conventional cholecystectomy under balanced general anesthesia and an epidural. Initially conscious sedation was applied, with the patient properly monitored with pulse oximetry, continuous ECG and noninvasive blood pressure. In the left lateral decubitus position, puncture of the epidural space between T11 and T12 was taken, with a positive loss of resistance test and negative aspiration for CSF or blood, using a 16G Tuohy needle with its bevel in a cephalad orientation. After the puncture, 3 mL of 2% lidocaine with epinephrine was administered (test dose). No change in heart rate or electrocardiographic tracing was observed, so 20 mL of 0.5% ropivacaine was applied, and a multi-fenestrated 16G epidural catheter was introduced for the purpose of postoperative analgesia. After this procedure, suction was done, when reflux of fluid with a small amount of blood was observed. After securing the catheter to the skin and with the patient in the horizontal dorsal decubitus position, balanced general anesthesia with propofol, fentanyl and sevoflurane was performed. The

surgical procedure was uneventful. At the end of the surgery a new aspiration through the catheter was performed, when blood reflux was again observed. Then, 3 mL of lidocaine with adrenaline was administered through the catheter and subsequently a 40% increase in heart rate was noted. After the surgery, the patient, already extubated and in spontaneous breathing, lucid and oriented was taken to the radiology department. A helical computed tomography scan was performed with injection of 4 mL of iodinated non-ionic contrast through the epidural catheter. The image analysis revealed the catheter path from the skin to the epidural space (Fig. 1). This procedure allowed the observation of the posterior and anterior internal epidural venous plexuses (Fig. 2). The intervertebral vein was also identified from its origin in the intervertebral foramen to its confluence with the azygos vein (Fig. 3). In images in the axial, sagittal and coronal planes, it is possible to identify the azygos vein throughout its abdominal and thoracic portion (Figs. 4–6).

The catheter was removed uneventfully. The patient had a good clinical course and was discharged on the second postoperative day, with no complaints.

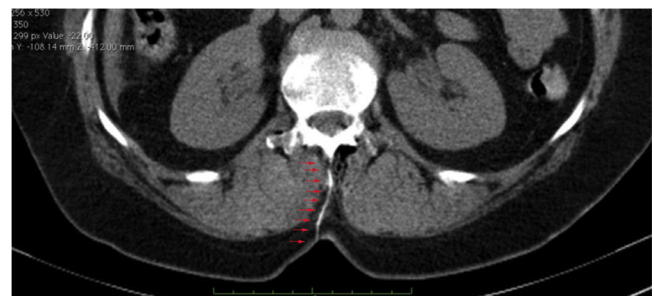

Figure 1 Catheter contrasted from the skin to the epidural space, marked by red arrows.

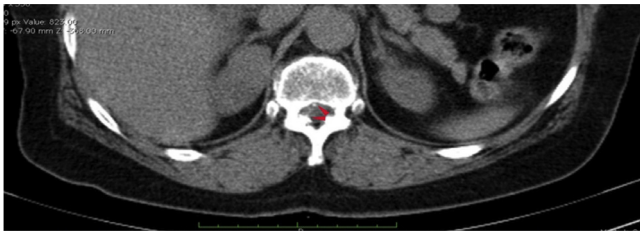

Figure 2 Anterior and posterior epidural venous plexus with contrast.

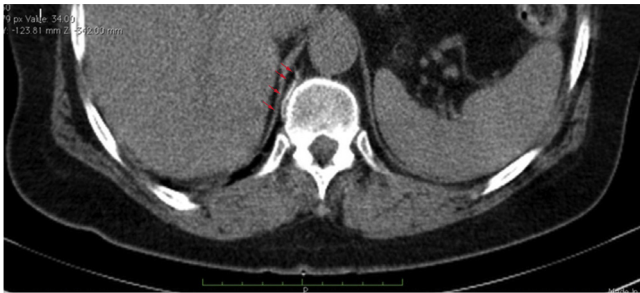

Figure 3 Intervertebral vein.

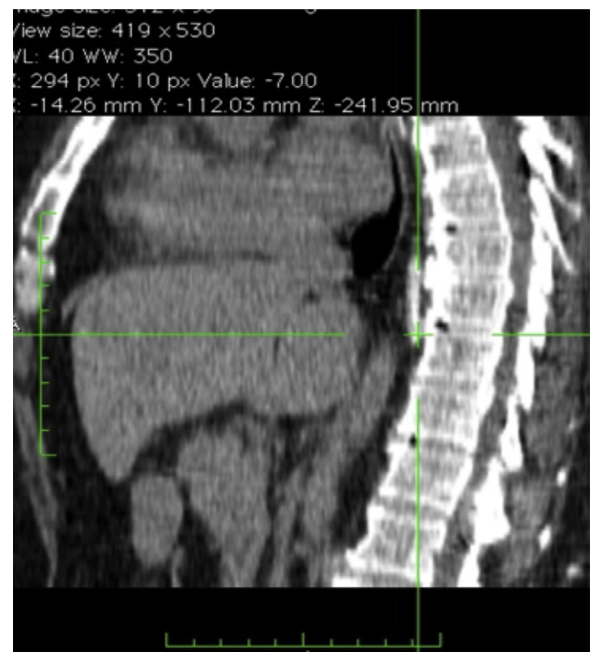


Figure 5 Azygos vein in the sagittal plane.

Discussion

The catheterization of the internal epidural venous plexus is a possible complication, even when the operator follows the proper technique. Several studies have tried to correlate strategies associated with a lower incidence of inadvertent catheterization of the epidural venous plexus.³ Myhre et al., in a meta-analysis involving 30 clinical trials and more than 12,000 patients, concluded that the risk of venous plexus catheterization can be reduced, if the following strategies are applied: positioning the patient in lateral decubitus,

fluid pre-distension, use of single-hole catheters and limiting the depth of catheter insertion to 6 cm or less.¹

Given the relative frequency of accidental epidural venous plexus catheterizations and the dire consequences that an accidental intravascular injection of local anesthetic can cause, it is imperative for the immediate recognition of this complication by the anesthesiologist. The administration of a test dose through the catheter must be a routine maneuver, even when the test dose by needle was negative. While it is possible to document the actual placement of the epidural catheter, as well as the occurrence of an

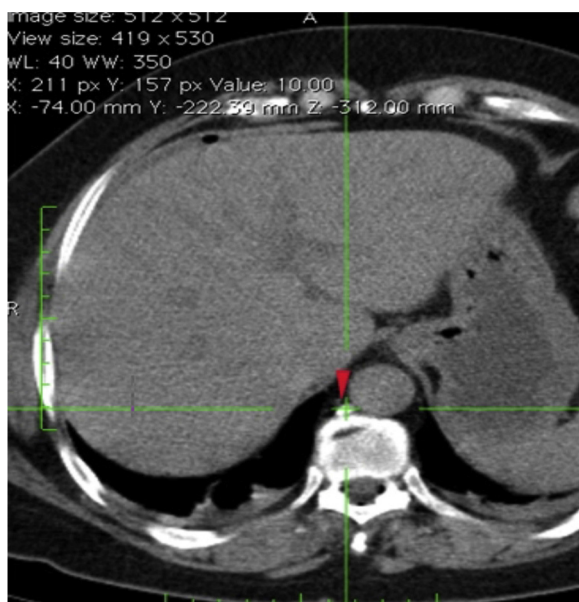


Figure 4 Azygos vein in the axial plane.

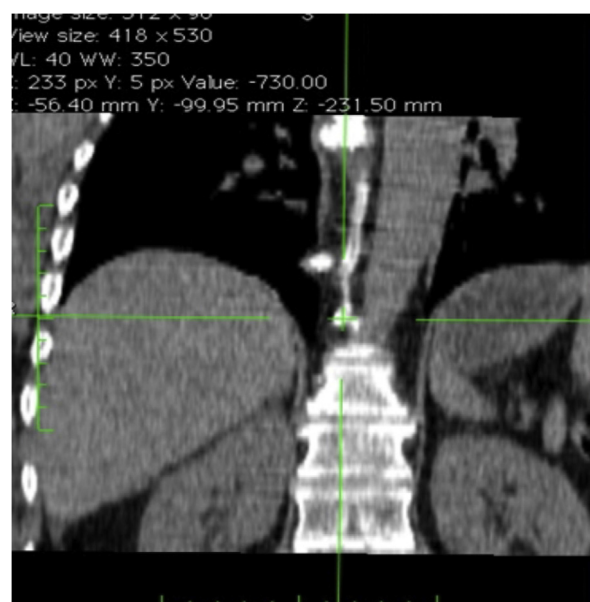

Figure 6 Azygos vein in the coronal plane.

accidental venous catheterization using computed tomography with contrast injection through the catheter, its occurrence must be clinically recognized, since the imaging test is not accessible to the anesthesiologist in his/her daily practice, because of its high cost or the difficulty of conducting this patient to the radiology department pre- or perioperatively.

Conflicts of interest

The authors declare no conflicts of interest.

References

1. Mhyre JM, Greenfield MLVH, Tsen LC, Polly L. A systematic review of randomized controlled trials that evaluate strategies to avoid epidural vein cannulation during obstetric epidural catheter placement. *Obstetr Anesthesiol.* 2009;108:1232–42.
2. Rodgers A, Walker N, Schug S, et al. Reduction of postoperative mortality and morbidity with epidural or spinal anaesthesia: results from overview of randomized trials. *BMJ.* 2000;321:1493.
3. Hogan Q. Epidural catheter tip position and distribution of injectate evaluated by computed tomography. *Anesthesiology.* 1999;90:964–70.