



REVISTA BRASILEIRA DE ANESTESIOLOGIA

Official Publication of the Brazilian Society of Anesthesiology
www.sba.com.br



CLINICAL INFORMATION

Continuous Bilateral TAP block in Patient with Prior Abdominal Surgery

Isabel Flor de Lima^{*,a}, Filipe Linda^a, Ângela dos Santos^a, Neusa Lages^b, Carlos Correia^b

^a Hospital Garcia de Orta, Entidade Pública Empresarial, Almada, Portugal

^b Centro Hospitalar do Alto Ave, Entidade Publica Empresarial, Fafe, Portugal

Study conducted at Serviço de Anestesiologia do Centro Hospitalar do Alto Ave, Entidade Publica Empresarial, Fafe, Portugal.

Submitted on October 26, 2012; accepted on December 3, 2012

KEYWORDS

Abdominal Muscles;
Analgesia;
Intraoperative Period/
complications;
Nerve Block;
Postoperative Period

Abstract

We present as an option for epidural analgesia and intravenous opioid infusion a clinical case of transversus abdominis plane (TAP) block, with bilateral placement of catheter for postoperative analgesia after exploratory laparotomy performed in a patient with previous abdominal surgery and heart, kidney and liver failure.

© 2013 Sociedade Brasileira de Anestesiologia. Published by Elsevier Editora Ltda. All rights reserved.

Introduction

Transversus abdominis plane (TAP) block has shown to be a promising and effective technique for intra- and postoperative analgesia of abdominal, urological, gynecological, and obstetric surgeries.

Since its first description in 2001 by Rafi and corroboration by McDonnell in 2004,¹ multiple studies have emerged aiming at increasing the clinical applicability of the TAP block approach.²

We present a case report in which a continuous bilateral TAP block was performed for postoperative analgesia of major abdominal surgery.

Clinical case

A male patient, aged 71 years, white, body mass index (BMI) of 20.76, was admitted with a clinical condition of intestinal obstruction and sepsis. The relevant features of patient's history were congestive heart failure (CHF) of ischemic and hypertensive etiology, implanted pacemaker, stage III chronic kidney failure (CKF), liver transplant 21 years ago due to cirrhosis secondary to HBV infection, and hospitalization three months ago due to hepatic encephalopathy. Laboratory tests showed anemia (Hb-10.6 g.dL⁻¹), thrombocytopenia (69,000 platelets.µL⁻¹), and creatinine (2.13 mg.dL⁻¹).

*Corresponding author. Serviço de Anestesiologia do Centro Hospitalar do Alto Ave, Entidade Publica Empresarial, Fafe, Portugal.
E-mail: i.flordelima@gmail.com (I.F. Lima)

We performed exploratory laparotomy with xiphopubic incision for Hartman’s procedure. We performed standard monitoring and balanced general anesthesia with propofol (200 mg), fentanyl (0.15 mg), and rocuronium (50 mg), and maintained with desflurane and nitrous oxide, uneventful.

Regarding analgesia, we administered intravenous (IV) paracetamol (1 g) and tramadol (100 mg). At the end of surgery, we performed bilateral, anterior, subcostal TAP block, ultrasound-guided, in an anatomical line conditioned by the previous and current surgery (Figs. 1, 2, and 3), with an 18-G Tuohy needle and introduced two 20-G epidural catheters (B. Braun Perifix), through which we bilaterally applied an initial bolus of 20 mL ropivacaine 0.5%. At the post-anesthesia care unit (PACU), we connected two elastomers with 5 mL.h⁻¹ ropivacaine 0.2% to catheters (Fig. 4). We combined this analgesia with paracetamol (1g every 6 hours), parecoxib (20 mg/IV every 12 hours), and rescue IV morphine (2 mg bolus, if numerical pain scale equal to or greater than four).

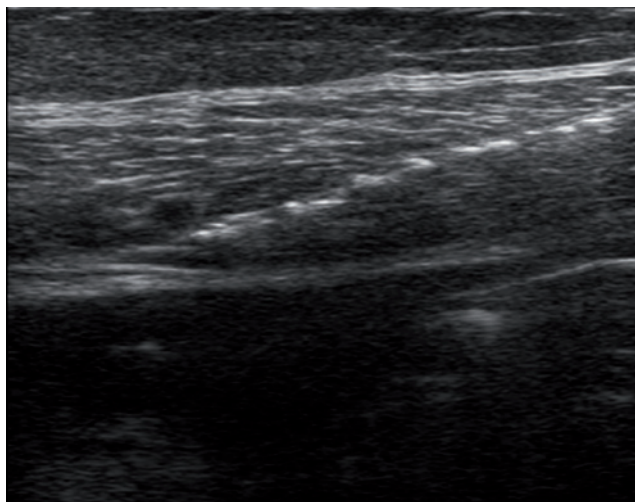


Figure 3 Needle entry into TAP and local anesthetic diffusion.

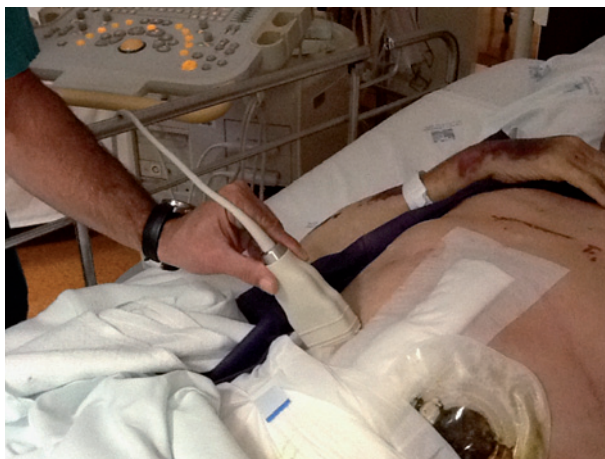

Figure 1 Tube position during TAP approach.

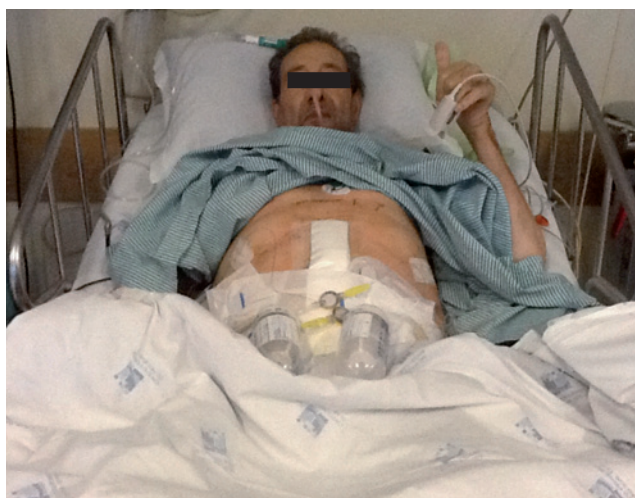

Figure 4 Patient monitoring at 48 hours.

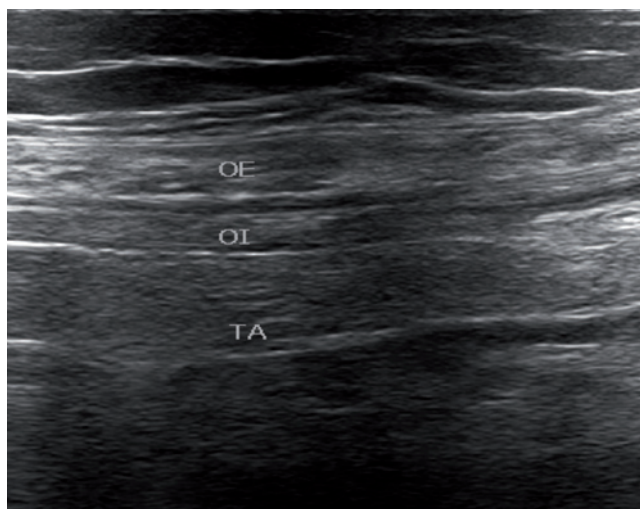


Figure 2 Ultrasound of the puncture region.

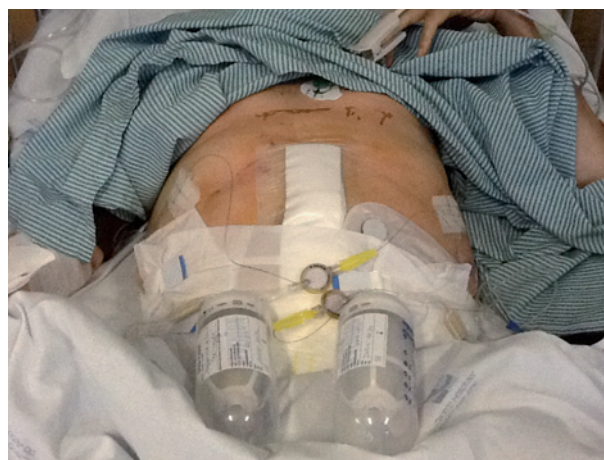

Figure 5 Elastomers bilaterally connected to TAP catheters.

At the 24th and 48th hour (Fig. 5), the patient's score for pain at rest and in motion was zero; he was hemodynamically stable and did not need rescue doses of morphine. After 48 hours we removed the catheters, the patient was discharged from PACU and transferred to the ward, having never reported pain.

Discussion

Pain control is an important and essential part of postoperative care and a decisive factor in recovering from any surgery. In our case, pain control assumed an even greater importance, given the patient's heart condition. We know that postoperative pain, particularly if poorly controlled, may cause sympathetic nervous system (SNS) activation, which is responsible for coronary vasoconstriction, tachycardia, and increased oxygen consumption, which may lead to ischemia or infarction.^{3,4}

Literature describes two standard analgesic options for patients undergoing major abdominal surgery: IV opioids and epidural analgesia. Although IV opioids provide good analgesia at rest (static analgesia), they are not as effective in controlling pain in motion (dynamic analgesia).^{5,6} Moreover, they are associated with side effects (nausea, vomiting, sedation, paralytic ileus, respiratory depression), with particular importance for liver and kidney diseases, as in the case described here. Both liver and kidney failure produce change in the pharmacokinetics of opioids, particularly morphine, and may precipitate the onset of these adverse effects by the accumulation of active metabolites.^{7,8} However, epidural analgesia has been considered the gold standard in controlling pain after surgery involving abdominal wall incisions², despite the contraindications, potential risks, and failure rate described (17% to 37%).⁹ Our patient had contraindications: sepsis (relative) and thrombocytopenia (absolute) worsened by the likelihood of multipuncture. There is no study in literature ensuring the safety of neuraxial block to platelet counts below 80,000. μL^{-1} .^{10,11} Therefore, we did not perform epidural analgesia in our patient.

To date, no TAP block has proved superior to intrathecal morphine or epidural analgesia, but it is considered a valid option if neuraxial block is contraindicated.² Considering the abovementioned, we opted for bilateral continuous TAP block to extend the analgesic benefit postoperatively.

There are three TAP approaches reported for analgesia: the posterior approach, via anatomical references in the triangle of Petit, described by Rafi and McDonnell, for the lower abdominal quadrants (T11-L1 dermatomes);¹ the ultrasound-guided subcostal approach, described by Hebbard in 2008, for periumbilical and upper abdominal quadrants (T10-T6 dermatomes);¹² and subcostal approach, with needle insertion obliquely from the xiphoid process to iliac crest, also described by Hebbard in 2010, for the entire abdominal wall (T6-L1 dermatomes) - a modification that overcomes the limitations of previous approaches.¹³ Other authors consider the combined posterior and subcostal approach, with single injection ideal for optimal analgesia throughout the abdominal wall.¹

Although TAP provides superior analgesia compared to placebo, the visceral pain of the retroperitoneum and posterolateral abdominal wall from the anterior axillary line remains, which requires the addition of IV opioids in the blockade.^{2,9,13,14}

Continuous TAP block provides static and dynamic analgesia with minimal effects on cardiovascular system.⁹ It may contribute to early ambulation and rapid recovery from any major abdominal surgery, particularly if associated with intravenous analgesia.⁹

In our case, the previous abdominal surgery and edema resulting from the current laparotomy hindered the visualization of abdominal wall muscles. This led us to perform an anterior subcostal block where muscle plane anatomy was noticeable, instead of using approaches described in the literature.

The approach used, although it is not "conventional" and has not been reported to date, resulted in analgesia at T6-L1 dermatome level, without the use of rescue analgesia. This particular patient's history of liver transplantation with a bilateral subcostal incision may have influenced the abdominal wall's decreased sensitivity. Furthermore, we do not know the real diffusion of local anesthetics (LA). Contrasting studies have shown that the posterior TAP block allow the LA diffusion into the paravertebral space and, therefore, the analgesic effect may be greater than expected regarding dermatomes, visceral analgesia, and duration.² In the case reported here, the possible presence of adhesions between abdominal wall muscle planes may have forced LA dispersal to inferior and posterior planes. It is also important to assess the ideal concentration and volume for bolus and infusion and proper placement of the catheter within TAP.^{1,13}

Although there are doubts regarding TAP block, the technique is easily applied and has an excellent safety profile with any approach,^{2,5} which may encourage its practice. There are only two case reports of liver puncture.² Although toxic plasma concentrations of LA have been detected, there are no reports of clinical signs of systemic toxicity associated with LA.²

Absolute contraindications for TAP block include patient refusal, abdominal wall infection, and abnormality at the puncture site. To date, there is no evidence that coagulation disorders are contraindications for the use of this technique.¹

TAP block is an important component of a multimodal analgesia. Its clinical indication as part of a combined anesthetic/analgesic technique is increasingly accepted.

TAP block has weak points when used alone and in single administration. However, if the technique is associated with continuous intravenous analgesics it is connected to lower pain scores, reduced opioid consumption with reduced nausea and vomiting after surgery, early ambulation and hospital discharge. However, more studies are needed to increase this technique's accuracy.

In the case reported here, the patient's clinical condition and previous abdominal surgery led us to perform a TAP block using an approach not yet reported, which resulted in clinical success.

Conflicts of interest

The authors declare no conflicts of interest.

References

1. Young JM, Gorlin AW, Modest VE, Quraishi SA - Clinical implications of the Transversus Abdominis Plane block in adults. *Anesthesiol Res Pract*. 2012;ID731645.
2. McDonnell G, Finnerty O - Transversus Abdominis Plane block. *Curr Opin Anesthesiol*. 2012;25:610-614.
3. Liu S, Carpenter RL, Neal JM - Epidural anesthesia and analgesia. Their role in postoperative outcome. *Anesthesiology*. 1995;82:1474.
4. Wu CL, Fleisher LA - Outcomes research in regional anesthesia and analgesia. *Anesth Analg*. 2000;91:123.
5. Niraj G, Kelkar A, Fox AJ - Case report - Oblique subcostal TAP catheters: an alternative to epidural analgesia after upper abdominal surgery. *Anaesthesia*. 2009;64:1137-1140.
6. Mann C, Pouzeratte Y, Boccarda G et al. - Comparison of intravenous or epidural patient controlled analgesia in the elderly after major abdominal surgery. *Anesthesiology*. 2000;92:433-441.
7. Gholson CF, Provenza JM, Bacon BR - Hepatologic considerations in patients with parenchymal liver disease undergoing surgery. *Am J Gastroenterol*. 1990;85:487-496.
8. Davies G, Kingswood C, Street M - Pharmacokinetics of opioids in renal dysfunction. *Clin Pharmacokinet*. 1996;31:410-422.
9. Niraj G, Kelkar A, Jeyapalan I et al. - Comparison of analgesic efficacy of subcostal Transversus Abdominis Plane block with epidural analgesia following upper abdominal surgery. *Anaesthesia*. 2011;66:465-471.
10. Van Veen JJ, Nokes TJ, Makris M - The risk of spinal haematoma following neuraxial anaesthesia or lumbar puncture in thrombocytopenic individuals. *Br J Haematol*. 2010;148(1):15-25.
11. Englbrecht JS, Pogatzki-Zahn EM, Zahn P - Spinal and epidural anesthesia in patients with hemorrhagic diathesis: decisions on the brink of minimum evidence? *Anaesthesist*. 2011;60(12):1126-1134.
12. Hebbard P - Subcostal transversus abdominis plane block under ultrasound guidance. *Anesth Analg*. 2008;106:674-675.
13. Hebbard P, Barrington MJ, Vasey C - Ultrasound-guided continuous oblique subcostal transversus abdominis plane blockade. *Reg Anesth Pain Med*. 2010;35(5):436-441.
14. Bjerregaard N, Nirolajsen, Bendtsen TF, Rasmussen BS - Transversus abdominis plane catheter bolus analgesia after major surgery. *Anesthesiol Res Pract*. 2012;ID596536.