



## CLINICAL INFORMATION

# Inadvertent Venous Air Embolism during Cesarean Section: Collapsible Intravenous Fluid Bags Without Self-Sealing Outlet Have Risks. Case Report

Mefkur Bakan\* <sup>1</sup>, Ufuk Topuz <sup>1</sup>, Asim Esen <sup>1</sup>, Gokcen Basaranoglu <sup>1</sup>, Erdogan Ozturk <sup>1</sup>

1. MD; Bezmialem Vakif University, School of Medicine, Department of Anesthesiology and Reanimation  
Received from the Bezmialem Vakif University, Istanbul, Turkey.

Submitted on August 17, 2012. Approved on September 17, 2012.

### Keywords:

Cesarean Section;  
Embolism, Air;  
Fluid Therapy;  
Infusions, Intravenous.

### Abstract

The anesthesiologist must be aware of the causes, diagnosis and treatment of venous air embolism and adopt the practice patterns to prevent its occurrence. Although venous air embolism is a known complication of cesarean section, we describe an unusual inattention that causes iatrogenic near fatal venous air embolism during a cesarean section under spinal anesthesia. One of the reasons for using self-collapsible intravenous (IV) infusion bags instead of conventional glass or plastic bottles is to take precaution against air embolism. We also demonstrated the risk of air embolism for two kinds of plastic collapsible intravenous fluid bags: polyvinyl chloride (PVC) and polypropylene-based. Fluid bags without self-sealing outlets pose a risk for air embolism if the closed system is broken down, while the flexibility of the bag limits the amount of air entry. PVC-based bags, which have more flexibility, have significantly less risk of air entry when IV administration set is disconnected from the outlet. Using a pressure bag for rapid infusion can be dangerous without checking and emptying all air from the IV bag.

© 2013 Sociedade Brasileira de Anestesiologia. Published by Elsevier Editora Ltda. All rights reserved.

## Introduction

Venous air embolism (VAE) is a potentially life-threatening complication of surgical and invasive procedures. The anesthesiologist must be aware of its causes, diagnosis and treatment and adopt the practice patterns to prevent its occurrence. Although VAE is a known complication of cesarean section <sup>1</sup>, we describe an unusual inattention that causes iatrogenic near fatal VAE during a cesarean section under spinal anesthesia. The patient gave written permission for the authors to publish this report.

## Case Report

A 40-yr-old woman, (85 kg, 155 cm) at 38 weeks' gestation had uterine contractions and was scheduled for cesarean section. She was healthy (ASA physical status I) and had history of uneventful uterine (myomectomy) and thyroid (sub-total thyroidectomy) surgeries 1 and 3 years ago, respectively.

Upon arrival, her blood pressure was 120/80 mm Hg and her heart rate was 75 bpm. We inserted a 22G intravenous (IV) cannula at the dorsum of the hand (a large-bore cannula could not be inserted at the ward), and a bladder catheter,

\* Corresponding author: Bezmialem Vakif University, Vatan cad, Fatih, 34093, Istanbul, Turkey.

E-mail: mefkur@yahoo.com

ISSN/\$ - see front matter © 2013 Sociedade Brasileira de Anestesiologia. Published by Elsevier Editora Ltda. All rights reserved.

doi: 10.1016/j.bjane.2012.09.001

initiated volume preload, and performed blood work (hemoglobin level was 9.1 g.dL<sup>-1</sup>). We obtained consent for surgery and anesthesia, and transferred the patient to the operating room.

Both the patient and the fetus were stable upon arrival in the operating room. We monitored ECG, non-invasive blood pressure and SpO<sub>2</sub>, and administered oxygen 5 L.min<sup>-1</sup> via facemask, inserted another 18G intravenous canula to the antecubital vein for rapid volume expansion and performed spinal anesthesia with the patient in the sitting position. We placed a 25-gauge spinal needle atraumatically in the first attempt to the subarachnoid area at L3-L4 level and injected 2.5 mL of hyperbaric bupivacaine 0.5% without incident. At this point the patient had received a total of 600 mL of crystalloid solution through both catheters. The patient was positioned in supine and the surgery began at the 10<sup>th</sup> minute of spinal anesthesia. Five minutes later, the patient had nausea while her arterial pressure tended to decrease slightly (Table 1). We administered ephedrine 5 mg twice and accelerated IV fluid administration by squeezing the IV fluid bag with a pneumatic pressure infuser. A healthy male infant was delivered with an APGAR score 9. We administered IV oxytocin 10 IU. Blood loss was approximately 400 mL and 1,100 mL of fluid had been administered up to this point. Between the 25<sup>th</sup> and 30<sup>th</sup> minutes of spinal anesthesia, the patient had suddenly become agitated and confused with

SpO<sub>2</sub> levels 84-80%. We administered ephedrine 10 mg, midazolam 2 mg IV and began performing manual mask ventilation with 100% oxygen. The pulse of radial artery was palpable, both lungs were easily expanded with low airway resistance, but the SpO<sub>2</sub> level was decreasing and EtCO<sub>2</sub> was 12 mm Hg. At this time, the anesthesiologist recognized the IV administration set (both drip chamber and tubing) full of air and clamped immediately. There was also some amount of air in the IV bag (measured as 55 mL after the case) with no fluid remaining. We administered propofol 100 mg and rocuronium 20 mg and performed urgent endotracheal intubation, but the EtCO<sub>2</sub> level did not change and SpO<sub>2</sub> values decreased. Circulatory collapse developed in minutes and was treated with noradrenaline, atropine, adrenaline and volume expansion with a colloid solution (Table 1). After we restored hemodynamic condition, we inserted an arterial cannula and placed a central venous catheter to the left internal jugular vein (the attempt at the right internal jugular vein failed). Repeated attempts to aspirate the air from the central venous catheter had failed. The first arterial blood gases analysis revealed pH: 7.27, pCO<sub>2</sub>: 43 mm Hg, pO<sub>2</sub>: 111 mm Hg, HCO<sub>3</sub><sup>-</sup>: 19 mmol.L<sup>-1</sup>, BE: -7 mmol.L<sup>-1</sup>, lactate: 3 mmol.L<sup>-1</sup>. Before extubation pH was 7.38 and lactate level decreased to 2 mmol.L<sup>-1</sup>. The patient was extubated 50 minutes after surgery. The patient regained consciousness with no neurologic deficits and was transferred to the postoperative care unit.

**Table 1** - Time course of hemodynamic and respiratory changes.

Time* (min)	HR (bpm)	ABP (mm Hg)	EtCO <sub>2</sub> (mm Hg)	SpO <sub>2</sub> (%)	
0	80	130/70	-	97	Before spinal anesthesia
5.	78	120/60	-	100	5 l/min O <sub>2</sub> supply with facemask
10.	82	110/55	-	100	Surgery started
15.	84	100/55	-	100	Ephedrine 5+5 mg administered
20.	88	105/50	-	100	Delivery of the baby
25.	78	95/50	-	100	
28. <sup>a</sup>	120	100/50	12	82	Mask ventilation, ephedrine 10 mg
30.	125	110/45	12	60	Endotracheal intubation
32.	122	80/35	10	55	Noradrenaline 80+80 µg
34.	45	-	10	50	Atropine 1 mg + noradrenaline 160 µg
36.	17	-	10	-	Atropine 2 mg + adrenaline 1 mg
38.	144	90/50	15	80	
40.	150	145/70	60	97	
45.	138	135/70	55	98	
60.	125	120/60	45	98	Surgery ended
110.	105	120/70	35	100	Extubation
130.	95	110/70	-	98	Post-anesthesia care unit

HR: heart rate, ABP: arterial blood pressure (systolic/diastolic), EtCO<sub>2</sub>: end tidal CO<sub>2</sub>, SpO<sub>2</sub>: peripheral oxygen saturation, \*After spinal anesthesia, <sup>a</sup> Estimated time for air entry.

After the case, a conversation with the nurse anesthetist cleared the story: when positioning the patient for spinal anesthesia, the IV administration set detached from the IV line and soiled unintentionally. When changing the set, she had turned the IV bag upside down (as in Figure 1-A) and some air entered into it. Using a pneumatic pressure infuser for rapid volume administration caused VAE.

## Discussion

Generally, a small amount of air in the venous vasculature gets absorbed spontaneously without sequel, but the rapid entry of a large amount of air can result in significant morbidity and mortality. The lethal volume of air has been described as 200-300 mL or 3-5 mL.kg<sup>-1</sup> for adults from case reports, while the rate of air entrainment is also important<sup>2</sup>. To calculate the estimated volume of air entered into the current patient's vasculature, we tested two different kinds of 1,000 mL IV fluid bags available in our institute and found some interesting outcomes.

Polyvinyl chloride (PVC) is a chemical widely used in the manufacturing of collapsible IV fluid containers preferred for its flexibility. However, vinyl-containing products represent a health risk<sup>3</sup> and environmental hazard and many health-care companies have undertaken programs designed to find replacements for PVC. The IV fluid bag in this recent case was a polypropylene (PP)-based material with lower flexibility compared with PVC. We tested PVC and PP-based bags, changed the IV set by turning the bag upside down (as in the recent case) after various amounts of fluid were evacuated, and then measure the amount of air in the bag with a 50 mL syringe and a three-way stopcock. We repeated the test 5 times and the median results are shown in Table 2. After changing the IV administration set, the amount of air entered into the IV fluid bag depends on the volume of fluid used (if more fluid was used, there will be more space for air entry) and the flexibility of the bag, while flexibility significantly limits the amount of air entry (Table 2).

By the time that nurse anesthetist changed the IV set in the recent case, the volume of fluid used in the 1,000 mL bag was 300-400 ml and we found that a maximum of 240-300 mL

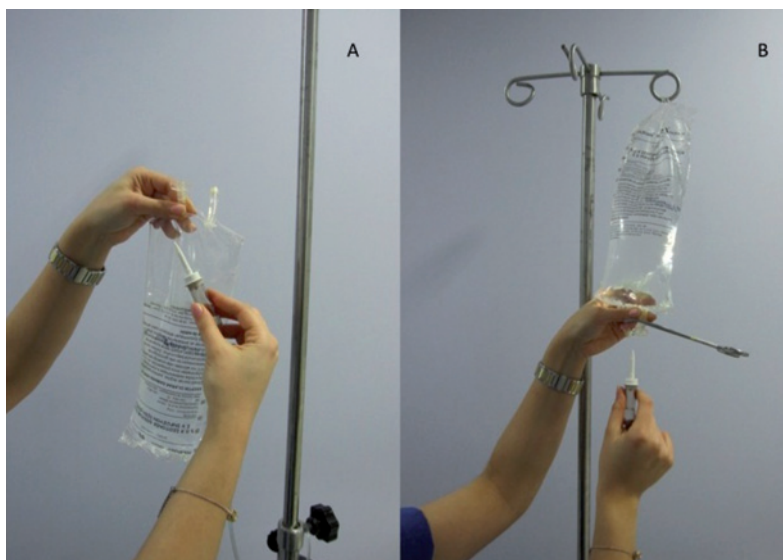


Figure 1 - Two ways for changing IV administration set.

Table 2 - Volume of air entry into an infusion bag after changing the administration set.

	Volume of fluid evacuated (mL)*					
	0	100	200	300	400	500
Volume of air entered into a PVC-based bag (mL)	35 ± 2	75 ± 6	105 ± 6	130 ± 9	120 ± 10	110 ± 8
Volume of air entered into a PVC-free bag (mL)	40 ± 3	110 ± 7	150 ± 8	240 ± 13	300 ± 16	370 ± 18
p	< 0.05	< 0.01	< 0.01	< 0.01	< 0.01	< 0.01

\*Test repeated 5 times after turning IV bag upside down as shown in Figure 1-A, values are median ± S.D.

of air can enter into a PP bag at the same conditions while in a PVC bag this amount decreases to 120-130 mL. The amount of air remaining in the bag in this recent case was 55 mL and the volume of drip chamber and tubing was 15 mL. Thus, the estimated volume of air embolism was 170-230 mL.

In literature, plastic bottles have been responsible for the risk of VAE<sup>4,5</sup>. One of the reasons to use self-collapsible IV fluid bags instead of conventional glass or plastic bottles is to take precaution against air embolism. Air embolism is out of the question when collapsible bags are used as a closed infusion system. To our knowledge, this is the second case report on venous air embolism related to the use of collapsible IV fluid bags, where the estimated volume of air entry and the bag's material were not mentioned in that case<sup>6</sup>. There is risk for impairment of this closed system when IV administration set is disconnected from the outlet. Self-sealing outlets become safe guards to prevent air embolism and contamination. When the administration set has to be changed, the outlet of the bag may be clamped with a forceps to prevent air entry (Figure 1-B).

The incidence of VAE during cesarean delivery reportedly ranges between 11% and 97%, depending on the sensitivity of diagnostic tools used during the procedures and the patient's position<sup>1</sup>. Predisposing factors in pregnancy include placenta previa, previous uterine surgery, hypovolemia and maternal positioning. Air entrance from ruptured uterine veins, especially during manual extraction of the placenta, is usually without clinical consequence despite its common occurrence. In the aforementioned case, possible air embolism from the surgical site may worsen the clinical effect of iatrogenic air embolism.

Due to increases in the right ventricular afterload, VAE may lead to acute right ventricular failure and a subsequent decrease in left ventricular output<sup>2</sup>. Inotropic support to overcome the afterload is the logical management of this condition, while adrenaline was more effective than norepinephrine in our case.

In conclusion, collapsible intravenous fluid bags without self-sealing outlet carry risk of air embolism if the closed system is broken down, while the bag's flexibility decreases the amount of air entry. Using a pressure bag for rapid infusion can be dangerous without checking and emptying all air from the IV bag. Clinicians must be aware of this possibility, especially when other predisposing conditions exist - such as the cesarean section.

## References

1. Lew TW, Tay DH, Thomas E - Venous air embolism during caesarean section: More common than previously thought. *Anesth Analg.* 1993;77:448-452.
2. Mirski MA, Lele AV, Fitzsimmons L, Toung TJK - Diagnosis and treatment of vascular air embolism. *Anesthesiology.* 2007;106:164-177.
3. Food and Drug Administration (FDA), Public Health Notification: PVC Devices Containing the plasticizer DEHP. Center for Devices and Radiological Health. From, [www.fda.gov/safety/dehp.html](http://www.fda.gov/safety/dehp.html). Accessed July 2002.
4. Gray AJ, Glover P - Air emboli with Haemaccel®. *Anaesthesia.* 1999;54:790-792.
5. Suwanpratheap A, Siriussawakul A - Inadvertent venous air embolism from pressure infuser bag confirmed by transesophageal echocardiography. *J Anesth Clin Res.* 2011;2:2-10.
6. Pant D, Narani KK, Sood J - Significant air embolism: A possibility even with collapsible intravenous fluid containers when used with rapid infusion system. *Indian J Anaesth.* 2010;54:49-51.