






Fatal hemorrhage from peripheral varicose vein rupture

Guendalina Gentile¹ , Stefano Tambuzzi¹ , Michele Boracchi¹ ,
Alessandro Del Gobbo² , Paolo Bailo¹ , Riccardo Zoia¹ 

How to cite: Gentile G, Tambuzzi S, Boracchi M, Gobbo A, Bailo P, Zoia R. Fatal hemorrhage from peripheral varicose vein rupture. *Autops Case Rep* [Internet]. 2021;11:e2021330. <https://doi.org/10.4322/acr.2021.330>

ABSTRACT

Varix of the lower extremities is a common entity that eventually presents fatal outcome. Fatal massive bleeding due to rupture of a peripheral varicose vein is rare. The estimated incidence of these cases is 1/1000 autopsies. The case we present is unique among 26,054 autopsies performed in Milan from 1993 to 2020. It describes the investigations carried out in the suspicion of a non-natural event in an elderly woman. She was found dead at home with a large volume of blood near her feet that drained from the right leg. Pathological examination disclosed that the hemorrhage occurred by the rupture of a venous varix of the lower limb. Cases of fatal hemorrhage from peripheral variceal rupture are insidious and require proper characterization. The bloodstain pattern analysis, careful autopsy dissection by layers to demonstrate the rupture, and histologic examination of the lesion are the essential elements to find out the actual cause of death.

Keywords

Autopsy; Hemorrhage; Varicose veins.

INTRODUCTION

Chronic venous insufficiency (CVI) is present in 15-50% of the general population.^{1,2} It is rarely considered a life-threatening entity.³ The peripheral venous tortuosity is usually localized to the lower limbs.⁴ The risk factors associated with CVI are female gender, age, family history, obesity, and prolonged work activity in an orthostatic stance.⁵ Spontaneous or trauma-related⁶ rupture of the varix is an unusual complication.^{3,7} This eventual complication leads to an unexpected natural death due to severe bleeding and is documented in 0.15-2% of the population or in less than 1 in 1000 autopsy cases.^{6,8-12} The venous bleeding is distinguishable from the arterial bleeding¹¹ by its

proximity of the bleeding source due to the lower pressure of the venous system.¹³ However, in some cases, it may show a projected, scattered appearance when the pressure of blood in the distended veins is high.¹³ Thus, severe bleeding observed may raise misinterpretations and doubts about the injury mechanism.^{1,13} These cases require an often-challenging differential diagnosis between a non-natural cause of death and an accidental event.^{6,14} Our report discusses the challenges to understand the mechanism of the vessel injury and the cause of death on a single case of lethal rupture of the right lower limb varix in an older woman.

¹ Università degli Studi di Milano, Dipartimento di Scienze Biomediche per la Salute, Sezione di Medicina Legale e delle Assicurazioni, Laboratorio di Istopatologia Forense e Microbiologia Medico Legale, Milano, Italy

² Fondazione IRCCS Ca' Granda - Ospedale Maggiore Policlinico Milano, Anatomia Patologica, Milano, Italy



CASE REPORT

A 91-year-old, self-sufficient, and lonely woman was found dead by the police; after two days, the neighbors did not see her. She was found sitting near the refrigerator with a pool of blood (measuring 87 cm in transverse diameter and 72 cm in longitudinal diameter) at her feet, despite other major blood traces scattered over the floor. Also, the victim's right hand showed traces of the same type. An already opened package of oral antiplatelet drugs (*Ticlid*, 250 mg) was found on the bedside table that the victim was eventually taking. The blood was localized and clustered in the hallway and near the chair where the deceased lady had been found. Also, a 2-euro metal coin smeared with blood on both sides was found. The pattern of blood flow lacked high-pressure projections; it was not scattered and did not show typical signs of high-pressure blood spillage (typically observed in arterial origin hemorrhage). This observation allowed us to consider it a venous type of bleeding. An autopsy 3 days after the discovery was undertaken by judicial request.

Autopsy findings

On external examination, the corpse was in good conditions of nutrition and preservation. No signs of traumatic injuries or defense wounds were found. The hypostasis was reduced in intensity and extension. This finding was consistent with death due to acute hemorrhagic shock. The lower limbs showed clear signs of chronic venous disease and diffuse brownish dyschromic areas between 0.2 and 0.5 cm in diameter. A bluish serpiginous tegumentary swelling was observed at the distal third of the right leg on the anteromedial surface, and a minor full-thickness skin breach with the underlying venous wall was disclosed. The wound had irregular raised blood-stained margins, and it measured 0.5 x 0.3 cm (Figure 1).

The internal organs were diffusely pale. The brain parenchyma showed a yellowish and softened area in the left temporal area. Bilateral apical whitish pleural thickenings were documented, and reduced thickness of the renal cortex and atherosclerotic disease of the aorta and coronary arteries. There was no evidence of myocardial infarction. The only bleeding site was found in the right lower limb.

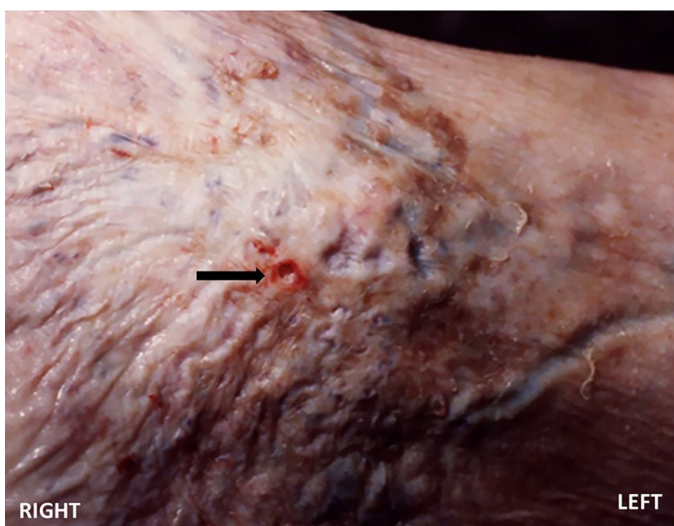

Figure 1. Right to left gross view of the venous tortuosity and break of the integument and venous wall (arrow).

No other source of traumatic or natural bleeding was detected. After the autopsy, the cause of death was identified as acute hemorrhagic shock secondary to the rupture of a venous varix of the right lower limb. The histological analysis of the skin fragment taken from the suspected bleeding site was undertaken. The microscopic study of the remaining organs was not allowed.

Microscopic features

The skin fragment was processed with standard post-fixative histological examination. In the dermo-epidermal sample, the histological examination documented the cross-section of a markedly ectatic venous blood vessel, characterized by a thin wall and without smooth muscle fibers, filled with blood. The venous vessel was 80% occluded by a thrombotic material and was superficial to the skin layer at the point of rupture with discontinuity of the overlying tissues (Figure 2).

DISCUSSION

The first reports of death from acute bleeding by peripheral varicose veins rupture date from the 1970s.¹⁵ Two major types of bleeding ulcers have been described. The first is acute perforated ulcers with small superficial lesions and adjacent pigmentation in surrounding healthy skin.¹⁶ The other type is chronic ulcerative ulcers (more extensive

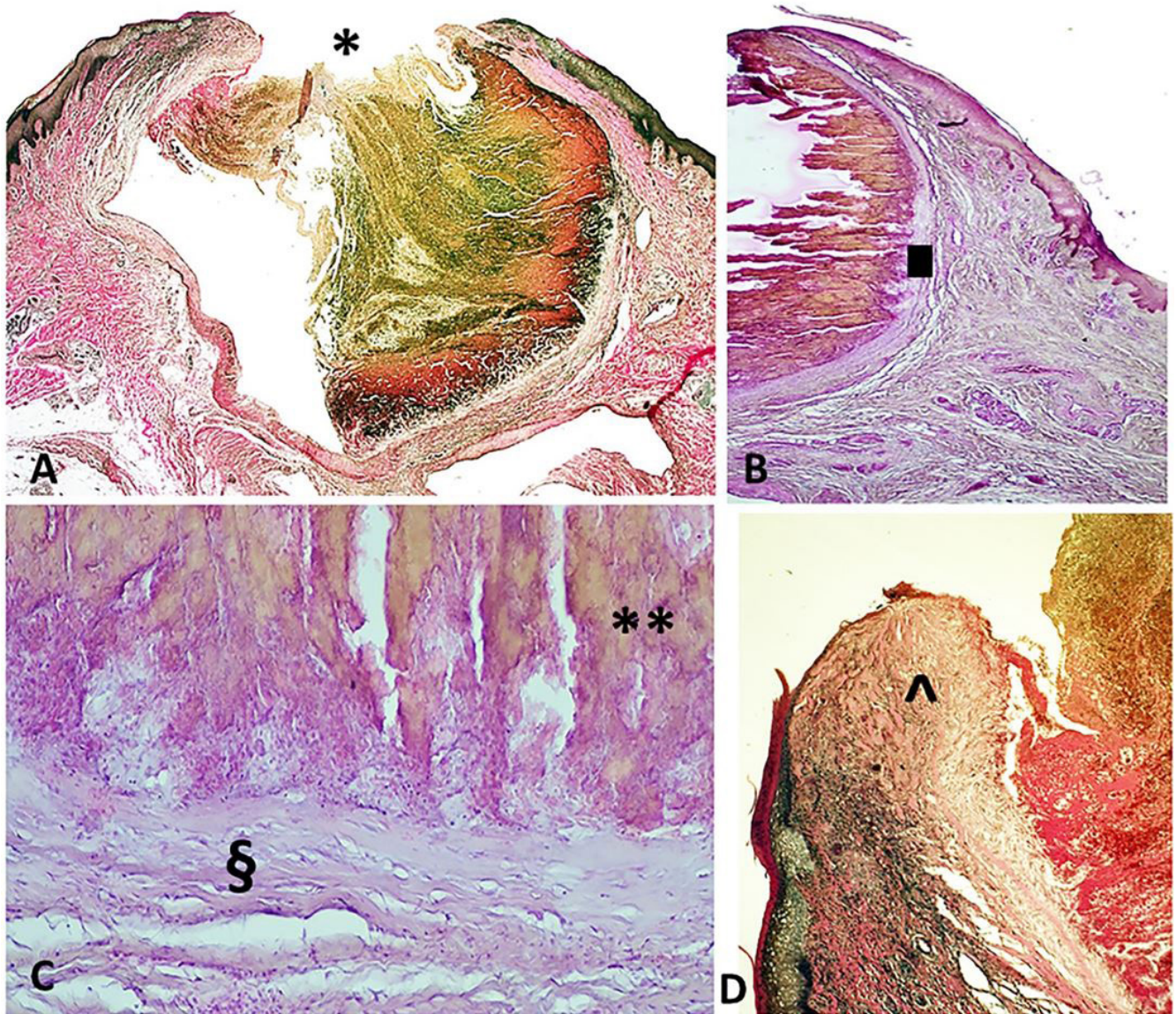


Figure 2. Photomicrographs of the vascular lesion. **A** – Panoramic view of the dermo-epidermal specimen including a cross-section of a superficial venous vessel at the point of rupture (*) with discontinuity of overlying tissues (van Gieson's trichrome, 2x); **B** – The subcutaneous soft tissue site of vascular ectasia of the venous origin. Note the lacking of muscular layer () and blood congestion (H&E, 20x); **C** – Phlebo-thrombotic material is characterized by numerous red blood cells alternating with layers of fibrin (Zahn's lines) (***) and initial adhesion/organization (§) (H&E, 40x); **D** – Granulation tissue (^) (van Gieson's trichrome, 10 x).

and more profound than the previous ones). This first description of acute varicose vein bleeding was followed by reports of spontaneous ruptures,^{2,3,17} or due to minor traumas.¹⁸ In the forensic field, the rare complication of fatal bleeding in subjects affected by limb venous varicosity¹⁸ is scarcely reported. The search performed on PubMed NCBI reports only 13 cases of pathological-forensic relevance.^{1-4,6,8,11-14,19,20} Many patients diagnosed with varicosities of non-severe degree underestimate the threaten of this entity.

They consider it an aesthetic problem than a medical concern. However, this entity carries the potential threaten of massive and lethal bleeding. The time-lapse of death is between 5 and 20 minutes; despite the elevation of the affected limb and compression of the bleeding point seem easy maneuvers to save life.²¹ The risk of life-threatening rupture of peripheral varicosities is increased in the affected subjects that are socially vulnerable or in conditions of social isolation. This typically occurs in the elderly, who constitute the

most exposed and vulnerable patients, because of their skin and soft tissue fragility.¹¹ Therefore, more spontaneous and severe lesions are documented in these patients, even in apparently "intact" varices at the gross examination or after mild traumas than in younger people.^{11,12} The resulting profuse bleeding could be arrested with simple therapeutic hemostatic or adequate compression procedures.¹⁰ Yet the lack of awareness of the danger, the neglect, and/or the cognitive impairment may lead them to overlook a minor, continuous, and painless venous bleeding¹¹ that, conversely, could prove to be unstoppable and, therefore, lethal.¹⁹

In the presented case, the 91-year-old lady lived alone. She had visible superficial peripheral varices and showed skin changes from chronic venous stasis. She was found in her home with a pool of blood near her feet which led the police to hypothesize a lethal injury despite the absence of signs of physical aggression such as fatal wounds. The only finding was the right lower limb was the single bleeding vascular lesion. Histologically, the latter was characterized as an ulcer of a very superficial dilated varicose vein, thin-walled and lacking smooth muscle and, as such, capable of predisposing to profuse bleeding.¹² The bloodstain pattern analysis performed was consistent with venous bleeding, characterized by low pressure. The blood pool near the deceased was below the bleeding point from which it originated, which contributed to confirming the venous bleeding hypothesis.

We hypothesized two possible mechanisms as the cause of injury: a minor trauma, such as rubbing the right leg with an object, or a spontaneous rupture. We believe that the weakness of the ulcerated skin and vein wall contributed significantly to the rupture of the venous vessel. Regarding the presence of a 2-euro coin within the blood pool, we hypothesized that the patient tried to use it to stop the bleeding. Metal coins were considered an effective hemostatic means for small bleedings, according to a past popular tradition. Moreover, the chronic therapeutic use of oral platelet antiaggregant drug and the lack of assistance or request for help were further crucial factors for establishing a fatal bleeding condition.

This case of fatal hemorrhage from a peripheral varicose vein rupture as a cause of sudden death highlights the dangerous nature of chronic venous

disease (which threat to life is neglected). It rapidly led to the end of life of a lonely and highly vulnerable older woman. The pathologist had to be careful before commenting on the cause and manner of death. The association of the blood pattern analysis and a thorough autopsy, the careful scene in which the deceased was found, together with the histological examination, represented the elements on which the final judgment was based. The actual incidence of such events is not yet fully known. It is, therefore, crucial to report these rare events because they undoubtedly can be a cause of sudden death.

REFERENCES

1. Aquila I, Sacco MA, Gratteri S, Di Nunzio C, Ricci P. Sudden death by rupture of a varicose vein: case report and review of literature. *Med Leg J.* 2017;85(1):47-50. <http://dx.doi.org/10.1177/0025817216678712>. PMID:28112026.
2. Morrow PL, Hardin NJ, Karn CM, Beloin R, McDowell RW. Fatal hemorrhage caused by varicose veins. *Am J Forensic Med Pathol.* 1994;15(2):100-4. <http://dx.doi.org/10.1097/00000433-199406000-00003>. PMID:8074099.
3. Racette S, Sauvageau A. Unusual sudden death: two case reports of hemorrhage by rupture of varicose veins. *Am J Forensic Med Pathol.* 2005;26(3):294-6. <http://dx.doi.org/10.1097/01.paf.0000176283.19127.0e>. PMID:16121090.
4. Nikolić S, Živković V. Bloodstain pattern in the form of gushing in a case of fatal exsanguination due to ruptured varicose vein. *Med Sci Law.* 2011;51(1):61-2. <http://dx.doi.org/10.1258/msl.2010.010129>. PMID:21595424.
5. Beebe-Dimmer JL, Pfeifer JR, Engle JS, Schottenfeld D. The epidemiology of chronic venous insufficiency and varicose veins. *Ann Epidemiol.* 2005;15(3):175-84. <http://dx.doi.org/10.1016/j.annepidem.2004.05.015>. PMID:15723761.
6. Doberentz E, Hagemeyer L, Veit C, Madea B. Unattended fatal haemorrhage due to spontaneous peripheral varicose vein rupture--two case reports. *Forensic Sci Int.* 2011;206(1-3):e12-6. <http://dx.doi.org/10.1016/j.forsciint.2010.06.020>. PMID:20655677.
7. Nikolić S, Živković V. Fatal exsanguination due to ruptured varicose vein of the lower leg: case report. *Srp Arh Celok Lek.* 2011;139(11-12):819-23. <http://dx.doi.org/10.2298/SARH1112819N>. PMID:22338484.
8. Ampanozi G, Preiss U, Hatch GM, et al. Fatal lower extremity varicose vein rupture. *Leg Med (Tokyo).* 2011;13(2):87-

90. <http://dx.doi.org/10.1016/j.legalmed.2010.11.002>. PMID:21144790.
9. Hejna P, Ublova M, Straka L, Zatopkova L. Unattended fatal haemorrhage associated with spontaneous rupture of peripheral varicosity. *Soud Lek.* 2012;57(2):18-20. PMID:22724651.
 10. Cocker DM, Nyamekye IK. Fatal haemorrhage from varicose veins: is the correct advice being given? *J R Soc Med.* 2008;101(10):515-6. <http://dx.doi.org/10.1258/jrsm.2008.080132>. PMID:18840868.
 11. Hejna P. A case of fatal spontaneous varicose vein rupture-an example of incorrect first aid. *J Forensic Sci.* 2009;54(5):1146-8. <http://dx.doi.org/10.1111/j.1556-4029.2009.01101.x>. PMID:19627413.
 12. Byard RW, Gilbert JD. The incidence and characteristic features of fatal hemorrhage due to ruptured varicose veins. A 10-year autopsy study. *Am J Forensic Med Pathol.* 2007;28(4):299-302. <http://dx.doi.org/10.1097/PAF.0b013e31814250b3>. PMID:18043015.
 13. Byard RW, Veldhoen D, Manock C, Gilbert JD. Blood stain pattern interpretation in cases of fatal haemorrhage from ruptured varicose veins. *J Forensic Leg Med.* 2007;14(3):155-8. <http://dx.doi.org/10.1016/j.jcfm.2006.02.025>. PMID:16730472.
 14. Gentile G, Galante N, Tambuzzi S, Zoja R. A forensic analysis on 53 cases of complex suicides and one complicated assessed at the Bureau of Legal Medicine of Milan (Italy). *Forensic Sci Int.* 2021;319:110662. <http://dx.doi.org/10.1016/j.forsciint.2020.110662>. PMID:33401231.
 15. Evans GA, Evans DM, Seal RM, Craven JL. Spontaneous fatal haemorrhage caused by varicose veins. *Lancet.* 1973;2(7842):1359-61. [http://dx.doi.org/10.1016/S0140-6736\(73\)93325-4](http://dx.doi.org/10.1016/S0140-6736(73)93325-4). PMID:4128056.
 16. Wigle RL, Anderson GV Jr. Exsanguinating hemorrhage from peripheral varicosities. *Ann Emerg Med.* 1988;17(1):80-2. [http://dx.doi.org/10.1016/S0196-0644\(88\)80511-0](http://dx.doi.org/10.1016/S0196-0644(88)80511-0). PMID:3337422.
 17. Cittadini F, Albertacci G, Pascali VL. Unattended fatal hemorrhage caused by spontaneous rupture of a varicose vein. *Am J Forensic Med Pathol.* 2008;29(1):92. <http://dx.doi.org/10.1097/PAF.0b013e318165c08e>. PMID:19749628.
 18. Sauvageau A, Schellenberg M, Racette S, Julien F. Bloodstain pattern analysis in a case of fatal varicose vein rupture. *Am J Forensic Med Pathol.* 2007;28(1):35-7. <http://dx.doi.org/10.1097/01.paf.0000257390.59657.6a>. PMID:17325461.
 19. Serinelli S, Bonaccorso L, Gitto L. Fatal bleeding caused by a ruptured varicose vein. *Med Leg J.* 2020;88(1):41-4. <http://dx.doi.org/10.1177/0968533219885621>. PMID:31928306.
 20. Gilbert JD, Byard RW. Ruptured varicose veins and fatal hemorrhage. *Forensic Sci Med Pathol.* 2018;14(2):244-7. <http://dx.doi.org/10.1007/s12024-017-9897-y>. PMID:28695421.
 21. Serra R, Ielapi N, Bevacqua E, et al. Haemorrhage from varicose veins and varicose ulceration: a systematic review. *Int Wound J.* 2018;15(5):829-33. <http://dx.doi.org/10.1111/iwj.12934>. PMID:29808553.

This study was carried out at the Institute of Forensic Medicine. Milan, Italy

Authors' contributions: Guendalina Gentile and Stefano Tambuzzi equally contributed to this work. They devised the project and the main conceptual idea of the article, collected data, drafted the manuscript and performed literature research. Michele Boracchi devised the project of the article and drafted the manuscript. Alessandro Del Gobbo performed the histological analyses. Paolo Bailo realized important contribution to the article's review and editing. Riccardo Zoia guarantor of the project and directed the study, devised the main conceptual idea of the article.

Ethics statement: The subject involved in this study underwent a judicial autopsy at the Institute of Legal Medicine of Milan in order to identify the cause of death. Data collecting, sampling and subsequent forensic analysis were authorized by the inquiring magistrate. Consequently, in accordance with Italian law, ethical approval is not required in these cases. Publication of data is allowed when the case has been closed, but the anonymity of the subject must be guaranteed.

Conflict of interest: None

Financial support: None

Submitted on: July 27th, 2021

Accepted on: August 28th, 2021

Correspondence

Guendalina Gentile

Università degli Studi di Milano, Sezione di Medicina Legale e delle Assicurazioni
via Luigi Mangiagalli, 37, 20133, Milano, Italy

Phone: + 3 (90) 25031-5721 / Fax: +3 (90) 25031-5724

guendalina.gentile@unimi.it

ERRATUM: Fatal hemorrhage from peripheral varicose vein rupture

Due to copyediting error the article “Fatal hemorrhage from peripheral varicose vein rupture” (DOI <https://doi.org/10.4322/acr.2021.330>), published in *Autops. Case Rep*, 11, 2021, was published with an error in the author’s name in How to cite.

On How to cite, where the text reads:

How to cite: Gentile G, Tambuzzi S, Boracchi M, Gobbo A, Bailo P, Zoia R. Fatal hemorrhage from peripheral varicose vein rupture. *Autops Case Rep* [Internet]. 2021;11:e2021330. <https://doi.org/10.4322/acr.2021.330>

It should read:

How to cite: Gentile G, Tambuzzi S, Boracchi M, Del Gobbo A, Bailo P, Zoia R. Fatal hemorrhage from peripheral varicose vein rupture. *Autops Case Rep* [Internet]. 2021;11:e2021330. <https://doi.org/10.4322/acr.2021.330>

The publisher apologizes for the errors.

