

## An unusual ventriculoperitoneal shunt complication: catheter migration into the breast

Adilson José Manuel de Oliveira<sup>a,b</sup> , Jefferson Rossi Júnior<sup>a</sup> ,  
Martha Natalia Burgos Morales<sup>a</sup> , Bruno Monteiro Reis<sup>a</sup> ,  
Fernando Campos Gomes Pinto<sup>a</sup> 

**How to cite:** de Oliveira AJM, Rossi Júnior J, Morales MNB, Reis BM, Pinto FCG. An unusual ventriculoperitoneal shunt complication: catheter migration into the breast. *Autops Case Rep* [Internet]. 2020 Apr-Jun;10(2):e2020165. <https://doi.org/10.4322/acr.2020.165>

### Keywords:

Ventriculoperitoneal Shunt; Breast Implants; Neurosurgery

### DEAR EDITOR

We present the second case, in medical literature, of intracranial hypertension caused by ventriculoperitoneal shunt (VPS) migration into the breast, in a 31-year-old woman who had breast silicone implants performed for esthetic reasons.

VPS placement is one of the most common surgical procedures performed in neurosurgery. This procedure may be associated with mechanical and non-mechanical complications. The most distressing mechanical complication is the shunt migration. Several catheter migrations sites, such as to the intracranial, subdural, subgaleal, chest wall/thorax, breast, cardiac/intravascular, abdominal wall, genitourinary system, and bowel, were described.<sup>1</sup>

VPS migration into the breast accounts for approximately 3% of all catheter migrations, with or without pseudocyst formation and shunt obstruction. The earliest breast-related complication in a patient with VPS was retrograde cerebrospinal fluid (CSF) tracking described by Nakano et al. 1994.<sup>2</sup> During the last decade, a rise in breast-related complications of VPS have been noted (especially shunt migration),

which is probably related to the increase in breast implants and mammoplasty.<sup>3</sup> There were 13 previous case reports of VPS distal catheter migration into the breast from 2005 to 2019.<sup>3</sup>

We report the case of a 31-year-old woman with hydrocephalus secondary to spontaneous intracerebral hemorrhage caused by a cerebral arteriovenous malformation (AVM).

A VPS placement was performed with a good outcome; however, at the 6-month outpatient follow-up, the patient presented with breast asymmetry and symptoms of intracranial hypertension.

This patient, a 31-year-old woman, previously healthy, who experienced a sudden intense headache and drowsiness, attended the emergency department. She was somnolent without focal neurological deficits. Her past medical history revealed mammary implants of silicone for aesthetic reasons. The investigations with head computed tomography and angiography showed a subarachnoid hemorrhage secondary to AVM (Spetzler–Martin grade 5), with hydrocephalus. The patient was submitted to a VPS procedure with

<sup>a</sup> Universidade de São Paulo (USP), Faculty of Medicine, Neurosurgery Department. São Paulo, SP, Brazil.

<sup>b</sup> Clínica Girassol, Neurosurgery Service. Luanda, Angola.



good postoperative recovery. She was discharged 3 weeks later, asymptomatic, and scheduled for elective treatment for the AVM.

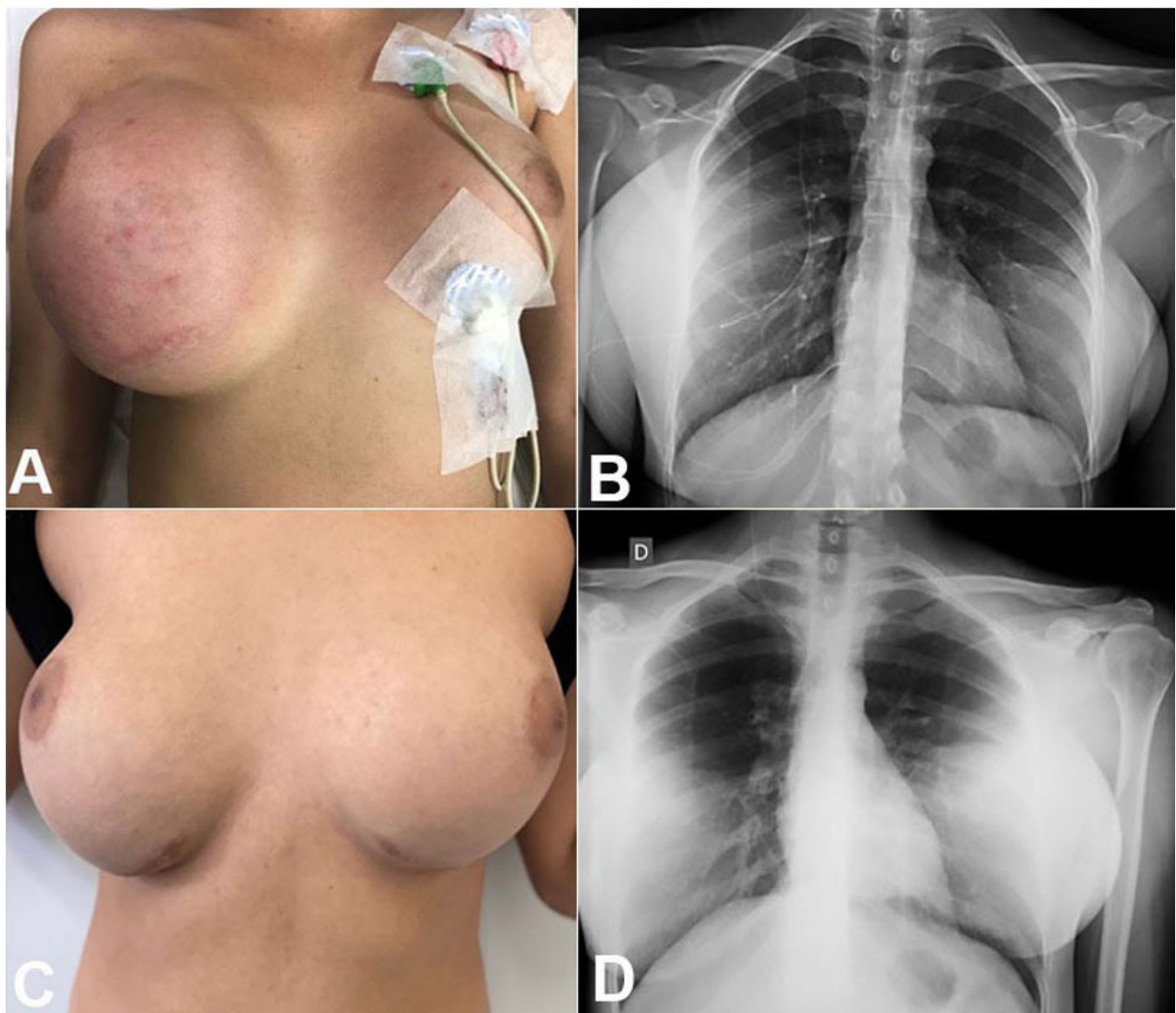
Seven months later, the patient complained of a moderate intensity headache refractory to analgesia and vomiting. A week later, she noted an increase in the size of her right breast and came to an outpatient clinic evaluation.

On clinical examination, the patient was awake and aware with no motor or cranial nerve impairments, the patient had bilateral papilledema in the fundus. The breast examination revealed an increase in the

size of her right breast with inflammatory signs and a palpable liquid collection (Figure 1A).

The patient was submitted to ultrasonography, which showed the integrity of the silicone implant and the presence of the VPS catheter inside this capsule. An x-ray of the thorax and abdomen showed the distal catheter of VPS outside the abdomen and inside the right breast (Figure 1B).

Surgical revision of the VPS system was performed, revealing the distal catheter inside the right breast; however, outside the silicone implant, the catheter was placed medially and inside the peritoneal cavity.



**Figure 1.** **A** – Preoperative examination showing evident breast size asymmetry; **B** – Chest plain radiography showing the VPS catheter coiled into de breast pocket; **C** – postoperative view with the right breast normal size; **D** – Chest plain radiography after VPS replacement into the abdominal cavity.

Post-operatively, the size of the right breast decreased and became symmetrical with the left breast (Figure 1C). The patient's headache and vomiting also improved.

At the 1-year follow-up, the patient was asymptomatic, the breast was still symmetrical, and the x-ray showed the satisfactory position of the distal catheter (Figure 1D).

VPS catheter migration into the breast is a relatively new entity (15 years since it was first described), and consequently, the medical community is unfamiliar with it. This condition is both an aesthetic and a clinical problem because it can be related to VPS malfunction causing intracranial hypertension symptoms, which is a life-threatening condition.<sup>4</sup>

After a literature research, regardless the period, using the following keywords (i) migration of peritoneal catheter, (ii) distal catheter migration, (iii) migration of distal ventriculoperitoneal catheter, (iv) dislocation of ventriculoperitoneal catheter, (v) displacement of ventriculoperitoneal catheter, (vi) ventriculoperitoneal shunt malfunction, (vii) ventriculoperitoneal shunt complications, (viii) complications of distal ventriculoperitoneal shunt catheter AND breast migration in the PubMed and google scholar databases we concluded that our patient is the second case, of VPS breast migration with the malfunction of the system and intracranial hypertension symptoms not associated with central nervous system tumor or infection.

In the first case with this malfunction, it was necessary to remove the breast prosthesis.<sup>5</sup> Another lesson learned in this case is the time from VPS surgery to catheter migration; in the literature, it is typically less than 6 months (with a median duration of 2 months).

The mechanism leading to migration of the distal catheter into the breast may be summed up as the pulling effect of an implant or an inadvertent passage through the implant along with the recoiling nature of the shunt tube promoted by the pushing effect of the raised abdominal pressure (cough/sneeze/strain/obesity). There is a case report of catheter migration to the breast following vigorous breast manipulation.<sup>6</sup>

Catheter migration to the breast may be avoided by making (surgically) guarded tunneling (away from the convexity of the breast) in case of preexisting implants. If an implant is planned in a patient with VPS, it would be advisable to place the implant deeper to the pectoralis major muscle (in the submuscular plane) to avoid complications.<sup>3</sup>

Breast ultrasonography (as used in this case), or thorax tomography, is an effective imaging method for the diagnosis of VPS migration.

VPS migration usually has a good outcome—as in our case—but rapid correction must be performed to avoid neurological impairments or mammary dysfunctions.

Due to the increase in mammary implants for aesthetic reasons, neurosurgeons and plastic surgeons must be aware of this complication of VPS surgery in patients with such implants.

## REFERENCES

1. Harischandra LS, Sharma A, Chatterjee S. Shunt migration in ventriculoperitoneal shunting: a comprehensive review of literature. *Neurol India*. 2019;67(1):85-99. <http://dx.doi.org/10.4103/0028-3886.253968>. PMID:30860103.
2. Nakano A, Tani E, Sato M, Shimizu Y. Cerebrospinal fluid leakage from the nipple after ventriculoperitoneal shunt: case report. *Surg Neurol*. 1994;42(3):224-6. [http://dx.doi.org/10.1016/0090-3019\(94\)90266-6](http://dx.doi.org/10.1016/0090-3019(94)90266-6). PMID:7940108.
3. Schrot RJ, Ramos-Boudreau C, Boggan JE. Breast-related CSF shunt complications: literature review with illustrative case. *Breast J*. 2012;18(5):479-83. <http://dx.doi.org/10.1111/j.1524-4741.2012.01281.x>. PMID:22882605.
4. Rudolph R, Burdick A. Silicone breast implant skewered by a ventriculoperitoneal shunt with secondary cerebrospinal fluid pseudocyst. *Aesthet Surg J*. 2015;35(6):NP179-81. <http://dx.doi.org/10.1093/asj/sjv046>. PMID:26229136.
5. Iyer HP, Jacob LP, Chaudhry NA. Breast cerebrospinal fluid pseudocyst. *Plast Reconstr Surg*. 2006;118(4):87e-9e. <http://dx.doi.org/10.1097/01.prs.0000232394.53652.31>. PMID:16980838.
6. Abode-Iyamah KO, Khanna R, Rasmussen ZD, et al. Risk factors associated with distal catheter migration following ventriculoperitoneal shunt placement. *J Clin Neurosci*. 2016;25:46-9. <http://dx.doi.org/10.1016/j.jocn.2015.07.022>. PMID:26549674.

**Authors' contributions:** All authors contributed equally for the manuscript conception. All authors, collectively, proofread the final version and approved to publication

The authors retained informed consent signed by the patient authorizing the data publication, and the manuscript is according by the Institutional Ethics committee.

**Conflict of interest:** None

**Financial support:** None

**Submitted on:** February 20<sup>th</sup>, 2020

**Correspondence**

Adilson José Manuel de Oliveira  
Neurosurgery Department - Faculty of Medicine - Universidade de São Paulo (USP)  
Alameda Santos, 663, Ap. 34B – Cerqueira Cesar – São Paulo/SP – Brazil  
CEP: 01419-000  
Phone: +55 (11) 99779-2709  
adilsonvalmont@gmail.com