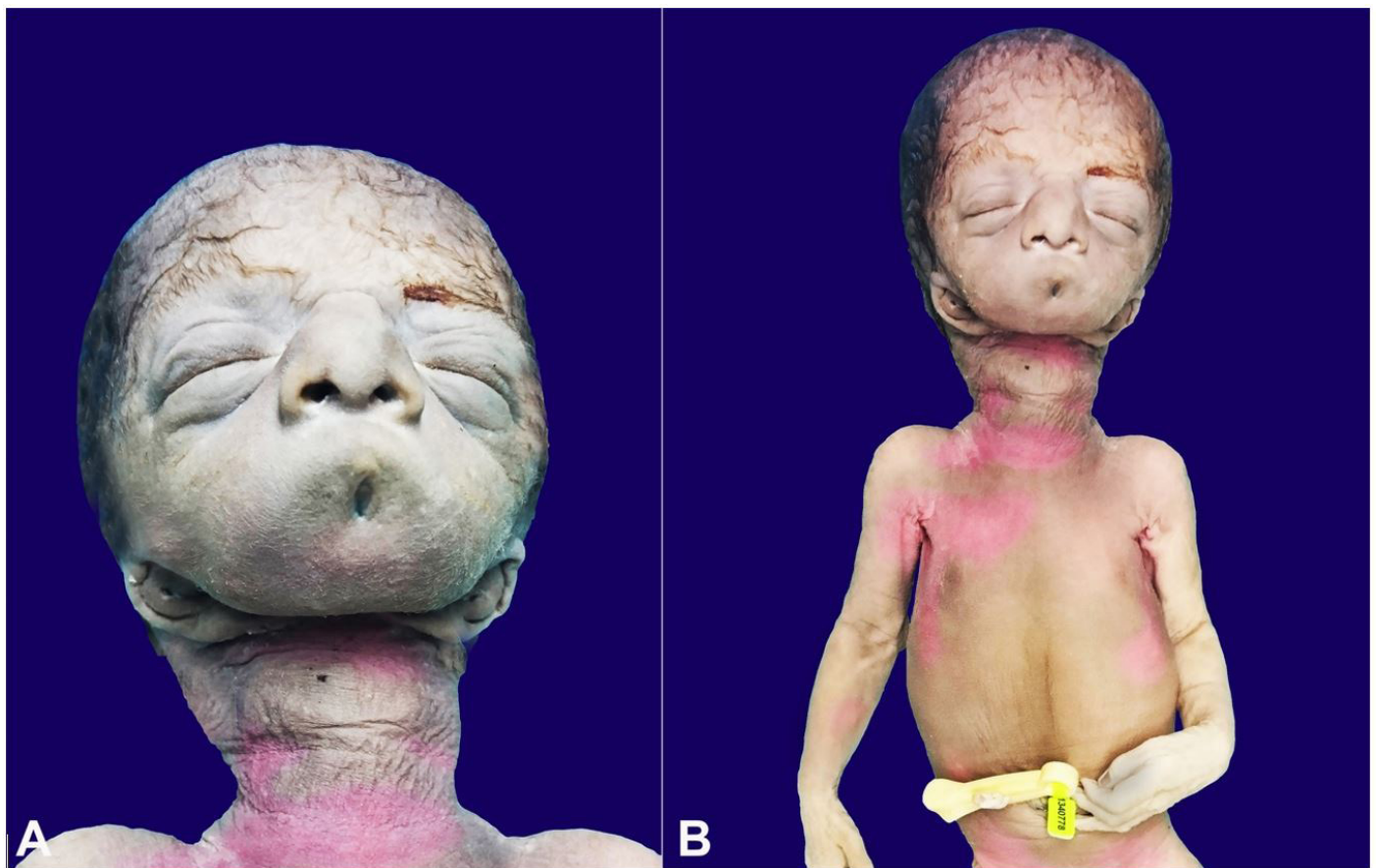


## Agnathia-microstomia-synotia syndrome (otocephaly)

Cristina Díaz del Arco<sup>a,b</sup> , Agustín Oliva<sup>c</sup>, Adela Pelayo Alarcón<sup>a,b</sup>

**How to cite:** Díaz del Arco C, Oliva A, Pelayo Alarcón A. Agnathia-microstomia-synotia syndrome (otocephaly). *Autops Case Rep* [Internet]. 2020 Jan-Mar;10(1):e2020152. <https://doi.org/10.4322/acr.2020.152>



**Figure 1. A and B** – Newborn showing low-implanted ears with midline fusion, severe microstomia and slight neck elongation.

Otocephaly (OC) is a rare congenital disease affecting less than 1 newborn in 70000.<sup>1</sup> However, approximately 65 cases were reported in the last 30 years. The infants show absence or hypoplasia of the mandible (agnathia), ventromedial malposition of

the ears with or without auricular fusion (synotia), and microstomia with hypoplasia or absence of the tongue (aglossia).<sup>2</sup> OC anomalies occur between 4 and 7 weeks of gestation. Facial structures affected by OC are mainly derived from the first pharyngeal arch.<sup>1</sup> This syndrome

<sup>a</sup> Hospital Clínico San Carlos, Department of Pathology. Madrid, Spain.

<sup>b</sup> Complutense University of Madrid. Madrid, Spain.

<sup>c</sup> Hospital Clínico San Carlos, Department of Gynecology and Obstetrics. Madrid, Spain.

could be explained by a defect of blastogenesis or failure of the neural crest cell migration, which leads to midline alterations.<sup>2</sup> OC etiology is not clear; however, it has been related to genetic and teratogenic factors, such as mutations in the PRRX1 gene or unbalanced translocations.<sup>3</sup> Familial aggregation has been occasionally observed.<sup>2</sup> OC can show extracranial malformations (mainly holoprosencephaly). Previous studies classified OC into four groups: (i) agnathia alone; (ii) agnathia with holoprosencephaly; (iii) agnathia with situs inversus and visceral anomalies; and (iv) agnathia with holoprosencephaly, situs inversus, and visceral anomalies. Other extracranial malformations include neural tube defects, cephalocele, corpus colossus dysgenesis, renal ectopia, adrenal hypoplasia and rib, vertebral, or cardiac abnormalities.<sup>4</sup> Severity of OC signs may vary from mandibular hypoplasia to situs inversus and holoprosencephaly.<sup>2,4</sup> Prenatal diagnosis is challenging, and it is commonly suspected when OC occurs together with other alterations, such as polyhydramnios, holoprosencephaly, or situs inversus. Unexpected polyhydramnios has been reported to be the most frequent presenting sign. However, most published cases have been diagnosed beyond 24 weeks of gestation.<sup>1,2</sup> When OC is suspected, facial defects should be carefully investigated, and 3D ultrasound has shown to be more sensitive than 2D ultrasound for this diagnosis.<sup>3</sup>

Our patient's mother was a 24-year-old woman from Nicaragua, with no relevant medical history. Pregnancy was uncontrolled until 32 weeks gestation. An ultrasound study was performed in other institution and revealed polyhydramnios and the absence of the gastric bubble. Five days later, the patient came to our institution's emergency room for prelabor rupture of membranes. Another ultrasound study showed polyhydramnios, hypotelorism, and absence of the lower jaw bone. Clavicles and sternum were not identified. Labor was induced at 34 weeks gestation, and the newborn died right after birth. A perinatal autopsy was performed. Macroscopic examination showed synotia, absence of external ear canal,

agnathia, aglossia, and severe microstomia (Figure 1). We also observed choanal atresia and hypoplasia of the upper pharynx. No sternal or clavicular abnormalities were identified. The position of the organs was normal (situs solitus), and no central nervous system or cardiac anomalies were observed. The microscopical evaluation showed only pulmonary edema.

Otocephaly is usually an incidental finding.<sup>1</sup> However, its early diagnosis is essential for proper care during delivery. Most cases are lethal, and patients show intrauterine growth retardation, prematurity, and impaired ventilation. Endotracheal intubation is difficult due to severe airway malformations, and only approximately 7 non-holoprosencephaly patients have survived beyond infancy.<sup>3</sup> An expert team, family information, premature birth planning, early gastrostomy and tracheostomy, and a long-term treatment plan are essential to ensure proper patient management.<sup>5</sup>

## REFERENCES

1. Gekas J, Li B, Kamnasaran D. Current perspectives on the etiology of agnathia-otocephaly. *Eur J Med Genet.* 2010;53(6):358-66. <http://dx.doi.org/10.1016/j.ejmg.2010.09.002>. PMID:20849990.
2. Faye-Petersen O, David E, Rangwala N, Seaman JP, Hua Z, Heller DS. Otocephaly: report of five new cases and a literature review. *Fetal Pediatr Pathol.* 2006;25(5):277-96. <http://dx.doi.org/10.1080/15513810601123417>. PMID:17438667.
3. Hisaba WJ, Milani HJ, Araujo Júnior E, et al. Agnathia-otocephaly: prenatal diagnosis by two- and three-dimensional ultrasound and magnetic resonance imaging: case report. *Med Ultrason.* 2014;16(4):377-9. PMID:25463893.
4. Jagtap SV, Saini N, Jagtap S, Saini S. Otocephaly: agnathia-microstomia-synotia syndrome: a rare congenital anomaly. *J Clin Diagn Res.* 2015;9(9):ED03-04. <http://dx.doi.org/10.7860/JCDR/2015/13636.6444>. PMID:26500912.
5. Golinko MS, Shetye P, Flores RL, Staffenberg DA. Severe agnathia-otocephaly complex: surgical management and longitudinal follow-up from birth through adulthood. *J Craniofac Surg.* 2015;26(8):2387-92. <http://dx.doi.org/10.1097/SCS.0000000000002150>. PMID:26517463.

**Authors' contributions:** Díaz del Arco C drafted the manuscript and analyzed data. Oliva A and Pelayo Alarcón A provided the data and revised the manuscript. All authors collectively proofread the final version and approved for publication

The manuscript was approved by the Institutional Ethics Committee.

**Conflict of interest:** None

**Financial support:** None

**Submitted on:** January 25<sup>th</sup>, 2020

**Correspondence**

Cristina Díaz del Arco  
Department of Pathology - Hospital Clínico San Carlos  
C/ Professor Martín Lagos, s/n, 28040 – Madrid – Spain  
Phone: +34 913 30 30 01  
crisdelarco@gmail.com