

## Vocal fold mobility alteration reversed after thyroidectomy

Aline Paterno Miazaki<sup>a</sup>, Vergilius José Furtado Araújo-Filho<sup>a</sup>, Lenine Garcia Brandão<sup>a</sup>,  
Vergilius José Furtado de Araujo-Neto<sup>a</sup>, Leandro Luongo Matos<sup>a,b</sup>,  
Claudio Roberto Cernea<sup>a</sup>

Miazaki AP, Araújo-Filho VJF, Brandão LG, Araujo-Neto VJF, Matos LL, Cernea CR. Vocal fold mobility alteration reversed after thyroidectomy. *Autopsy Case Rep* [Internet]. 2016;6(3):53-57. <http://dx.doi.org/10.4322/acr.2016.039>

### ABSTRACT

The involvement of the inferior or recurrent laryngeal nerve (RLN) in mobility derangement of the vocal folds occurs more frequently due to thyroid malignancy invasion. Although uncommon, the same derangement, which is caused by benign thyroid entities, is also described and reverts to normality after a thyroidectomy in up to 89% of cases. In these cases, the pathogenesis of the vocal cord mobility disturbance is attributed to the direct compression of the RLN by massive thyroid enlargement. The authors describe three cases of patients presenting unilateral vocal cord palsy, which, before surgery, was diagnosed by laryngoscopy concomitantly with large and compressive goiter. Vocal fold mobility became normal after the thyroidectomy in all three cases. Therefore, it is noteworthy that these alterations may present reversibility after appropriate surgical treatment. An early surgical approach is recommended to reduce the nerve injury as much as possible; to preserve the integrity of both RLNs since the nerve function will be restored in some patients.

### Keywords

Goiter; Vocal Cord Paralysis; Thyroidectomy

### INTRODUCTION

The diagnosis of vocal cord palsy associated with nodular goiter always raises the suspicion of thyroid malignancy. However, although less frequent, mobility disturbance of the vocal cords also may occur due to the compressive effect of gland enlargement. The main vocal fold mobility derangements are represented by paresis when the mobility is decreased, or by palsy when there is no moving sketch of the vocal fold during phonation. Both alterations may be examined by laryngoscopy; they occur by the injury of the recurrent laryngeal or vagus nerves.<sup>1,2</sup>

The most frequent causes of vocal cord palsy are idiopathic (13-27%) and malignancies (12-38%); a less

common cause is benign nodular goiter (5-10%).<sup>3</sup> Rowe-Jones et al.<sup>4</sup> found 22 cases with preoperative vocal cord mobility disturbance among 2321 cases of goiter that were submitted to a thyroidectomy. In the same study, the authors detected the postoperative recovery of recurrent laryngeal nerve (RLN) function and vocal fold mobility in 19 patients (89% of recovery rate).

The aim of this study is to present a series of three cases of vocal cord mobility derangement caused by goiter, which were each reversed after a thyroidectomy.

<sup>a</sup> Head and Neck Surgery Discipline - Hospital das Clínicas - Faculty of Medicine - Universidade de São Paulo, São Paulo/SP - Brazil.

<sup>b</sup> Instituto do Câncer do Estado de São Paulo (ICESP), São Paulo/SP - Brazil.



## CASE REPORTS

### Case 1

A 77-year-old female patient complained of insidious dysphagia and dyspnea, which had worsened over the last 20 years. She denied dysphonia. She had undergone a right thyroid lobectomy with isthmusectomy 30 years previously and was being followed up at the same medical facility. The physical examination revealed an euphonic and eupneic patient presenting a neck scar and a huge, nodular left thyroid lobe enlargement with imprecise inferior limit, which resembled a plunging goiter. A laryngoscopy, performed 2 years before, showed normal mobility of the vocal folds. A fine needle aspiration biopsy revealed a cytological finding consistent with the diagnosis of adenomatous goiter. A current laryngoscopy showed the palsy of the left vocal fold (Figure 1).

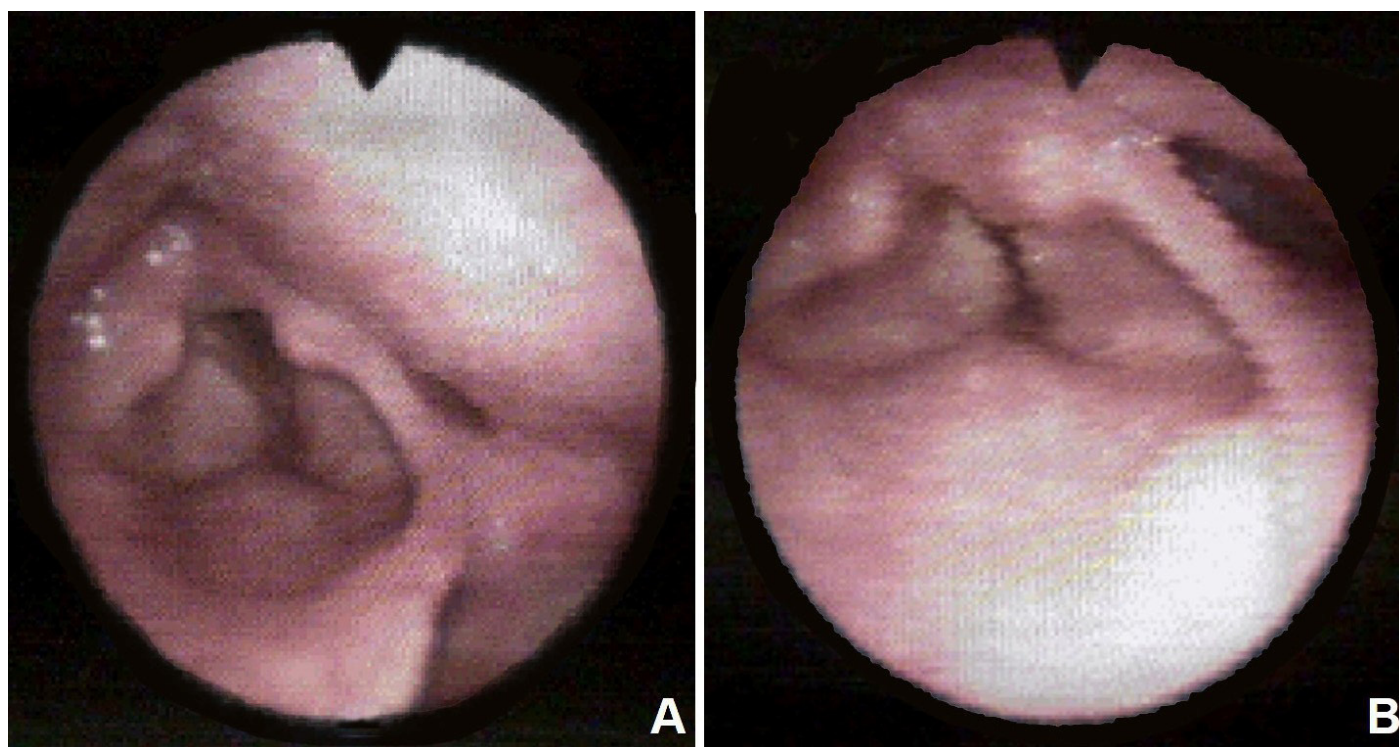
The computed tomography of the neck showed a voluminous plunging mass within the left thyroid lobe (estimated volume 286 cc) displacing the great vessels and the trachea to the right, which exhibited a luminal narrowing of up to 70%. A compression of the neurovascular bundle (involving the left vagus nerve, left internal jugular vein, and the left carotid artery)

caused by the mass against the first left rib was also identified (Figure 2).

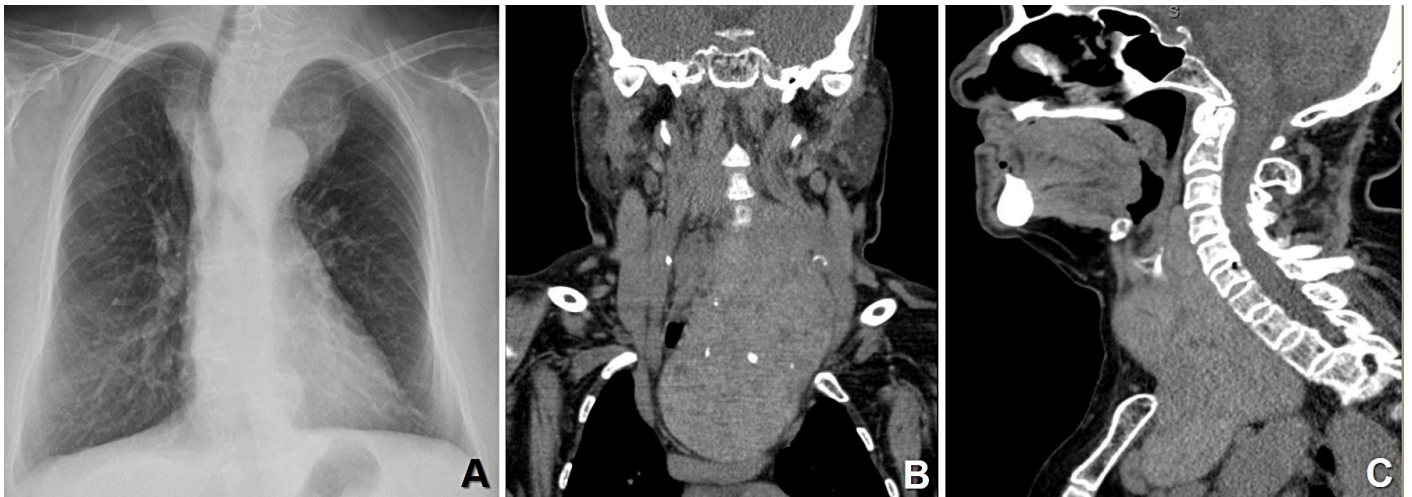
The patient underwent a left lobe thyroidectomy through a transverse lower midcervical incision preserving the left RLN. Intraoperative RLN monitoring was undertaken, with the presence of the nervous sign throughout the surgical procedure (signal conductivity of 115  $\mu$ V at the moment of nerve identification and 195  $\mu$ V at the end of surgery). Colloid goiter was the anatomopathological report of the surgical specimen. On the first postoperative day, the vocal cords presented normal mobility (Figure 3) at laryngoscopy, and the patient was discharged for routine follow-up with continuous hormone replacement.

### Case 2

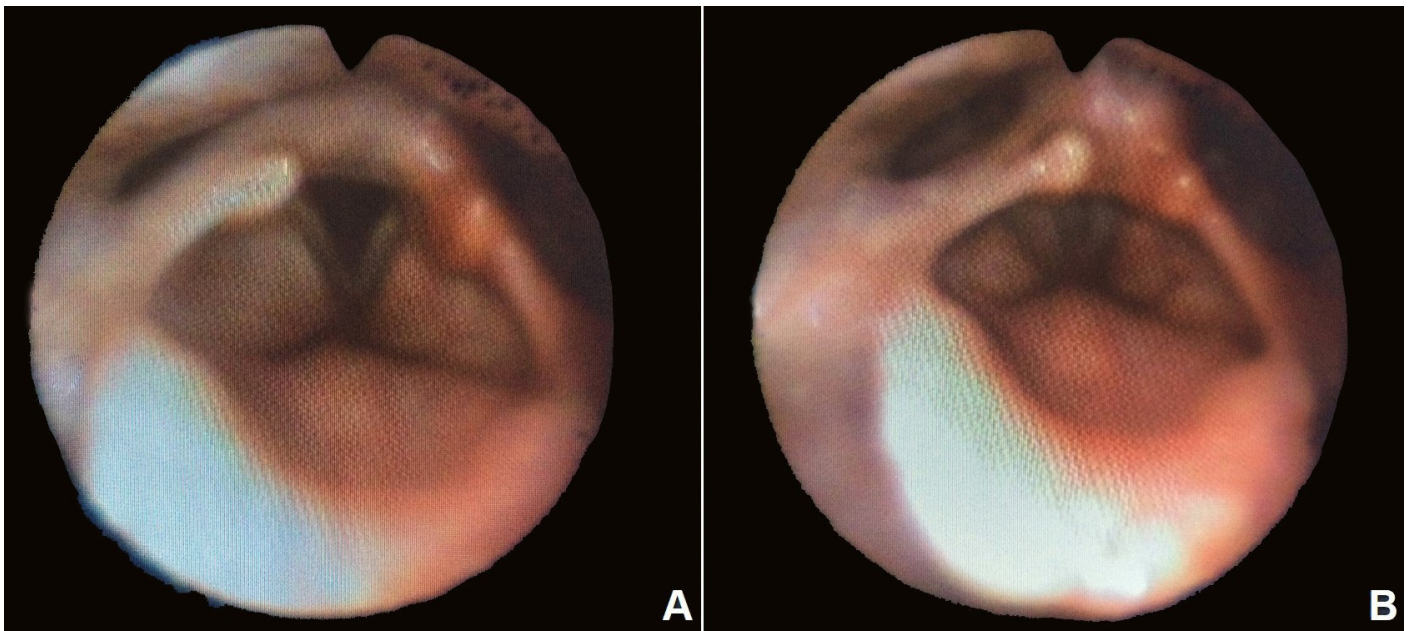
A 46-year-old woman diagnosed with substernal multinodular toxic goiter (estimated volume of 175 cc) presented an immobile left vocal fold in the paramedian position on preoperative laryngoscopy. Total thyroidectomy was undertaken with intraoperative RLN monitoring. Both RLN and vagus nerves exhibited normal function during the whole surgical procedure. The patient presented normal voice and vocal cords' mobility at the laryngoscopy 1 week after surgery.



**Figure 1.** Preoperative laryngoscopy showing the left vocal fold palsy at inspiration (A) and at phonation (B).



**Figure 2.** Chest radiography (A) and neck computed tomography (B - coronal plane and C - sagittal plane) showing a massive plunging mass into the superior mediastinum in the left thyroid lobe topography, displacing and narrowing the trachea. Note the displacement of the left neurovascular bundle and its compression against the first rib.



**Figure 3.** Postoperative laryngoscopy showing the left vocal fold mobility recovery at inspiration (A) and at phonation (B).

### Case 3

An 80-year-old woman with the diagnosis of plunging multinodular goiter (ultrasonographic estimated volume of 230 cc) complained of long-standing dysphonia. The preoperative laryngoscopy revealed a paralyzed left vocal fold in the paramedian position. She was submitted to a total thyroidectomy, and 1 week later she presented a normal voice without dysphonia. At the control laryngoscopy, the mobility of the vocal cords was normal.

### DISCUSSION

The cases described herein demonstrate that vocal cords palsy may happen in association with the thyroid benign entities and that its reversibility is possible after a thyroidectomy. The findings are corroborated by literature reports.

O'Duffy and Timon<sup>3</sup> found 9 patients (1.7%) with a paralyzed vocal fold among 830 patients submitted to thyroidectomy. In 6 of these patients, a benign



thyroid entity was identified; in 3 patients, the vocal cord palsy was associated with malignancy.

In a study comprising 90 patients with unilateral vocal cord palsy, Srirompotong et al.<sup>5</sup> found that malignancy was the etiology in 29%. In this study, neck neoplasia was responsible for 10% of the cases, followed by pulmonary malignancy in 7%. Rowe-Jones et al.<sup>4</sup> studied 2408 patients who had undergone a thyroidectomy between 1947 and 1992. Preoperative palsy of one vocal fold was identified in 22 out of 2321 patients (0.95%) with benign thyroid disease, and in 7 of 87 patients (8%) with malignant thyroid disease. The recovery of nerve function and mobility of the vocal cords occurred in 17 patients with benign thyroid disease (89%). In 6 of these patients (35.3%), the nerve function, demonstrated by laryngoscopy, was re-established on the third postoperative day (similar to our series observation), while late recovery occurred after 12 and 18 months postoperatively.

There are various possible explanations for vocal fold mobility alteration as well as some types and causes of the RLN injury associated with benign thyroid diseases.<sup>3,4,6-8</sup>

According to the Seddon<sup>9</sup> classification, which was further modified by Sunderland,<sup>10</sup> there are different grades and stages of nervous injury. The neuropraxia is the most common and mild neuronal lesion or injury, in which a transient conduction blockage occurs due to a local demyelination (by Schwann cells injury) with preservation of the axonal integrity. Usually, in this case, the nerve function is restored when the Schwann cells are repaired. The axonotmesis represents the second degree of a nerve lesion, which is associated—to a lesser extent—with nerve function recovery.<sup>6,7</sup> The neuropraxia was the lesion that most likely occurred in the cases presented herein, because of the fast functional recovery of the involved vocal fold.

Rowe-Jones et al.<sup>4</sup> proposed some mechanisms to explain the vocal fold palsy associated with thyroid enlargement: (i) a direct compression of the nerve or its blood supply against the spine or trachea stretching the nerve and eliciting an inflammatory response, and thrombosis of small arteries with subsequent neuronal surrounding fibrosis; (ii) the involvement of the nerve directly by thyroiditis; and (iii) the expansion of the thyroid could restrain the nerve in the pretracheal space bringing about a compartmental syndrome.

In this setting, the thyroidectomy provides the re-establishment of the nerve blood supply, which explains the prompt recovery of the nerve function and, consequently, the vocal fold soon after the surgical procedure, as exemplified by the Case 1 of this series.

Similarly, O'Duffy and Timon<sup>3</sup> stated that the most accepted mechanisms are the compression or stretching of the nerve, and/or the detriment of the nerve blood supply by the nerve compressing against a hard structure, such as the spine or trachea, as observed in the presented cases of our series. The reversibility of the nervous lesion would depend on the duration of ischemia.

Holl-Allen<sup>8</sup> observed that retrosternal goiters also could be responsible for similar palsy mainly by the involvement of the left RLN, which exhibits a longer route. This explanation is consistent with the three cases of retrosternal or plunging goiters of our reported series.

Rueger<sup>11</sup> described different rates of nerve function recovery after a thyroidectomy due to benign thyroid entities, which ranged between 0% and 38% depending on the duration of the paralysis highlighting the necessity of the preoperative laryngoscopy to adequately evaluate the mobility of the vocal cords before the procedure. Equally important is the postoperative laryngoscopy, since voice normalization does not prove the recovery of the paralysis, since the contralateral vocal fold can amend the glottal gap. Pre- and postoperative laryngoscopies were undertaken in all three cases reported herein, which evidenced vocal fold recovery after the thyroidectomy.

Given the possibility of partial or transitory lesion of the RLN, which may reverse after a thyroidectomy, the observation, dissection, and preservation of nerve integrity throughout the whole surgery is recommended.<sup>12</sup> Furthermore, the nerve can regenerate if an incomplete nerve lesion occurs.<sup>13</sup> This precaution was undertaken in all the cases of this study.

Therefore, nodular thyroid disease associated with vocal fold palsy does not always indicate malignancy; although rare, it also may occur among benign entities. The pre- and postoperative laryngoscopy and the surgical treatment should be undertaken as early as possible to preserve the RLN, since many patients recover its function after a thyroidectomy.

The study was approved by the Research and Ethics Committee under the number 712/11.

## REFERENCES

1. Abboud B, Tabchy B, Jambart S, Hamad WA, Farah P. Benign disease of the thyroid gland and vocal fold paralysis. *J Laryngol Otol.* 1999;113(5):473-4. <http://dx.doi.org/10.1017/S0022215100144251>. PMID:10505166.
2. McCall AR, Ott R, Jarosz H, Lawrence AM, Paloyan E. Improvement of vocal cord paresis after thyroidectomy. *Am Surg.* 1987;53(7):377-9. PMID:3605854.
3. O'Duffy F, Timon C. Vocal fold paralysis in the presence of thyroid disease: management strategies. *J Laryngol Otol.* 2013;127(8):768-72. <http://dx.doi.org/10.1017/S0022215113001552>. PMID:23899778.
4. Rowe-Jones JM, Rosswick RP, Leighton SEJ. Benign thyroid disease and vocal cord palsy. *Ann R Coll Surg Engl.* 1993;75(4):241-4. PMID:8379624.
5. Srirompotong S, Sae-Seow P, Srirompotong S. The cause and evaluation of unilateral vocal cord paralysis. *J Med Assoc Thai.* 2001;84(6):855-8. PMID:11556465.
6. Mattsson P, Hydman J, Svensson M. Recovery of laryngeal function after intraoperative injury to the recurrent laryngeal nerve. *Gland Surg.* 2015;4(1):27-35. PMID:25713777.
7. Chhabra A, Ahlawat S, Belzberg A, Andreseik G. Peripheral nerve injury grading simplified on MR neurography: as referenced to Seddon and Sunderland classifications. *Indian J Radiol Imaging.* 2014;24(3):217-24. <http://dx.doi.org/10.4103/0971-3026.137025>. PMID:25114384.
8. Holl-Allen RT. Laryngeal nerve paralysis and benign thyroid disease. *Arch Otolaryngol.* 1967;85(3):335-7. <http://dx.doi.org/10.1001/archotol.1967.00760040337018>. PMID:6019250.
9. Seddon HJ. A classification of nerve injuries. *BMJ.* 1942;2(4260):237-9. <http://dx.doi.org/10.1136/bmj.2.4260.237>. PMID:20784403.
10. Sunderland S. A classification of peripheral nerve injuries producing loss of function. *Brain.* 1951;74(4):491-516. <http://dx.doi.org/10.1093/brain/74.4.491>. PMID:14895767.
11. Rueger RG. Benign disease of the thyroid gland and vocal cord paralysis. *Laryngoscope.* 1974;84(6):897-907. <http://dx.doi.org/10.1288/00005537-197406000-00002>. PMID:4832372.
12. Chang M, Khoo JB, Tan HK. Reversible recurrent laryngeal nerve palsy in acute thyroiditis. *Singapore Med J.* 2012;53(5):e101-3. PMID:22584984.
13. Jatzko GR, Lisborg PH, Muller MG, Wette VM. Recurrent nerve palsy after thyroid operations: principal nerve identification and a literature review. *Surgery.* 1994;115(2):139-44. PMID:8310401.

**Conflict of interest:** None

**Submitted on:** March 23<sup>rd</sup>, 2016

**Accepted on:** June 16<sup>th</sup>, 2016

### Correspondence

Leandro Luongo Matos

Universidade de São Paulo (USP)

Av. Dr. Enéas de Carvalho Aguiar, 255, 8th floor, room 8174 – São Paulo/SP – Brazil

CEP: 05403-000

Phone: +55 (11) 3069-6425

[l.matos@fm.usp.br](mailto:l.matos@fm.usp.br)