

## Inner tubing technique used for the treatment of anastomotic aneurism

Márcio Teodoro da Costa Gaspar<sup>a</sup>, Bruno Vinicius Hortences de Mattos<sup>b</sup>,  
Milena Cristina Dias Sofia<sup>c</sup>, Grace Carvajal Mulatti<sup>c</sup>, Alex Lederman<sup>c</sup>

Gaspar MTC, Mattos BVH, Sofia MCD, Mulatti GC, Lederman A. Inner tubing technique used for the treatment of anastomotic aneurism. *Autopsy Case Rep* [Internet]. 2016;6(2):55-58. <http://dx.doi.org/10.4322/acr.2016.032>

### Abstract

The authors report the case of a 66-year-old male patient diagnosed with a pseudoaneurysm of the distal aorto-aortic anastomosis treated with the inner tubing technique. The patient had been operated on 1 year before when he had an aortic prosthesis implanted as treatment for a ruptured abdominal aortic aneurysm. The inner tubing technique was developed to facilitate the treatment in bifurcated vascular lesions, where endovascular conventional prosthesis is not available.

### Keywords

Aortic Aneurysm, Abdominal; Endovascular Procedures

### CASE REPORT

A 66-year-old male patient—an ex-smoker—who was previously diagnosed with hypertension, dyslipidemia, non-dialytic chronic renal failure, and benign prostate hyperplasia was admitted to the emergency facility with the diagnosis of a juxtarenal abdominal aortic aneurysm rupture. He was submitted to a thoraco-phreno-laparotomy followed by aneurysmectomy and aorto-aortic Dacron prosthesis insertion. Within the first 24 hours of the postoperative period, mesenteric ischemia and abdominal compartment syndrome ensued, which required an extensive enterectomy involving the small bowel until 1.7 m of the Treitz angle, accompanied by proximal enterostomy, distal stump burial, and Bogotá bag peritoneostomy. The abdominal cavity was closed

after two revisions. On the twentieth postoperative day, after the last surgical procedure, right lower limb ischemia, caused by decompensated chronic arterial occlusion, required transtibial amputation. The patient was discharged after 55 days of hospitalization. Nearly 1 year after these procedures, he was hospitalized for reconstruction of the intestinal transit and incisional hernioplasty with preperitoneal Marlex<sup>®</sup> mesh.

A pseudoaneurysm of the distal aorto-aortic anastomosis was diagnosed by a Doppler ultrasound performed during the 1-year follow-up, which was confirmed by a non-contrasted abdominal computed tomography (CT). The latter detected an infrarenal fusiform aneurysm emerging 8 cm below the renal arteries and extending until the emergence of the iliac

<sup>a</sup> Surgery Department - Clinica Multiperfil – Luanda – Angola.

<sup>b</sup> Surgery Department - Faculty of Medicine - Universidade de São Paulo - São Paulo/SP – Brazil.

<sup>c</sup> Surgery Division - Hospital Universitário - Universidade de São Paulo - São Paulo/SP – Brazil.



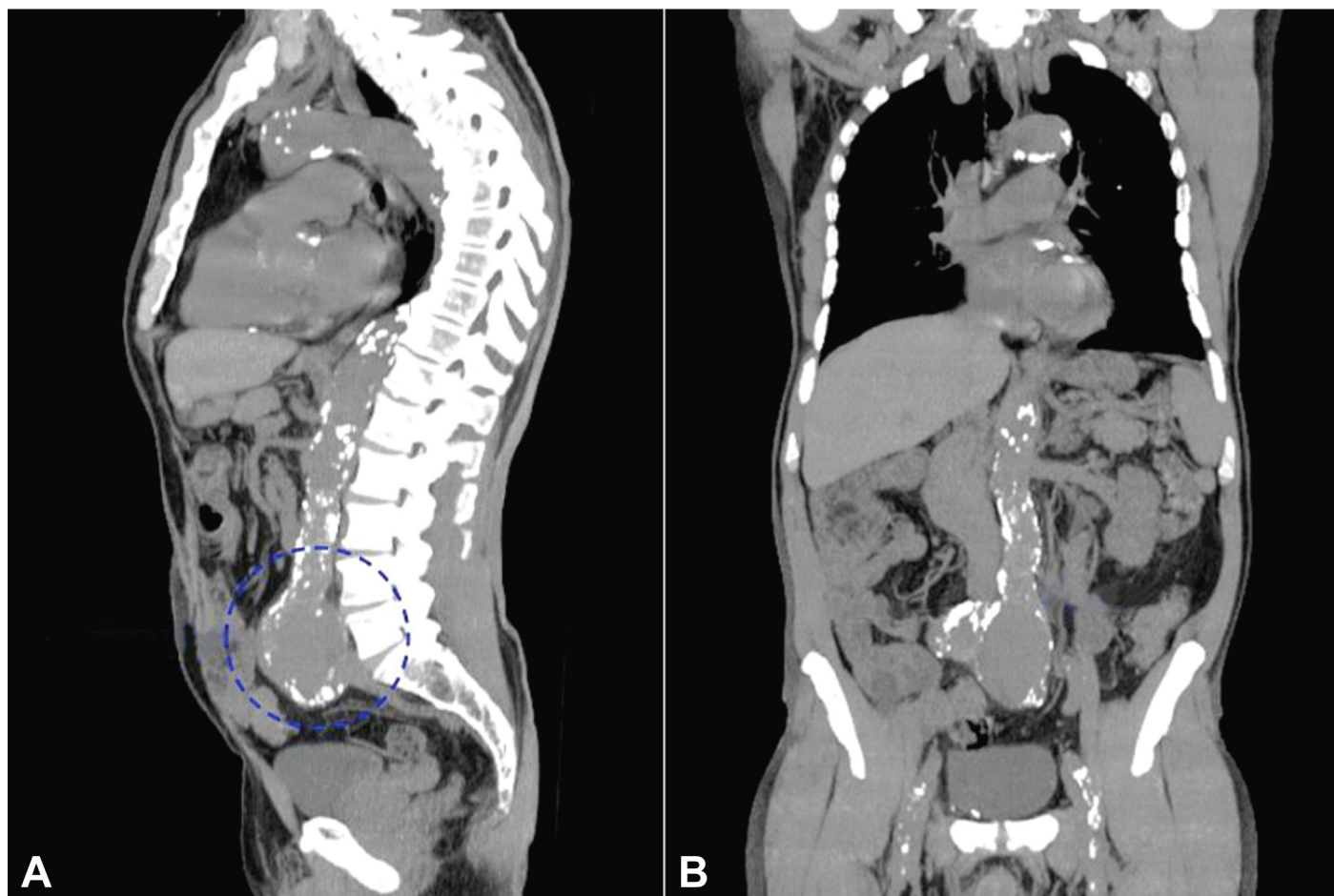
arteries (7.3 cm in length and 6.1 cm in diameter). An eccentric thrombus and parietal calcifications were present, and a saccular component (3.7 cm in length and 3.7 cm in diameter) extended until the right common iliac artery, as shown in (Figure 1).

In light of the imaging findings and clinical data, some therapeutic options were considered, namely: (i) inner tubing or sandwich; (ii) multilayer flow modulator; (iii) aortomonoiliac endografting plus femorofemoral crossover bypass graft; and (iv) open surgery. However, taking into account the multiple previous surgical interventions, the vascular surgeons chose the inner tubing technique, which was performed as follows: (i) a bilateral inguinotomy with isolation of the common, the internal, and the external femoral arteries; (ii) systemic heparinization; (iii) an arteriography identifying the distal prosthesis, and the common internal and external iliac arteries; (iii) the insertion of bilateral rigid guidewire; (iv) a Viabahn® endoprosthesis kissing placement (13 × 100 left;

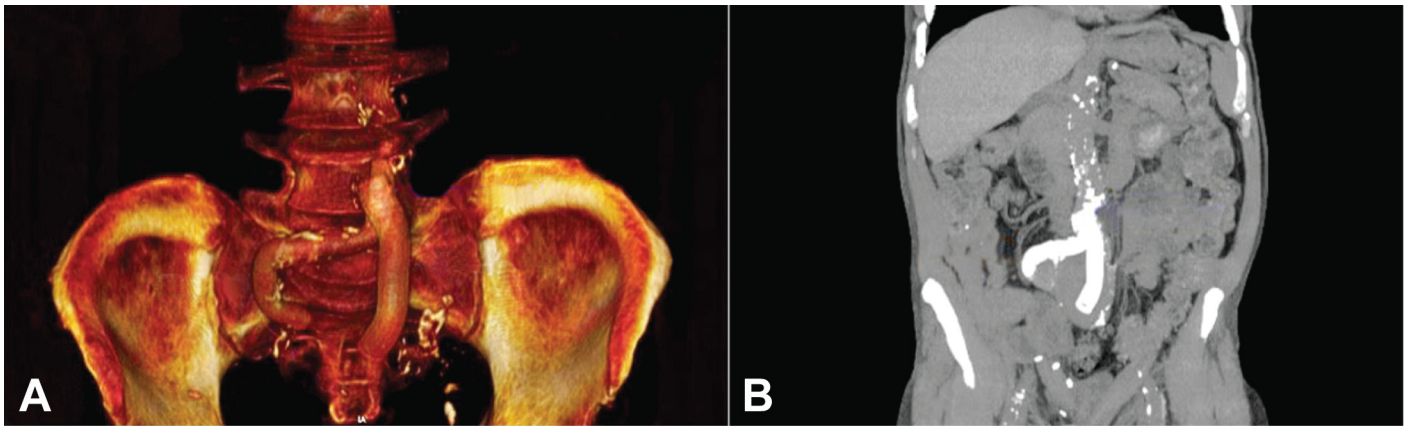
10 × 150 right); (v) a control arteriography (a small endoleak on the left side was detected but blood flow was satisfactorily obtained on both sides); (vi) arterial suture with 5-0 prolene; and (vii) suture of the inguinotomies. The procedure was uneventful, without the need for hemoderivatives transfusion. The patient was fed orally on the first postoperative day and was discharged on the second day. Perfusion was promptly fully re-established, which was assured on the ambulatory follow-up by clinical examination. A control CT was done 1 month after the procedure (Figure 2).

## DISCUSSION

Endovascular treatment of aneurysms represents, beyond question, a great deal of movement in vascular surgery. In the treatment of patients with increasingly severe conditions, the improvement of prostheses and refinement of the endovascular



**Figure 1.** Computed tomography of the abdomen. **A** - Coronal plane; and **B** - sagittal plane, showing an aortic aneurysm at the site of the distal aorto-aortic anastomosis.



**Figure 2.** Computed tomography of the abdomen performed three months after the procedure. **A** - 3D reformation; and **B** - coronal plane; patency of the endoprosthesis in the iliac arteries position.

techniques are accompanied by encouraging results<sup>1</sup>. Several techniques are available for the treatment of aneurysms<sup>2,3,4</sup>, but in the case reported herein the inner tubing technique was chosen, which was developed for bifurcation lesions where conventional vascular endoprosthesis are unavailable or the anatomy does not fit the available endoprosthesis<sup>5</sup>. The aortomonoiliac endovascular grafting technique would be, indeed, an adequate procedure for this case, but it would involve a higher surgical risk and the requirement of an aortic endoprosthesis that was unavailable in our service. Thus, a straight stent was set in place to create a “proximal neck,” followed by the insertion (within the first stent) of two other parallel stents using the “kissing” maneuver plotting up a branch in each artery bifurcation<sup>5</sup>. In our patient, since the previous inserted prosthesis was in the aortic position, it was only necessary to complete the technique by deploying the iliac extensions bilaterally. The first prosthesis served as the basis for fixing the new iliac branches.

This technique, besides the preservation of vascular bifurcations,<sup>5</sup> presents the following advantages: (i) the use of easily available, off-the-shelf, covered stents without the need for individualized customization; (ii) a full approach by inguinoscopy without the need for a laparotomy in a previously operated abdomen; (iii) the preservation of two iliac arteries without the necessity of the performance of an aortic-monoiliac graft associated with a femorofemoral crossover bypass; (iv) the preservation of the hypogastric arteries; (v) reduced hospitalization time; and (vi) reduced time of anesthesia. On the other hand, the main early- and

mid-term complication of any endovascular procedure/treatment is represented by the proximal and distal endoleaks. In our case, the proximal endoleak was prevented by using an endoprosthesis gauge adapted to fill the whole lumen of the first prosthesis (confirmed by the control image). The distal leak was resolved by the aneurysm remodeling since the endoprostheses were well located into the iliac arteries. The occlusion of an endoprosthesis is another possible complication of this chosen technique. However, the control CT showed an adequate blood flow and the absence of kinking in the endoprostheses.

The inner tubing technique seems to be a viable therapeutic option accompanied by a promising outcome, besides being a minimally invasive method for the correction of complex lesions in high-risk patients with a hostile abdomen.<sup>5</sup> Larger studies and longer follow-up are still needed to assure promising results in other cases.

## REFERENCES

1. Sakalihan N, Limet R, Defawe OD. Abdominal aortic aneurysm. *Lancet*. 2005;365(9470):1577-89. [http://dx.doi.org/10.1016/S0140-6736\(05\)66459-8](http://dx.doi.org/10.1016/S0140-6736(05)66459-8). PMID:15866312.
2. Kafejian O, Ricci JA, Nem JT Jr, Roberti T, Bolanho E. Aneurisma de aorta abdominal: diagnóstico, tratamento cirúrgico e resultados. *Cir Vasc Ang*. 1988;4:8-15.
3. Novero ER, Metzger PB, Angelieri FMR, et al. Correção endovascular do aneurisma da aorta abdominal: análise dos resultados de único centro. *Radiol Bras*. 2012;45(1):1-6. <http://dx.doi.org/10.1590/S0100-39842012000100003>.

4. Araujo AG, Souza FHR, Fernandes FH, Barbosa FP, Jatene JA, Câmara PCG. Tratamento endovascular de aneurisma de aorta abdominal pela técnica de Chaminé. Rev Bras Cardiol Invasiva. 2014;22(4):386-9. <http://dx.doi.org/10.1590/0104-1843000000065>.
5. Lederman A, Saliture FT No, Miotto B No, Bub GL, Lobato MA, Aun R. Inner tubing endograft: a new technique for bifurcation preservation. J Vasc Bras. 2009;8(3):255-8. <http://dx.doi.org/10.1590/S1677-54492009005000013>.

**Conflict of interest:** None

**Submitted on:** January 5<sup>th</sup>, 2016

**Accepted on:** March 31<sup>st</sup>, 2016

**Correspondence**

Márcio Teodoro da Costa Gaspar  
Hospital Universitário - Universidade de São Paulo (USP)  
Av. Prof. Lineu Prestes, 2565, Butantã, São Paulo/SP – Brazil  
CEP: 05508-000  
Phone: +55 (11) 94836-3866  
**E-mail:** [marcio85gaspar@gmail.com](mailto:marcio85gaspar@gmail.com)