

## Retroperitoneal endoscopic lumbar sympathectomy

Wander Eduardo Sardinha<sup>1</sup>; Jose Manoel da Silva Silvestre<sup>1</sup>; Fernando Thomazinho<sup>1,1</sup>; Rodrigo Gomes de Oliveira<sup>1,1</sup>; Domingos de Moraes Filho<sup>1</sup>

<sup>1</sup>Physician. Professor, Universidade Estadual de Londrina, Londrina, PR, Brazil.

<sup>1,1</sup>Resident, Vascular Surgery Service, Department of Surgical Clinic, Hospital Universitário Estadual do Norte do Paraná (HURNP), Universidade Estadual de Londrina, Londrina, PR, Brazil.

### Correspondence

J Vasc Bras. 2007;6(4):339-43.

---

### RESUMO

**Contexto:** A simpatectomia ainda encontra indicação no tratamento de várias doenças, tais como a insuficiência arterial periférica crônica aterosclerótica grau IV (Fontaine) sem condições de revascularização, úlceras hipertensivas e o fenômeno de Raynaud acompanhado de lesões tróficas. A cirurgia clássica é realizada através do acesso retroperitoneal, mas também pode ser realizada por meio de técnicas minimamente invasivas.

**Objetivo:** Este trabalho tem o objetivo de mostrar os resultados da simpatectomia lombar por pneumoretroperitonioscopia.

**Métodos:** Trinta e um pacientes foram submetidos a simpatectomia lombar por pneumoretroperitonioscopia (22 homens e nove mulheres), com média de idade de 48 anos (41-70). Vinte eram pacientes com insuficiência arterial periférica crônica, sem possibilidade de revascularização, todos com lesões (necroses ou úlceras); sete pacientes eram portadores de tromboangiite obliterante; três tinham úlcera hipertensiva; e um apresentava fenômeno de Raynaud secundário. As cirurgias foram realizadas por pneumoretroperitoneoscopia, sendo feita a exérese do segundo ao quarto gânglio da cadeia lombar.

**Resultados:** Não houve complicações intra-operatórias, havendo necessidade de apenas uma conversão para cirurgia convencional por dificuldade técnica. A duração média do procedimento foi de 103 minutos e o tempo médio de internação foi de 2 dias.

**Conclusão:** A simpatectomia pode ser realizada por pneumoretroperitonioscopia com as vantagens de uma cirurgia minimamente invasiva.

**Palavras-chave:** Simpatectomia lombar, pneumoretroperitoneoscopia.

---

## ABSTRACT

**Background:** Sympathectomy can still be performed in the treatment of many diseases, such as chronic atherosclerotic peripheral arterial disease stage IV without conditions of revascularization, hypertensive ulcer and necrosis associated with Raynaud phenomenon. The classical treatment is performed through retroperitoneal access, but can also be performed through minimally invasive techniques.

**Objective:** This study aims at evaluating results of retroperitoneal endoscopic lumbar sympathectomy.

**Methods:** Thirty-one patients were submitted to retroperitoneal endoscopic lumbar sympathectomy (22 males and nine females), mean age of 48 years (41-70). Twenty patients had chronic peripheral arterial disease, with no possibility of revascularization, all presenting with necrosis or ulcer; seven patients had thromboangiitis obliterans, three had hypertensive ulcer, and one patient had secondary Raynaud phenomenon. Surgical procedures were performed by retroperitoneal endoscopic access, besides excision of ganglia L2-L4 of the lumbar sympathetic chain.

**Results:** There were no intraoperative complications, only the need of converting to open surgery due to technical difficulties. Mean operative time was 103 minutes and mean hospital stay was 2 days.

**Conclusion:** Sympathectomy can be performed by retroperitoneal endoscopy using the advantages of a minimally invasive surgery.

**Keywords:** Lumbar sympathectomy, retroperitoneal endoscopy.

---

## Introduction

Since its first use in 1920, by Adson & Brown<sup>1</sup> in the USA and Diez<sup>2</sup> in South America, sympathectomy is still used for the treatment of some diseases.

Sympathectomy changes vasomotor tone, causing improvement in skin microcirculation. The physiopathological bases of sympathectomy are: 1) immediate paralytic vasodilatation; 2) hemometakinesis phenomenon; 3) development of collateral circulation.<sup>3</sup> The procedure can be indicated in cases of atherosclerotic chronic peripheral arterial insufficiency with impossibility of revascularization, in thromboangiitis obliterans and in vasospastic ischemic manifestations associated with functional arteriopathies.<sup>4</sup> It can also be indicated for hyperhidrosis and reflex sympathetic dystrophy.<sup>5</sup>

The conventional technique of lumbar sympathectomy by retroperitoneal access may present some inconveniences inherent to any surgical procedure, such as extensive dissection, painful incision and complications such as surgical wound infection, hematoma, bleeding, postoperative paralytic ileus if there is inadvertent perforation of the peritoneum and incisional hernia. However, its advantage is providing wide access to the retroperitoneal cavity, allowing more facility of sympathetic chain excision and control of bleeding more efficiently and appropriately. Retroperitoneal endoscopic lumbar sympathectomy (RELS) has the advantage of being a minimally invasive procedure, with less painful and faster postoperative recovery, discharge and earlier return to usual activities. It has some disadvantages, such as longer perioperative time, especially in initial cases, and reduced operative work field, which makes complete removal of ganglia L2-L4 difficult.

## Method

From October 2003 to February 2007, 31 patients were submitted to RELS. Of these, 22 were male and nine were female (Table 1), mean age of 48 years (41-70). A total of 34 sympathectomies were performed, three bilateral – two patients with thromboangiitis obliterans and one patient with chronic peripheral arterial insufficiency (CPAI). The patients submitted to bilateral RELS needed that procedure at different moments, because the lesions were manifested at different times.

**Table 1 - Population: patients submitted to retroperitoneal endoscopic lumbar sympathectomy (RELS)**

Patients	n = 31
Mean age	48 (41-70)
Man/Woman	22:9
Number of sympathectomies	n = 34
Indications	
POAD (20)	
Gangrene of toes	9
Ischemic ulcers	11
TAO (7)	
Gangrene of toes	6
Ischemic ulcers	1
HU (3)	
Raynaud	1

HU = hypertensive ulcer; POAD = peripheral occlusive arterial disease (Fontaine stage IV); RELS = retroperitoneal endoscopic lumbar sympathectomy; TAO = thromboangiitis obliterans (Fontaine stage IV).

There were no diabetic patients. All 20 patients with atherosclerotic CPAI had trophic lesions (necrotic ulcers or gangrene). Of these, 11 had ulcers and nine had toe gangrene. All seven patients with thromboangiitis obliterans, diagnosed by Shionoya criteria,<sup>5</sup> had ischemic ulcers or gangrene, and three of them had been previously submitted to contralateral lumbar sympathectomy by conventional open access, and two had been previously submitted to cervical-thoracic sympathectomy due to finger gangrene. As to the three patients who had hypertensive ulcer, none of them had a satisfactory response with clinical treatment. One female patient had toe gangrene in the lower limb due to Raynaud phenomenon associated with mixed disease of the connective tissue. In our sample, three patients had body mass index (BMI) > 31. Presence of obesity brought technical difficulties in the access, in creation of retroperitoneal cavity and in identification of sympathetic chain due to higher presence of fat in that space.

### *Surgical procedure*

The surgical procedure was performed under general anesthesia. The patient is placed in right lateral decubitus position and flexion table placed at the supra-umbilical level to increase the space between the coastal ridge and iliac crest (Figure 1). Three to four incisions, named portal, are performed. Only the first incision has 2-3 cm; the others are approximately 1-1.5 cm, enough to

introduce the trocar. The site of those incisions is represented in Figure 2. The first 2-3 cm incision is located in the anterior axillary line, half way through the coastal ridge and the iliac crest, by which a 10-mm camera was introduced. Through this first entry, a blunt dissection was initially performed, progressing through the aponeurotic muscle until reaching the peritoneum. At that moment, a finger dissection was performed, reflecting the peritoneum medially until reaching the retroperitoneal fat; next, the 10-mm trocar is inserted to create space, reflecting the peritoneum medially. Then, both incision extremities were sutured at the fascia to avoid leakage of carbon gas, which will be insufflated with 12-14 mmHg pressure.

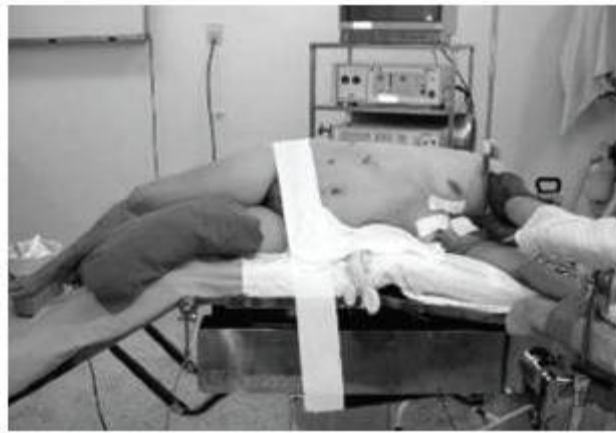

Figure 1 - Patient positioning at surgical table

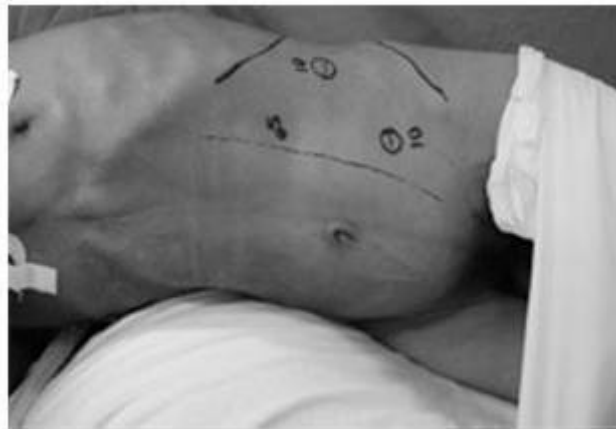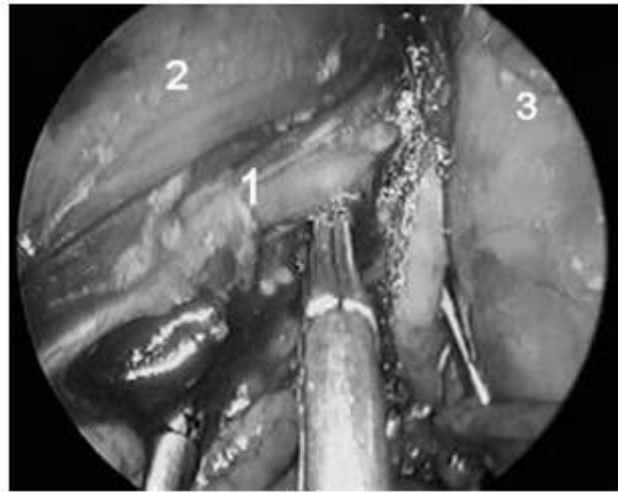


Figure 2 - Marking of portals for retroperitoneal cavity access (an alternative, as described in the text, is to introduce a fourth portal for the retractor)

Creation of a space in the retroperitoneal cavity, by inflating the gas, and with the aid of a camera that provides direct and safer visualization, allows introduction of the second and third portals. The second 10-mm portal is placed around 2-4 cm laterally to the rectus abdominis sheath, distally to the camera portal. The third portal, measuring 5 mm, is placed in the same reference as the second, but in proximal position. These two latter portals are used as work instruments (dissection and grasping). A fourth portal is often needed to place a third work instrument (liver retractor), which will retract the psoas muscle superiorly, since it frequently covers the sympathetic chain, making visualization difficult.

After visualization of the psoas muscle, individualization of the sympathetic chain is performed

medially to it and using a curve dissection and grasping forceps, being careful not to damage adjacent structures, such as ureter, lumbar arteries and veins (Figure 3). The sympathetic chain runs through the dihedral angle formed by the psoas muscle and vertebral bodies. Proper dissection should be performed to expose the distal segment of the lumbar sympathetic trunk to identify the L4 ganglion. From that point, 3-4 cm of the chain is resected proximally. At the end of the procedure, homeostasis and fascia synthesis are reviewed.



**Figure 3 - Dissection of the lumbar sympathetic chain (1), psoas muscle superiorly (2) and peritoneal sac retracted to the right (3)**

## Results

Thirty-one patients were submitted to RELS, with a total of 34 procedures performed by retroperitoneal endoscopy (12 procedures to the right, 19 to the left and three bilateral procedures). All procedures were successfully performed; however, due to technical difficulties, it was necessary to convert to conventional open surgery in one patient. That patient was obese, with a large amount of retroperitoneal fat, requiring extensive dissection and being difficult to properly identify the structures, which made the procedure technically difficult. After conversion to conventional open surgery, the retroperitoneal fat, which had been dissected, was removed and there was no difficulty in identifying the sympathetic chain.

There was perforation of the peritoneum in four cases. The retroperitoneal cavity created by the carbon gas is small and the peritoneal opening makes the insufflated gas in the retroperitoneal cavity also pass to the peritoneal cavity. This results in a reduction in the space created by the pneumoretroperitoneum, making the procedure longer due to the difficulty in performing it in an even smaller space. However, it is not necessary to perform conversion to conventional surgery due to peritoneal perforation.

Mean time of surgical procedure in the first 15 cases was 121 minutes (187-85), with evident learning curve marked by significant reduction in surgical time in more recent cases for a mean of 87 minutes (97-71). Duration of retroperitoneum was 82 minutes in average (55-112). After the surgery, it was not necessary to associate other drugs in patients' analgesia due to the procedure. They were all discharged 24 hours after the surgery. The histopathological test of all specimens showed removal of the sympathetic chain. There were no hemorrhagic complications.

One month after the surgery, none of the patients complained about neuralgia and only one patient had hypoesthesia in the inguinal region. There was no sexual dysfunction in men, even in those who were submitted to bilateral RELS.

Of the patients with CPAI without conditions of revascularization, nine had gangrene restricted to toes and 11 had ischemic ulcers. Of the nine patients with toe gangrene, seven had healing after debridement. Of the two patients with more extensive lesions, one was submitted to transmetatarsal amputation and one to transtibial amputation due to extensive lesion infection. The 11 patients with ulcers had lesion healing during the 6-month follow-up.

Of the seven patients with thromboangiitis obliterans, six had toe gangrene and one had ischemic ulcer. They all had good response with healing and improvement in pain pattern. The patients with hypertensive ulcer had good response, with lesion healing.

The patient with Reynaud syndrome, after sympathectomy, was submitted to toe amputation of the affected limb and progressed with complete healing.

## Discussion

Indication of lumbar sympathectomy has been reduced due to success of distal revascularizations and new drugs. However, a considerable number of patients cannot be submitted to arterial reconstruction or has trophic lesions associated with vasospastic phenomena that do not respond to pharmacological therapy. The *TransAtlantic Inter-Society Consensus* (2000)<sup>6</sup> established the indications for lumbar sympathectomy: 1 – main: selected patients with distal occlusive disease that cannot be submitted to surgery and thromboangiitis obliterans. Surgery impossibility mainly depends on lack of distal drainage; 2 – sympathectomy is indicated in patients whose ankle-brachial index is higher than 0.3; that tissue necrosis is limited to toes and absence of neuropathy (diabetes). Conventional lumbar sympathectomy, with risks inherent to any open surgery, remains as standard surgery for these patients. All patients in this series had ankle-brachial index higher than 0.3.

Chemical sympathectomy,<sup>7,8</sup> through radiologically-guided percutaneous injections of phenol or alcohol, shows some success in a few series, but in others<sup>9</sup> it shows inconstant results, especially regarding duration of sympathetic blockade.

Use of laparoscopic techniques in sympathectomy shows the advantages of minimally invasive surgery and makes the procedure feasible and efficacious.

Some authors use laparoscopic sympathectomy using the transperitoneal access<sup>10</sup> with excellent outcomes; however, we prefer the pneumoretroperitoneum technique due to lower clinical repercussions of an intra-abdominal hypertension. Beglaibter et al.<sup>11</sup> described their technique for RELS with excellent outcomes. The retroperitoneal endoscopic technique was described by Gaur<sup>12</sup> in 1992, but there are other variations, such as use of balloon placed through a small incision in the retroperitoneal space.<sup>13</sup>

We had problems with patients with abdominal adipose tissue due to the difficulty of entering the first portal that requires finger dissection. In addition to that difficulty, we have to mention that obese patients have more retroperitoneal fat, which makes dissection of the sympathetic chain difficult, since the cavity created by retroperitoneal endoscopy is small compared with the cavity created by peritoneal endoscopy.

Use of a fourth portal was necessary in 12 surgeries. That instrument, which is a liver retractor, was crucial for continuing the surgical procedure in these cases, since it allows raising the psoas muscle, or perhaps retracting the peritoneal sac. Besides some advantages and difficulties previously mentioned, such as difficulty in obese patients and long learning curve, videolaparoscopy has restricted indications in vascular surgery (opposed to digestive surgery) and small cavity for the procedure. We believe that RELS using video is a safe and technically accessible surgery for experienced surgeons in videolaparoscopy. The excellent clinical outcomes are compared to conventional open surgery, with the advantages of a minimally invasive surgery.

## References

1. Adson AW, Brown GE. Treatment of Raynaud's disease by lumbar ramisection and ganglionectomy and perivascular sympathetic neurectomy of the common iliac arteries. *JAMA* 1925;84:1908-10.
2. Diez J. Un nuevo metodo de simpatectomia periférica para el tratamiento de las afecciones tróficas y gangrenosas de los miembros. La disociación fascicular. *Bol Soc Cir Buenos Aires*. 1924;8:792-4.
3. Puech-Leão P. Cirurgia do sistema nervoso simpático: bases técnicas. In: Goffi FS, editor. Técnica cirúrgica: bases anatômicas, fisiopatológicas e técnicas da cirurgia. 4a ed. São Paulo: Atheneu; 1996. p. 200-3.
4. Kauffman P. Simpatectomias. In: Raia AA, Zerbini EJ, editores. Clínica cirúrgica Alípio Corrêa Neto. 4a ed. São Paulo: Sarvier; 1994. p. 84-101.
5. Shionoya S. [Diagnostic criteria of Buerger's disease](#). *Int J Cardiol* 1998;66(Suppl 1):S243-5.
6. Dormandy JA, Rutherford RB. [Management of peripheral arterial disease \(PAD\)](#). TASC Working Group. TransAtlantic Inter-Society Consensus (TASC). *J Vasc Surg*. 2000;31(1 Pt 2):S1-S296.
7. Cross FW, Cotton LT. [Chemical lumbar sympathectomy for ischemic rest pain](#). A randomized, prospective controlled clinical trial. *Am J Surg*. 1985;150:341-5.
8. Yoshida WB, Lemônica L, Rollo HA, et al. Bloqueio simpático lombar com fenol nas oclusões arteriais crônicas de membros inferiores. *Cir Vasc Angiol*. 1994;10:20-4.
9. Redman DR, Robinson PN, Al-Kutoubi MA. [Computerised Tomography guided lumbar sympathectomy](#). *Anaesthesia*. 1986;41:39-41.
10. Kathouda N, Wattanasirichaigoon S, Tang E, Yassini P, Ngaorungsri U. [Laparoscopic lumbar sympathectomy](#). *Surg Endosc*. 1997;11:257-60.
11. Beglaibter N, Berlatzky Y, Zamir O, Spira RM, Freund HR. [Retroperitoneoscopic lumbar sympathectomy](#). *J Vasc Surg*. 2002;35:815-7.
12. Gaur DD. [Laparoscopic operative retroperitoneoscopy: use of a new device](#). *J Urol*. 1992;148:1137-9.
13. Coptcoat LT, Cross FW. Laparoscopic retroperitoneal surgery. In: Coptcoat MJ, Joyee AD, editors. *Laparoscopy in urology*. Oxford: Blackwell; 1994.

 Correspondence:

Wander Eduardo Sardinha

Rua Borba Gato, 1079 - Jardim Ipiranga

CEP 86010-630 - Londrina, PR, Brazil

Tel.: (43) 3322.1411, (43) 9911.3015

Email: [wandersardinha@uol.com.br](mailto:wandersardinha@uol.com.br)

Study presented at the 36th Brazilian Congress of Angiology and Vascular Surgery.

Manuscript received April 16, 2007, accepted October 5, 2007.